

Unicystic Ameloblastoma in 8 Years old Child: A Case Report Review of Unicystic Ameloblastoma*

Gulten UNLU^{1**}, Vedat TAR², Hilal ALAN²

¹ Prof.Dr.DDS MsC PhD. Department of Oral and Maxillofacial Surgery, Faculty of Dentistry, Dicle University, Diyarbakir, TURKEY.

² DDS MsC Department of Oral and Maxillofacial Surgery, Faculty of Dentistry, Dicle University, Diyarbakir, TURKEY.

Abstract

Ameloblastoma is the most common aggressive benign odontogenic tumor of the jaws. The tumor is often asymptomatic, presenting as a slowly enlarging facial swelling or an incidental finding on a radiograph. The physical presence of the tumor may cause symptoms such as pain, ulceration, loosening of teeth, or malocclusion. Ameloblastoma is a locally destructive tumor with a propensity for recurrence if not entirely excised. A few cases of malignant change with distant metastasis have been reported in the literature. It is seen in all age groups but the lesion is most commonly diagnosed in the third and fourth decades. The tumor is considered a rarity in the young, but the tumor grows slowly and probably starts to develop in childhood (1). The treatment of ameloblastoma is still controversial and presents some special problems in children the growth of the jaw, the different incidence, behavior, and prognosis of the tumor in children make the surgical consideration different from adults. Some reports have encouraged aggressive resection for ameloblastoma in children.

(*International Dental and Medical Disorders December 2008; 1: 29-33*)

Keywords: Unicystic Ameloblastoma, Children.

Received date: August 2008

Accept date: December 2008

Introduction

Unicystic ameloblastoma, a variant of ameloblastoma first described by Robinson and Martinez^{1,2} in 1977, refers to those cystic lesions that show clinical and radiologic characteristics of an odontogenic cyst but in histologic examination show a typical ameloblastomatous epithelium lining part of the cyst cavity, with or without luminal and/or mural tumor proliferation.

According to the WHO 1992 definition, ameloblastoma is a benign but locally invasive polymorphic neoplasm consisting of proliferating odontogenic epithelium, which usually has a follicular or plexiform pattern, lying in a fibrous stroma. The WHO histological typing of odontogenic tumours classifies ameloblastomas as intra-osseous

central, and extra-osseous peripheral types³.

The small number of ameloblastomas arising directly from the surface epithelium or from residues of the dental lamina lying outside the bone constitute the peripheral type. Within the central type, the unicystic variant is recognised as a clinically, radiologically, and pathologically distinct entity with prognostic significance that warrants alternative management to the classical central type.

The intraosseous ameloblastoma of the jaws occurs most often in the fourth and fifth decades of life⁴. Its occurrence in children and adolescents younger than 18 years is uncommon, seen only in 14.6 % of 206 cases of ameloblastomas in one study⁵. The unicystic ameloblastoma is considered a variant of the solid or multicystic ameloblastoma, accounting for 6% to 15% of all intraosseous ameloblastomas⁶.

This lesion occurs in a younger age group, with slightly more than 50% of cases occurring in patients in the second decade of life⁷. In more than 90% of the cases, the unicystic ameloblastoma is located in the mandible, with 77% located in the molar ramus region in one study⁸.

Appropriate treatment for an ameloblastoma has been developed^{9,10}. But, there are few established criteria for treatment based on retrospective studies of a large number of cases and through analytical and non-descriptive statistics. An ameloblastoma is a benign tumour of odontogenic epithelial origin.

**Oral Presentation: VIII. International Scientific Congress of Association of Oral Surgery 24-29 May 2008 Yasmin Bodrum-TURKEY*

****Corresponding author:**

Prof.Dr.Gulten UNLU
Dicle University, Faculty of Dentistry, Department of Oral and Maxillofacial Surgery
21280 Diyarbakir, TURKEY.

E-mail: [gunlu@dicle.edu.tr](mailto:gulunlu@dicle.edu.tr)

Theoretically, it may arise from the cell rests of the enamel organ, from a developing enamel organ, from the epithelial lining of an odontogenic cyst, or from the basal cells of the oral mucosa^{11, 12}.

Regezi and Sciubba reported that ameloblastoma accounts for 11% of all odontogenic tumours in the jaw¹³.

The clinicopathological features are benign with a slow-growing pattern, but locally invasive. The clinical behaviour may be regarded as lying somewhere between benign and malignant, and the high recurrence rate is a problem for clinicians^{14, 15}. If the factors associated with recurrence are established and prediction of a recurrence is possible, this will be very important in reducing the recurrence rate and in the decision-making process of the appropriate treatment.

There are many reports on primary ameloblastoma, but they are mostly limited to the case report category. There have been few reliable large-scale studies with long-term follow up results on this tumour.

CASE

A 8 year-old boy presented with a painless hard swelling in the right side of the lower jaw of 6 months duration. Clinical examination revealed a bony hard swelling arising from the lower jaw, with the intraoral examination showing a large, hard, nontender mass on the right side of the mandible, covered by red, intact, and immobile mucosa. On palpation, the swelling was bony hard. (Figure 1-A and Figure 1-B)

No lymphadenopathy or fistulae were present. Past history and medical history were unremarkable. On examination no other abnormalities were found. He was taking no medication and had no history of known drug allergy. His physical examination revealed no abnormality other than those related to the chief complaint.

Radiography revealed a large unilocular radiolucency involving right mandibular first and second premolars tooth germs, first and second deciduous molar teeth and deciduous canin tooth. (Figure 2) . A provisional diagnosis of odontogenic tumour was made and incisional biopsy was performed.

Enucleation of the lesion was performed to completely extirpate the cystic lesion with extraction of 83, 84, 85 numbered teeth and 44, 45 teeth germs.(Figure 5) The result of histopathologic diagnosis was a unicystic ameloblastoma.

Panoramic radiographs are taken one day later after operation (Figure 2) ,3 months later (fFigure 3) and 6 months later (Figure 4). We can see the cavity is filled with bone in 3 months.

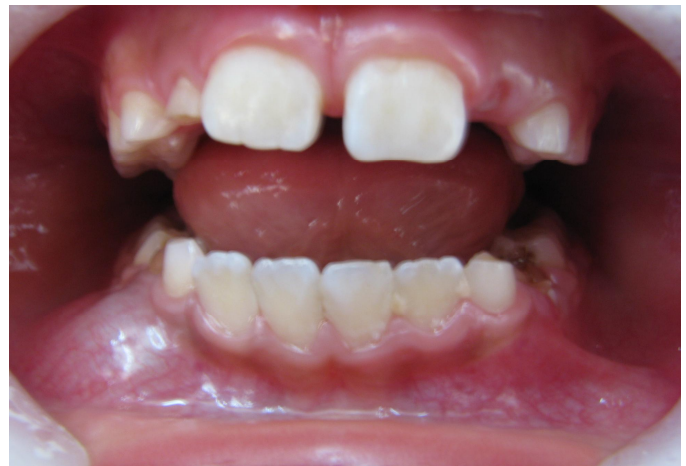

Fig.1a

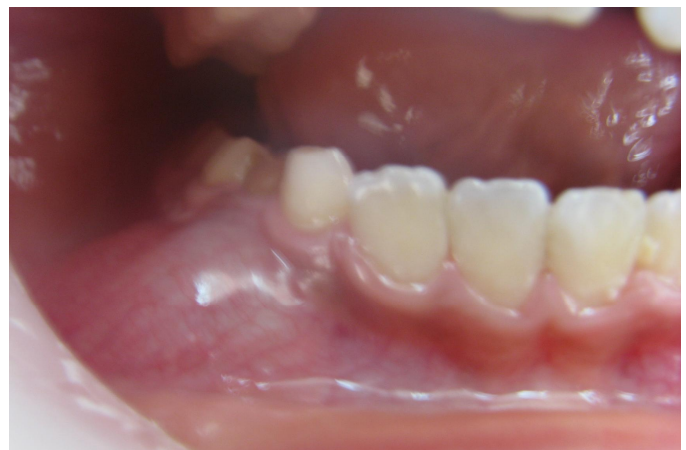

Fig. 1b

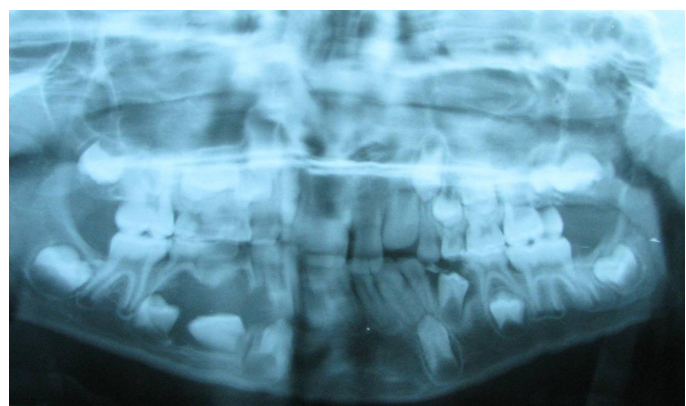


Fig. 2

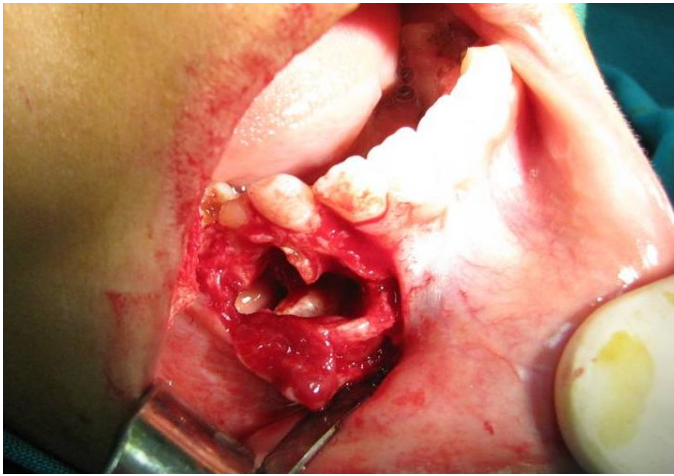


Fig. 3

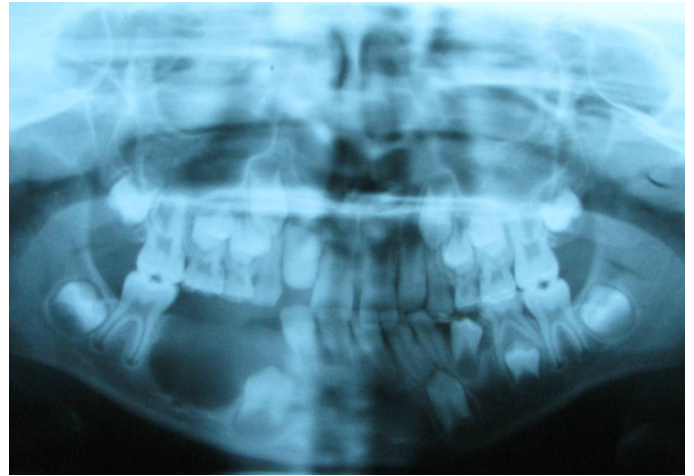

Fig. 6

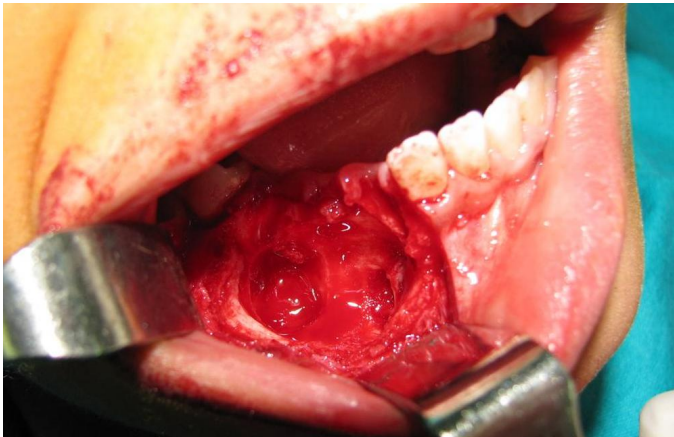


Fig. 4

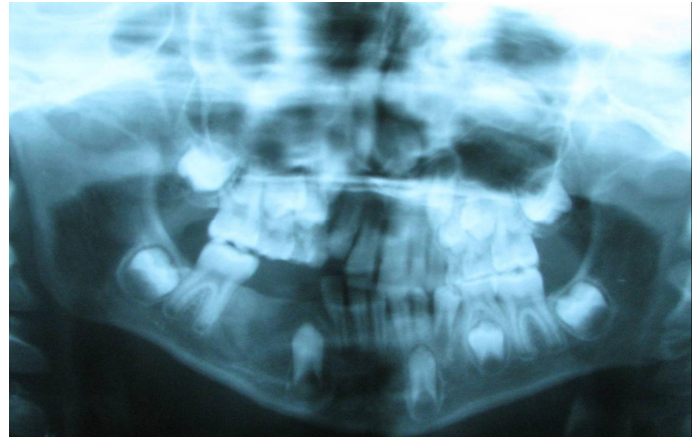

Fig.7

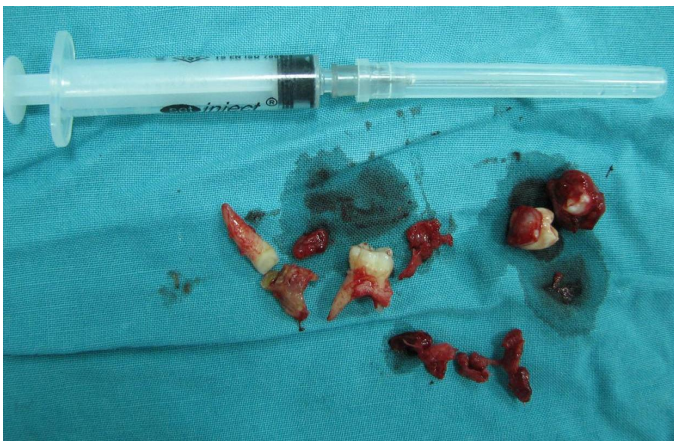

Fig. 5

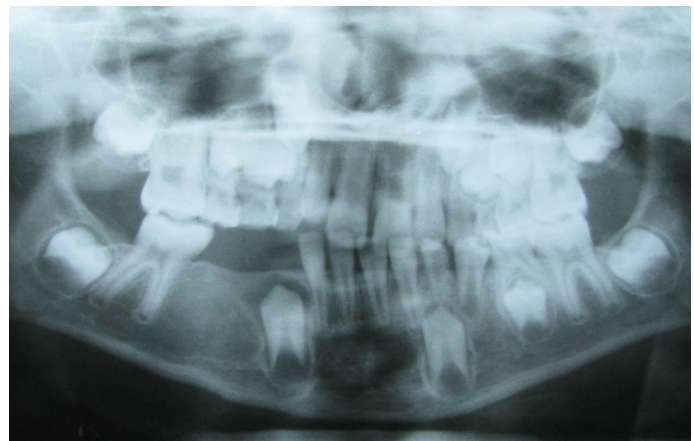


Fig. 8

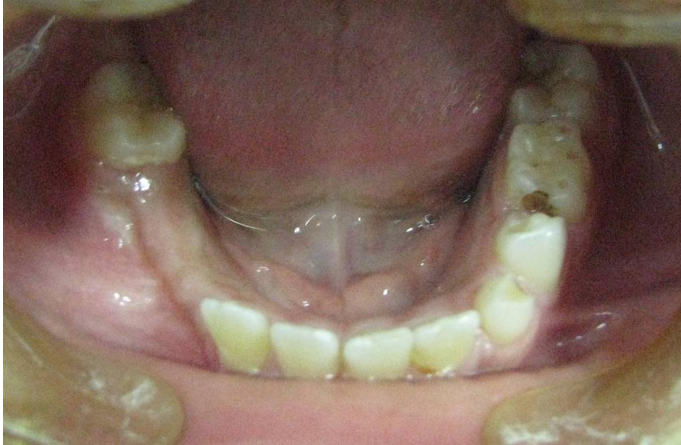

Fig. 9

Discussion

Ameloblastoma is rare before the age of 10 years. According to statistical analysis of 1036 cases of ameloblastoma collected from the literature by Small et al¹⁶, only 2% of cases occur before 10 years of age.

The ameloblastoma is statistically more frequent in the molar region and branch of the jaw, while in the maxilla it is often found in the molar region, even if in some cases the maxillary cavity is interested.

The radiographic appearances of the early stages of ameloblastoma are not characteristic - a local area of bone destruction of cyst-like, often unilocular, appearance. This is not surprising as it is generally recognised that ameloblastoma may arise in the wall of a non-neoplastic cyst as a result of neoplastic change. In its later stages ameloblastoma presents an expansile lesion with multilocular, rounded radiolucencies. At this stage the differential diagnosis of giant cell tumourous conditions, fibromyxoma and fibrous dysplasia should be considered. However, a single compartment lesion may persist, especially in the maxilla. As the tumour grows, the multilocular lesion appears more distinct and radiographic diagnosis is more accurate.

Recurrence of an ameloblastoma in large part reflects the inadequacy or failure of the primary surgical procedure¹⁷. The treatment is an important prognostic factor, as suggested in several studies^{18,19,20}. Various treatment methods for the lesion in relation to many factors, such as the tumour size and location, have been suggested. These include enucleation, marginal resection and aggressive resection.

Due to the strong likelihood of a recurrence, curettage or mass excision without a safety margin is not recommended for the treatment of an ameloblastoma, especially the follicular, granular

and acanthomatous types. When a diagnosis of ameloblastoma is obtained, the treatment must be aggressive and radical. This concurs with the opinion that a resection of the jaw should be approximately 1,5–2 cm beyond the radiological limit, in order to ensure that all the microcysts and daughter cysts are removed as demonstrated by Olaitan Et Al.²¹, Pandya and Stuteville²² advocated that the excised ameloblastoma mass should include at least a 2 cm margin of uninvolved bone around the tumour²³.

We needed a pathologic report and a clinical finding to distinguish the clinical classification, which affected the treatment plan. Some reports have mentioned that

unicystic-type ameloblastoma are generally removed as a dentigerous cyst without preoperative biopsy²⁴, and Isacson and associates²⁵ considered biopsies of a cystic lesion not to be recommended; all of the tissue must be included for a proper diagnosis. We considered that incision biopsy is important for any lesion with impression of cyst or ameloblastoma on radiography. We suggest checking the content of the tumor before doing the incision biopsy by aspiration first, then excise a part of the lesion as a specimen for pathologic examination, then use a curette or blunt instruments to detect the consistency of the lesion, whether having a cavity or being solid. If the cavity exists on clinical examination and pathologic findings confirm the ameloblastoma, we suggest performing a decompression procedure to decrease the pressure of the lesion (and this may decrease its size), and perform "enucleation biopsy" to get a proper specimen for a serial section examination.

Computed tomography and multiple resonance imaging examination will be helpful to detect the extension of the lesion²⁶. We suggest when cystic-type ameloblastoma

is confirmed, no matter whether unicystic or multicystic, the decompression procedure can be considered first. 6 to 12 months later the lesion might be obviously decreased²⁷, which may reduce the possibility of injury to the neurovascular bundle and help maintain the continuity of the jaw bone.

Conclusion

Unicystic ameloblastoma is a tumour with a strong propensity for recurrence, especially when the ameloblastic focus penetrates the adjacent tissue from the wall of the cyst. The ability to predict this potential occurrence prior to surgery would greatly enhance therapeutic strategies for reducing the incidence.

It should be emphasized that despite a clinical diagnosis of periapical disease of endodontic origin,

a nonodontogenic lesion may be present, as was evident in this case. In this study we aim to diagnose, treatment and follow up a unicystic ameloblastoma case -which is seen rarely in children- in 8 years old boy. There is no recurrence for two years follow up.

References

1. Takahashi K, Miyauchi K, Sato K. Treatment of ameloblastoma in children. *Br J Oral Maxillofac Surg* 1998;36:453-6.
2. Robinson L, Martinez MG. Unicystic ameloblastoma: A prognostically distinct entity. *Cancer* 1977;40:2278-85
3. Kramar IR, Pindborg JJ, Shear M. WHO international classification of tumours: histological typing of odontogenic tumours. Berlin: Springer-Verlag, 1992.
4. Gunhan O, Erseven G, Ruacan S, et al. Odontogenic tumours: a series of 409 cases. *Aust Dental J* 1990;35(6):518-22.
5. Lucas RB. Ameloblastoma. In: Lucas RB, editor. *Pathology of tumours of the oral tissues*. 2nd ed. Edinburgh: Churchill Livingstone, 1984:31-60
6. Olaitan AA, Adekeye EO: Clinical features and management of ameloblastoma of the mandible in children and adolescents. *Br J Oral Maxillofac Surg* 34:248, 1996
7. Reichart PA, Philipsen HP, Sonner S: Ameloblastoma: Biological profile of 3677 cases. *Oral Oncol Eur J Cancer* 31B:86, 1995
8. Ackermann GL, Altini M, Shear M: The unicystic ameloblastoma: A clinicopathological study of 57 cases. *J Oral Pathol* 17:541, 1988
9. Olaitan AA, Adekeye EO: Unicystic ameloblastoma of the mandible: A long term follow-up. *J Oral Maxillofac Surg* 55:345, 1997
10. Ackermann GL, Altini M, Shear M: The unicystic ameloblastoma: A clinicopathological study of 57 cases. *J Oral Pathol* 17:541, 1988
11. Leider AS, Eversole LR, Barkin ME: Cystic ameloblastoma: A clinico-pathologic analysis. *Oral Surg Oral Med Oral Pathol* 60:624, 1985
12. Crawley WA, Levin LS. Treatment of the ameloblastoma: a controversy. *Cancer* 1978: 42: 357-363
13. Williams TP. Management of ameloblastoma: a changing perspective. *J Oral Maxillofac Surg* 1993: 51: 1064- 1070.
14. Neville BW, Damm DD, Allen CM, Bouquot JE. *Oral and Maxillofacial Pathology*. Philadelphia: W. B. Saunders 1995: pp. 512-520.
15. Small IA, Waldron CA. Ameloblastomas of the jaws. *J Oral Surg* 1955: 8: 281- 297.
16. Regezi JA, Sciubba JJ. *Oral Pathology: Clinical-Pathologic Correlation*. Philadelphia: WB Saunders 1989: pp. 363-374.
17. Crawley WA, Levin LS. Treatment of the ameloblastoma: a controversy. *Cancer* 1978: 42: 357-363.
18. Small IA, Waldron CA. Ameloblastomas of the jaws. *J Oral Surg* 1955: 8: 281- 297.
19. Olaitan AA, Adeola DS, Adekeye EO. Ameloblastoma: clinical features and management of 315 cases from Kaduna, Nigeria. *J Craniomaxillofac Surg* 1993: 21: 351-355.
20. Adekeye EO. Ameloblastoma of the jaws: a survey of 109 Nigerian patients. *J Oral Surg* 1980: 38: 36-41.
21. Demeulemeester LJ, Mommaerts MY, Fossion E, Bossuyt M. Late loco-regional recurrences after radical resection for mandibular ameloblastoma. *Int J OralMaxillofac Surg* 1988: 17: 310- 315.
22. Mosadomi A. Odontogenic tumours in an African population. Analysis of twentynine cases seen over a 5-year period. *Oral Surg Oral Med Oral Pathol* 1975: 40: 502-521.
23. Olaitan AA, Adeola DS, Adekeye EO. Ameloblastoma: clinical features and management of 315 cases from Kaduna, Nigeria. *J Craniomaxillofac Surg* 1993: 21: 351-355
24. Gardner DG. A pathologist's approach to the treatment of ameloblastoma. *J Oral Maxillofac Surg* 1984;42:161-6.
25. Isacsson G, Andersson L, Forslund H, Bodin I, Thomsson M. Diagnosis and treatment of the unicystic ameloblastoma. *Int J Oral Maxillofac Surg* 1986;15:759-64.
26. Cihangiroglu M, Akfirat M, Yildirim H. CT and MRI findings of ameloblastoma in two cases. *Neuroradiology* 2002;44:434-7.
27. Nakamura N, Higuchi Y, Mitsuyasu T, Sandra F, Ohishi M. Comparison of long-term results between different approaches to ameloblastoma. *Oral Surg Oral Med Oral Pathol Oral Radiol Endod* 2002;93:13-20.