

A CASE REPORT: LUDWIG'S ANGINA IN A PATIENT WITH SYSTEMIC LUPUS ERYTHEMATOSUS (SLE) AND FAMILIAL MEDITERRANEAN FEVER (FMF)

Mustafa Yalcin^{1*}, Serahim Serhat Atilgan², Ferhan Yaman², Nihat Lacin¹, Necat Aslan¹,
Nedim Günes³, Haluk Yener Unsal¹, Yusuf Atalay⁴

1. Research Assistant , Dicle University, Faculty of Dentistry, Department of Oral and Maxillofacial Surgery.

2. Associate Professor , Dicle University, Faculty of Dentistry, Department of Oral and Maxillofacial Surgery.

3. Assistant Professor, Dicle University, Faculty of Dentistry, Department of Oral and Maxillofacial Surgery.

4. Assistant Professor , Afyon Kocatepe University, Faculty of Dentistry, Department of Oral and Maxillofacial Surgery.

Abstract

Ludwig's angina is potentially life-threatening, rapidly spreading involving bilaterally submandibular, sublingual and sub mental spaces. It is characterized by induration of mouth, swelling, elevation of tongue and airway obstruction. There is three main points with early diagnosis which are airway management, intravenous antibiotic therapy and surgical intervention. We present a case of Ludwig's angina in a 14-year-old boy. The etiology, management and potential complications of Ludwig's angina are discussed.

Case report (J Int Dent Med Res 2014; 7: (3), pp. 60-62)

Keywords: Ludwig's angina, systemic diseases and, maxillofacial infection.

Received date: 28 august 2014

Accept date: 11 November 2014

Introduction

Ludwig's angina is potentially life-threatening, rapidly spreading involving bilaterally submandibular, sublingual and submental spaces.¹ Ludwig's angina was described by Wilhelm Frederick von Ludwig in 1836 as a rapidly progressive, gangrenous cellulitis and edema of the soft tissues of the neck and floor of the mouth.² It is characterized by brawny induration and elevation of the tongue with the airway obstruction.³ Mortality rates for Ludwig's angina exceeded 50% in the pre-antibiotic era.⁴ As a result of antibiotic therapy, mortality recently averages approximately 8 %.⁵⁻⁶ Mortality is a result of upper airway obstruction.⁷⁻⁸

Odontogenic infection is the major etiologic factor of the Ludwig's angina and primarily resulting from infection of the second and third molars.⁶⁻⁹ The roots of these teeth

penetrate the mylohyoid ridge and because of that any dental infection or abscess has gateway to the submaxillary space.¹⁰ Infection spreads contiguously to the sublingual and submental space, posteriorly to the parapharyngeal and retropharyngeal space.¹¹⁻¹² Other etiologic factors are mandibular fractures, oral lacerations, infection of an oral malignancy, peritonsillar or parapharyngeal abscesses and submandibular sialadenitis.¹⁰ Predisposing factors include dental caries, recent dental treatment, systemic illness such as malnutrition, diabetes mellitus, compromised immune system such as immunodeficiency syndrome (AIDS), organ transplantation and trauma.¹³⁻¹⁴

Case Report

A 14- year-old boy was presented to our clinic complaining of severe painful tissues to the touch, diffuse swelling, difficulty swallowing. In his medical history, systemic lupus erythematosus (SLE) and Familial Mediterranean Fever (FMF) were present. The patient was febrile (temperature 38.4 °C), blood pressure was 123 / 72 mm Hg, and he was seemed uncomfortable, anxious, toxic appearance (Figure 1a). The patient's erythrocyte sedimentation rate (ESR) was 27 mm/h and

*Corresponding author:

Dr. Mustafa Yalcin
Dicle University, Faculty of Dentistry,
Department of Oral and Maxillofacial Surgery ,
Diyarbakir ,Turkey

E-mail: worldentist@hotmail.com

white blood cells (WBCs) were $15,3 \times 10^3/\mu\text{L}$. The patient weighted 55 kg, heighted 170 cm and had a bodily mass index of 19.

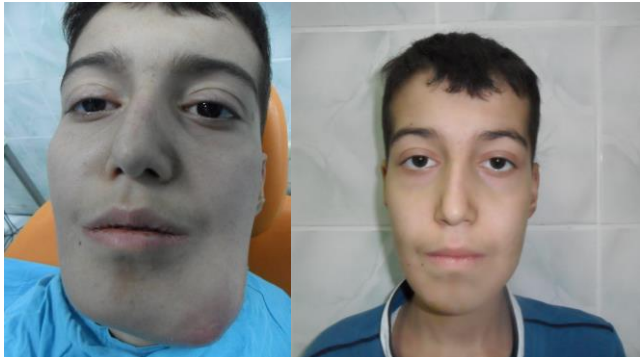

Figure 1a **Figure 1b**
Figure 1a-1b. Preoperative and Postoperative Extraoral

In the radiographic examination, bilateral first molar teeth were detected as etiologic factor of Ludwig's angina (Figure 3a).

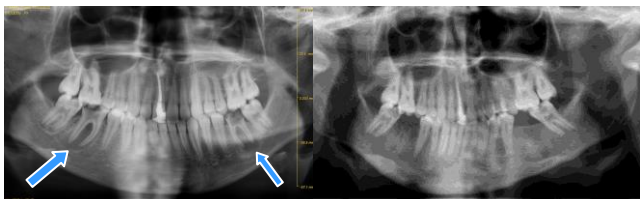


Figure 3a **Figure 3b** (3 months later)
Figure 3a-3b. Preoperative and Postoperative OPG

During the intraoral examination, floor of mouth induration caused elevation of the tongue and floor of mouth was palpated that filling with the purulent matter (Figure 2a).

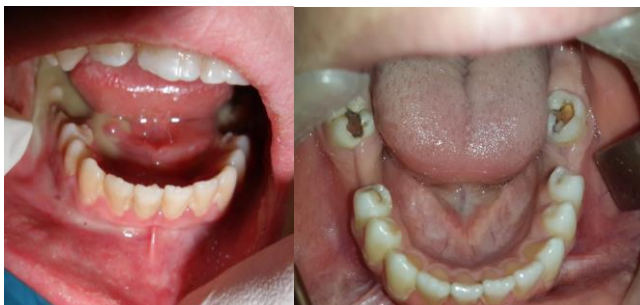

Figure 2a **Figure 2b**
Figure 2a-2b. Intraoral Preoperative and Postoperative

Mouth opening was 2,5 cm .There was firm induration of submental and right submandibular region. Additionally, left

submandibular and sublingual space was widespread swelling, fluctuating and erythema. The patient was diagnosed as a Ludwig's angina.

Corticosteroids are used to due to SLE. Therefore antibiotic prophylaxis was recommended for 3 days before the surgery. The patient had received twice a day with crystallized penicillin 800,000 units intravenously.

The patient was prepared for surgical intervention, provided asepsis and antisepsis. Extraoral and intraoral incision was made to drain of pus. Extraoral drainage was made the most fluctuant point of left mandible and intraoral, first lingual aspect of incisor teeth and bilateral buccal sulcus of premolar teeth. Blunt scissors was introduced to open up the tissue spaces and pus was drained. The wound was irrigated with normal saline and drain was placed and fixed to the skin with silk sutures. Postoperatively, crystallized penicillin intravenously, non-steroid anti-inflammatory were prescribed for 7 days. Postoperative irrigation was done within the drain and likewise intraoral three drainage point. Subsequently, drain was taken three days later and also infected right, left first mandibular molar teeth were extracted in the fifth day after mouth opening was provided and curettage was done. During this time, the patient was recommended that applied hot application over swelling surface. Every day for one week, 15th day, 1st month and 2nd month, the patient were followed and observed that swelling, erythema, pus, tongue elevation disappeared, sufficient mouth opening (Figure 2b).

Discussion

Ludwig's angina generally has a dental origin and developing from mandibular molar teeth infection, periapical abscess (70-90 %).¹⁵ Although one report has shown that second or third molars caused infection and continued down the mylohyoid line of the mandible into the submaxillary space, our patient's infection originated at the bilateral first mandibular molar teeth.¹⁶

One third of cases associated with systemic diseases like diabetes mellitus, compromised immune system illnesses (AIDS, HIV+), lupus erythematosus, neutropenia, glomerulonephritis and aplastic anemia.¹⁷ Maxillofacial spatial infections are complicated in patients with compromised immune system

such as SLE. Our patient had FMF and treatment of lupus erythematosus so that used corticosteroids and ferrous glycine sulphate complex and B vitamins complex.

Submandibular space is main infection region of the Ludwig's angina.⁷ This space subdivided by the mylohyoid muscle into the sublingual space superiorly and the submaxillary space inferiorly. This space bounded superiorly by the floor of mouth mucosa and inferiorly by the superficial layer of deep cervical fascia.¹¹⁻¹² Submandibular space infection can spread posteriorly to the retropharyngeal space and then mediastinum and causing mediastinitis.

Treatment of the Ludwig's angina should include airway control, intravenous antibiotics and surgical intervention. A patient with Ludwig's angina primarily should be secured airway management. In a retrospective review, 10% of children with Ludwig's angina needed airway control, whereas 52 % of patients > 15 years of age underwent tracheostomy.¹⁸ In our patient, there is no need to endotracheal intubations, tracheostomy or monitorizing for airway control. Intravenous antibiotics provide to treat and limit the spreading of infection. Antibiotics used before the antibiogram results, have been penicillin G intravenous, aminoglycosides, metronidazole, clindamycin, gentamicin. Steroid therapy has been suggested as a mean of reducing soft tissue swelling and edema and diminishing the potentiality for the need of a surgical airway in Ludwig's angina.⁷⁻¹⁹⁻²⁰ In the surgical intervention, all patients underwent incision and drainage. Surgical drainage requires large incisions exposing infected spaces and drains are inserted postoperatively.⁷

Conclusion

Ludwig's angina is a potentially lethal cellulitis of the submandibular, sublingual and submental spaces which was largely fatal during pre-antibiotic era. Airway control, aggressive intravenous antibiotic therapy and surgical decompression and debridement are the prior treatment approach. As a medical therapy, our patient took ferrous glycine sulphate complex and corticosteroids due to his systemic disease. In Ludwig's angina, patients who have systemic diseases like our patient, need antibiotic prophylaxis and consultation.

Declaration of Interest

The authors report no conflict of interest and the article is not funded or supported by any research grant.

References

1. Saifeldeen K , Evans R , Ludwig's angina , Emerg Med J. 2004;21:242-3 .
2. Muckleston HW. Angina Ludovici and kindred affections: historical and clinical study .Ann Otol Rhinol Laryngol . 1928;37:711-735
3. J. Burke, Angina Ludovici: a translation ,together with a biography of Wilhelm F.V. Ludwig, Bull. Hist. Med. 1939;7: 1115-1126
4. A.C. Williams, Ludwig's angina , Surg. Obstet. Gynecol. 70 1940; 140-149
5. Bransal A ,Miskoff J , Lis RJ. Otolaryngologic critical care. Crit Care Clin. 2003;19:55-72
6. Moreland LW, Corey J , McKenzie R. Ludwig's angina. Report of a case and review of the literature. Arch Intern Med. 1988; 148:461-6
7. Spitalnic SJ , Sucov A. Ludwig's angina : case report and review. J Emerg Med. 1995;13: 499-503
8. Britt JC ,Josephson GD, Gross CW . Ludwig's angina in the pediatric population : report of a case and review of the literature. Int J Pediatr Otorhinolaryngol. 2000;52:79-87
9. D.S. Sethi,R.E. Stanley ,Deep neck abscesses – changing trends, J. Laryngol. Otol. 1994; 108: 138-143.
10. Fischmann GE,Graham BS. Ludwig's angina resulting from the infection of an oral malignancy. J Oral Maxillofac Surg. 1985;43:795-6
11. M. Grodinsky, Ludwig's angina : an anatomical and clinical study with review of the literature, Surgery 5 (1939) 678-696.
12. H. H. Linder. The anatomy of the fasciae of the face and neck with particular reference to the spread and treatment of intraoral infections(Ludwig's) that have progressed into adjacent fascial spaces , Ann. Surg. 1986; 204(6): 705-714
13. Owens BM, Schuman NJ.Ludwig's angina.Gen Dent. 1994;42:84-7
14. Finch RG, Snider GE, Jr, Sprinkle PM.Ludwig's angina. JAMA. 1980;243:1171-3
15. Ho MP,Tsai KC, Yen SL ,Yu CL, Chen CH.A rare cause of Ludwig's angina by Morganella morganii . J Infect. 2006;53: 191-4
16. Tsshiasny K. Ludwig's angina : an anatomic study of the lower molar teeth in its pathogenesis. Arch Otolaryngol. 1943;38: 485-496
17. Chou YK, Lee CY, Chao HH. An upper airway obstruction emergency :Ludwig angina. Pediatr Emerg Care. 2007;23:892-6
18. Kurein M, Mathew J, Job A, Zachariah N.Ludwig's angina. Clin Otolaryngol Allied Sci. 1997;22:263-265
19. W. F. Ludwig, " Über eine in neuerer Zeit wiederholt hier vorgekom mene Form von Halsentzündung. Medicinisches Correspondenzblatt des Württembergischen ärztlichen Vereins," Stuttgart , 1836; 6: 21-25.
20. B. Freund and C. Timon, " Ludwig's angina: a place for steroid therapy in its management?" Oral Health , 1992; 82(5): 23-25.