

Oral Mucosal Burn Caused by Topical Application of 36% Policresulen Solution – A Case Series

Indriasti Indah Wardhany^{1*}, Yuniardini Septorini Wimardhani¹, Anandina Irmagita Soegyanto¹

1. Department of Oral Medicine, Faculty of Dentistry, Universitas Indonesia, Jakarta 10430, Indonesia.

Abstract

Trauma of the oral mucosa could be the result from chemical, thermal, mechanical, radiation or electrical injuries, and it manifested as oral mucosal burn. Most of the oral mucosal chemical burn manifested as localized or diffuse area of ulcer or sloughing. The severity of this manifestation depends on the concentration of the substance and intensity of substance contact. Policresulen is a polymolecular organic acid and has therapeutic properties as a local hemostatic and antimicrobial agent along with a stringent properties.

Case presentation: We are reporting six cases of oral mucosal burn due to topical use of policresulen. The clinical findings were vary including edema of the lips, ulceration, wide area of sloughing covering the underlying loss of mucosal integration and hemorrhagic crust of the lip.

Conclusion: Regarding the easy access and easy use policresulen topical solution, there are disadvantages of using them without proper technique and instruction.

There is a need to increase awareness and consideration of public, health professionals and Indonesian food and drug administration in using this medication and also the awareness of dentist in developed country since Indonesian overseas workers might bring along this drug.

Case report (J Int Dent Med Res 2016; 9: (Special Issue), pp. 387-391)

Keywords: Oral mucosal burn, policresulen, chemical burns.

Received date: 28 September 2016

Accept date: 29 October 2016

Introduction

Oral ulceration is very common and the etiologies are varied, including infection, autoimmune disorders immune disorders, trauma, vitamin deficiency, neoplastic / hematological and/or idiopathic.¹

Trauma of the oral mucosa could be the result from chemical, thermal, mechanical, radiation or electrical injuries, and it manifested as oral mucosal burn.¹⁻³ Chemical are less common cause,⁴ examples include local application of medication (aspirin, Tetracycline hydrochloride),^{1,3-5} topical use of illicit psychoactive drug (Cocaine, cannabis),^{4,6,7} some materials which commonly used in dentistry (Sodium Hypochlorite, hydrofluoric acid, toothpaste),^{3-5,10,11,17,18} and non-pharmaceutical

substances (propolis, garlic).^{4,8,9} Most of the oral mucosal chemical burn manifested as localized or diffuse area of ulcer or sloughing.²⁻¹¹ The severity of this manifestation depends on the concentration of the substance and intensity of substance contact.²

Policresulen is a polymolecular organic acid and classified by MIMS as a skin antiseptic and disinfectant.¹² The therapeutic properties of this substance are as a local hemostatic and antimicrobial agent along with astringent properties.^{13,14} Although policresulen is well known as a common prescript hemostatic agent for anal and gynecologic problems, in Indonesia this drug is also claimed to be safely use as over the counter oral topical agent. We here report six cases of oral mucosal burn due to topical use of policresulen.

Case Presentations

Case 1

A 28-year-old female patient came to oral medicine clinic complaining for oral ulceration and upper lip swelling since a week ago. Previously, she had topically applied policresulen

*Corresponding author:

Indriasti Indah Wardhany
Department of Oral Medicine,
Faculty of Dentistry, Universitas Indonesia,
Jakarta 10430, Indonesia.
E-mail: indriasti.indah@ui.ac.id

with cotton tip and rinsed with the water diluted concentrate to treat her traumatic ulcer on upper labial mucosa. Afterward, her entire mouth felt pain and the lip was swollen. She experienced difficulty to speak, eat and swallow. Clinical examination showed an enlarged upper lip, with multiple irregular ulcers all over the oral mucosa. The patient was diagnosed to have mucosal burn and treated with topical corticosteroid preparation along with the discontinuation of policresulen use.

Case 2

A 34-year-old male patient reported to oral medicine clinic with a chief complaint of pain on the left side of his mouth since a week ago. Two weeks before the complaint, he had diagnosed of having Herpes Zoster on his left side of the face and mouth. He had a week prescription of oral antiviral, analgesic and multivitamin for the herpes zoster. Since there was no prescription for the oral ulcers, he had topically applied policresulen drop combine with soak and rinse the ulcer with policresulen water diluted concentrate. He experienced difficulty to eat and continuous pain on his left side of the mouth especially on the gingival. Clinical examination showed an enlarged lower lip along with a wide area of sloughing on his upper and lower left side of the gingival and left buccal mucosa.

The diagnosis of mucosal burn was establish and treated with oxygen mouth rinse, doloneurobion, multivitamin and nutrition supplement, along with the discontinuation of policresulen use.

Case 3

A 43-year-old male patient reported to oral medicine clinic with chief complaint of pain, uncomfortable feeling and numbness on his right side of the mouth. Previously he had topically applied policresulen drop to treat his traumatic ulcers on the right buccal mucosa and hard palatine. He experienced pain which extend to his hard palate and lower right gingival along with numbness, right after the using of preparation. Clinical examination showed an area of sloughing and ulcer on right buccal area, also a healing ulcer on right hard palatine. The diagnosis of mucosal burn and traumatic ulcers was establish and treated with oxygen gel, gauze the lesion using chlorhexidine gluconate 0.2% mouth rinse using sterile gauze and multivitamin, along with the discontinuation of policresulen use.

Case 4

A 28-year-old male patient reported to oral medicine clinic with chief complaint of dryness and laceration on his upper lip since a week ago along with diarrhea. In the last two days, his lip condition is getting worse since he had applied policresulen on his upper lip using cotton bud. He feels an intense dryness along with scale and bleeding crack. He was diagnose of having hyperthyroid condition on 2014, August and treated with propranolol and propylthioural. He feels a moderate dryness of the lips since he was taking hyperthyroid medicine. Clinical examination showed an edema, scale, fissure and hemorrhagic crust on the upper lip, also fissures on the angular of lips. The diagnosis of oral burn was establish and treated with lips ointment contain antibiotic, corticosteroid, antihistamine and emollient, gauze of the lesion using chlorhexidine gluconate 0,2% mouth rinse using sterile gauze, along with the discontinuation of policresulen use.

Case 5

A 39-year-old female patient reported to oral medicine clinic with chief complaint of crust and laceration on her lower lip since three days ago. She had been applied policresulen using a cotton bud tip on her labial mucosa in order to treat her previous traumatic ulcer. She finds difficulties in putting the substance limited to the ulcer. Clinical examination showed an edema, scale and hemorrhagic crust on her lower lip along with slight sloughing on the lower labial mucosa. The diagnosis of oral burn was establish and treated with gauze of the lesion using chlorhexidine gluconate 0.2% mouth rinse using sterile gauze, along with the discontinuation of policresulen use.

Case 6

A 30-year-old male patient reported to oral medicine clinic with chief complaint of severe pain on his mouth that has been going for three days. He also has difficulties in eating and drinking since the pain was unbearable to him. Previously, he has been using water diluted policresulen as mouthwash twice a day for three days, in order to treat his traumatic ulcers on his right lower labial mucosa. He has been concentrating the mouthwash to soak his ulcers. Clinical examination showed a large area of sloughing and erosion on his mucosa especially in the lower aspect of the mouth. The diagnosis of mucosal burn and traumatic ulcers was

establish and the patient was instructed to gauze the lesion using chlorhexidine gluconate 0.2% mouth rinse using sterile gauze and multivitamin, along with the discontinuation of policresulen use.

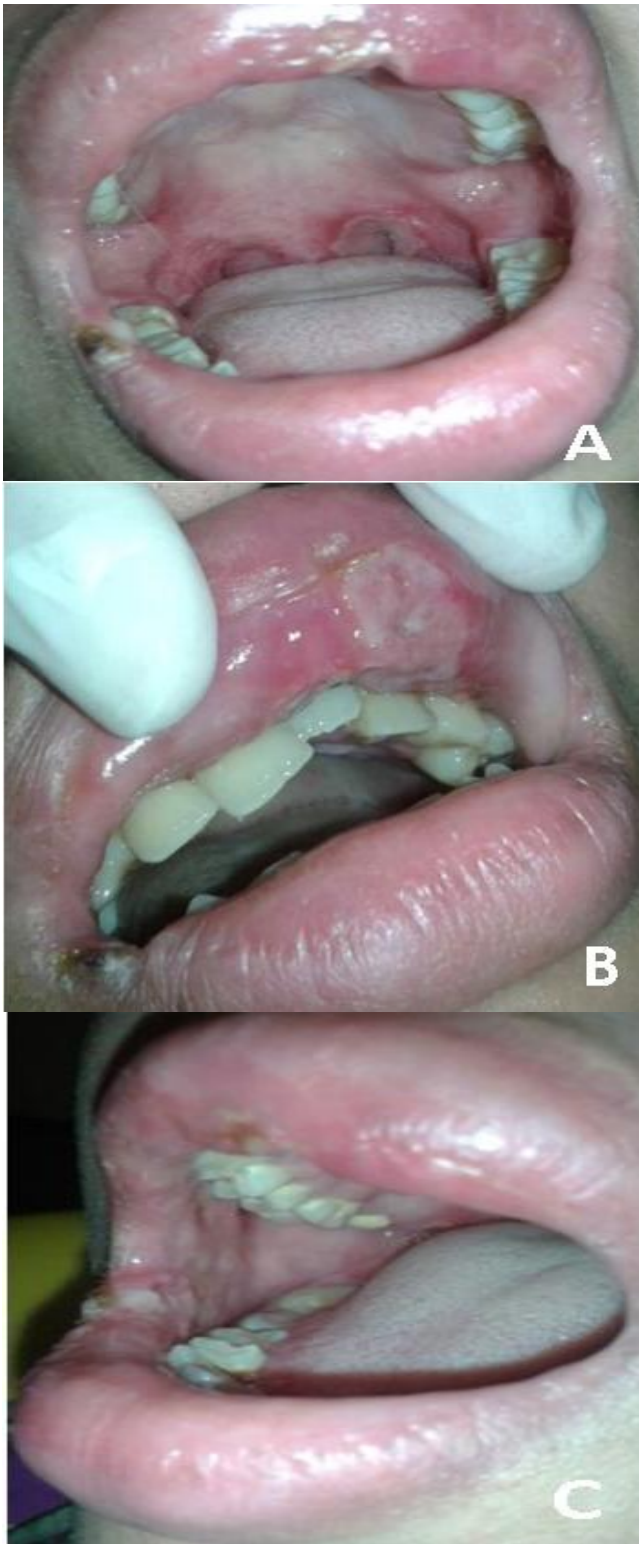


Figure 1. (A-C) Enlarged upper lip, with multiple irregular ulcers all over the oral mucosa.

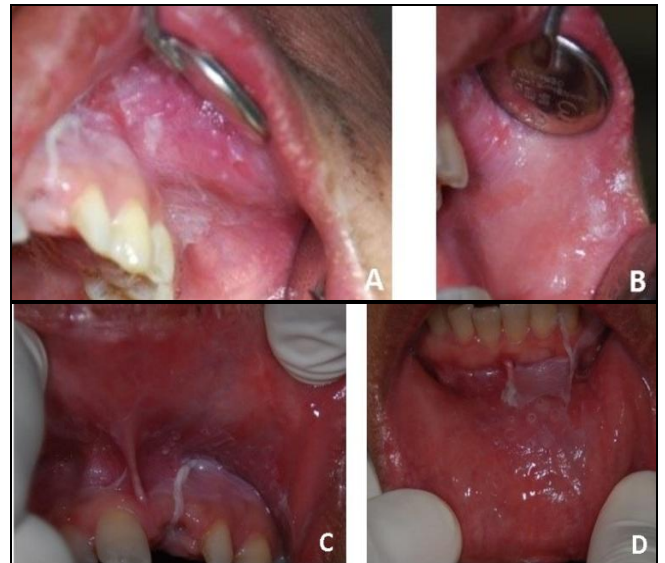


Figure 2. (A-D) Enlarged lower lip along with a wide area of sloughing on his upper and lower left side of the gingival and left buccal mucosa.

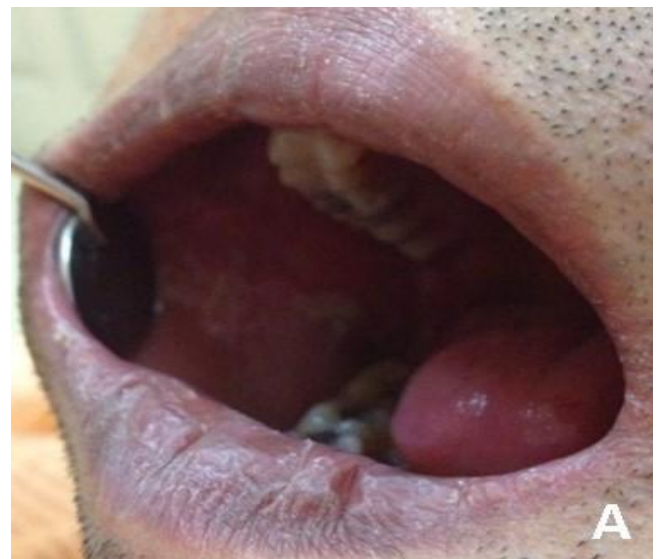

Figure 3. Area of sloughing and ulcer on right buccal area.

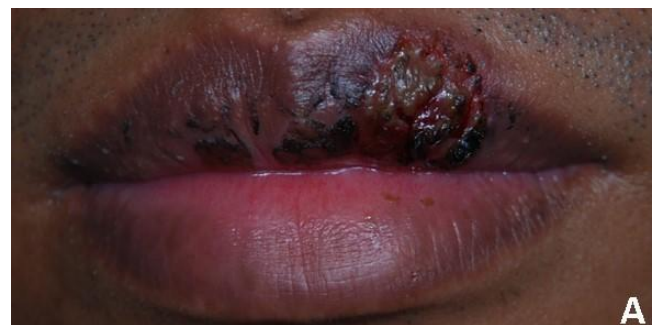

Figure 4. Edema, scale, fissure and hemorrhagic crust on the upper lip, along with fissures on the angular of lips.

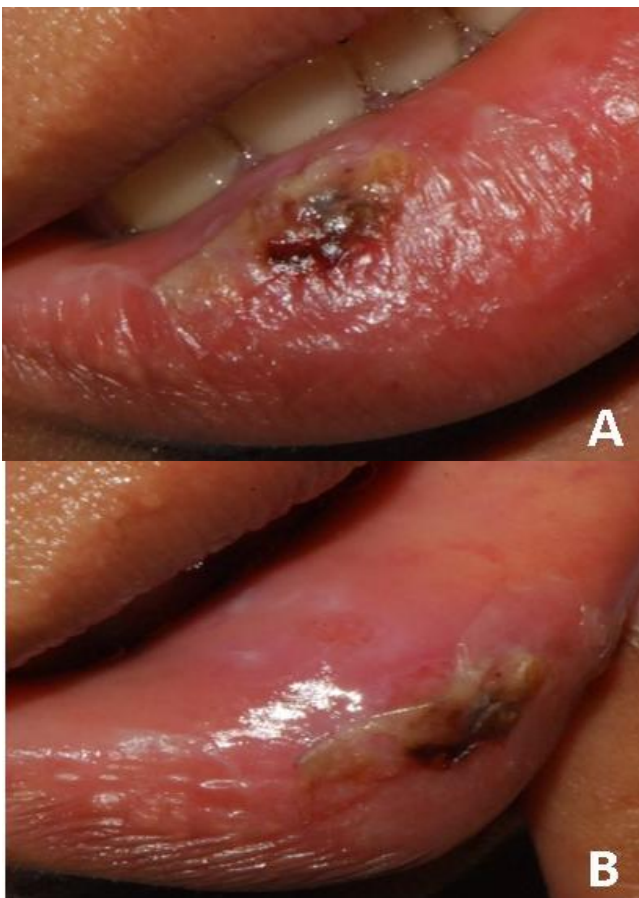


Figure 5. (A,B) Edema, scale and hemorrhagic crust on her lower lip along with slight sloughing on the lower labial mucosa.

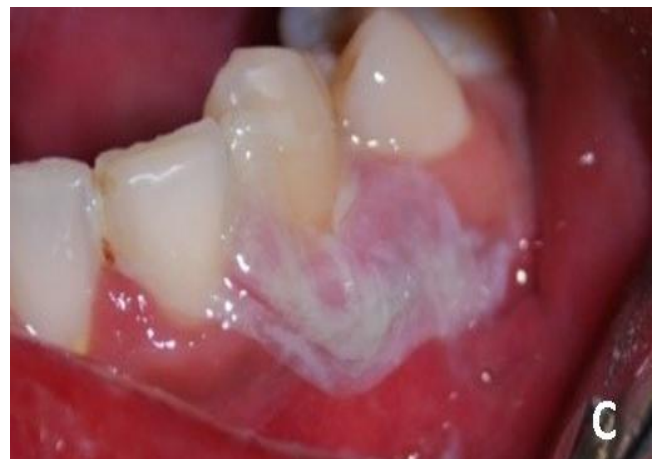
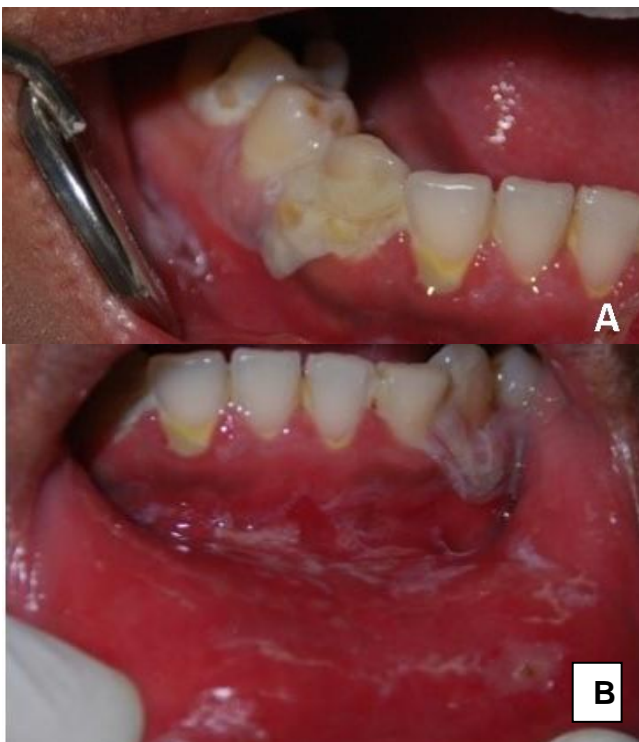
Figure 6. (A-C) Large area of sloughing and erosion on the lower aspect of oral mucosa.

Discussion

Policresulen also known as 101418 – 00 – 2, 2 - hydroxy - 3,5 - bis [(4 - hydroxy – 2 – methyl – 5 - sulfophenyl) methyl] - 4 – methylbenzenesulfonic acid, Policresulene, Policresuleno, Policresulenum, Policresulen 50%¹⁵ is a polymolecular organic acid and a condensation product of metacresolsulfonic acid & methanal.¹² As a hemostatic agent, policresulen controlled the hemorrhage by inducing the muscle fiber of small vessels to contract. The astringent effects of policresulen also suppress the oozing effect of blood vessel during the hemorrhagic episodes. In anorectal disorder, this agent could coagulate necrotic and/or pathogenically altered tissue, thus promotes desquamation of the contact tissue. It also has regeneration and re-epithelization properties following the hyperemia induced by this agent. Policresulen also has an antimicrobial activity.^{13,14}

There are direct and indirect mechanism of mucosal damaged by chemical irritant. The direct mechanism is through their acidic or alkaline properties. The epithelium tissue proteins tend to bind with organic and inorganic acid, causing the coagulated necrosis of the cells. However, the development of coagulum tends to limit the penetration of the acid.^{4,16} Chemically induced oral lesion can affect any mucosal site but more commonly in the site where the caustic agent applied. The clinical presentation of this lesion is similar regardless to it causes, but the severity depends on the caustic level of the substance and the time of exposure. The acute

response to the caustic agent exposure is immediate erythema and edema on the site of exposure, while later a white slough pseudo membrane covering underlying loss of mucosal integration lesion will form.⁴

All of patients in this case report were having a history of using policresulen daily to treat their ulcers, either by soaking, rinsing or dropping it to the ulcers. Regarding to policresulen organic acid properties, the oral lesion can be caused by coagulated necrosis of the cells, resulting to the formation of white slough pseudomembrane covering underlying ulcers. And the severities of the cases depend on concentration of the policresulen and the time of its exposure.²

In Indonesia, this drug is commonly used as oral topical agent for ulcer, since it was an easy to get on over the counter drugs. There are three drug packaging for policresulen which are ovule, topical solution and vaginal gel. According to the manufacture's package insert, this drug is indicated for Local hemostatic, cleansing & tissue regeneration in burns, wounds, chronic inflammatory processes, decubitus lesions, crural ulcers, condyloma acuminata, aphous stomatitis, bacterial vaginosis, vaginal candidiasis and trichomoniasis. Manufacture's user instruction package insert is to apply the concentration directly to the wound for local hemostasis, to dilute the concentration on 1:3 to 1: dilution for burn lesion and diluted the concentration alone or coating policresulen gel or gauze pad over the affected areas for extensive burns.¹²

However, as much as the easy access and easy use policresulen topical solution, there are disadvantages of using them without proper technique and instruction. This drug may not be a preferred option for the patient as it is adverse effect. The oral mucosal damage following the exposure of policresulen is unpredictable and can affect either healthy mucosa or mucosa with lesion. There is a need to increase the awareness of the public in the proper use, mechanism, and adverse reaction of this drug. The health professional especially dentist should be careful in deciding the proper of this drugs delivery, that is more likely in the dental office and institutionalized care setting. The Indonesian Food and drug administration should be considering to reclassify it to the drug that may only be dispensed by prescription. Other thought is that in fact many Indonesian people have work

as an overseas worker in developed country, and it is not impossible that the dentist in those developed country will face the same case as this case series since the worker more likely to bring this drug and having an adverse reaction.

Acknowledgements

We thank the Dental and Oral Hospital, Faculty of Dentistry, Universitas Indonesia; Cipto Mangunkusumo National Hospital for supporting the assessment and treatment of patient. The publication of this manuscript is supported by the Directorate of Research and Community Engagement of the Universitas Indonesia.

Declaration of Interest

The authors report no conflict of interest.

References

1. Hullah EA, Hegarty AM. Oral ulceration: aetiology, diagnosis and treatment. *Dental Nursing*. 2014;10(9):7-19.
2. Kannan S, Chandrasekaran B, Muthusamy S, Sidhu P, Suresh N. Thermal burn of palate in an elderly diabetic patient. *Gerodontology*. 2014;31(2):149-52.
3. Subbaiah R, Thomas B, Maithreyi VP. Self-inflicted traumatic injuries of the gingiva- A case series. *J Int Oral Health*. 2010;2(2):43-9.
4. Gilvetti C, Porter SR, Fedele S. Traumatic chemical oral ulceration: a case report and review of the literature. *BDJ*. 2010;208(7):297-300.
5. Manjunath DM, P Pai G, Madhavan SS. Tetracycline hydrochloride chemical burn as self-inflicted mucogingival injury: A rare case report. *J Indian SocPeriodontol*. 2012;16(2):282-5.
6. Gandara-Rey JM, Diniz-Freitas M, Gandara-Vila P, Blanco-Carrion A, Garcia-Garcia A. Lesions of the oral mucosa in cocaine users who apply the drug topically. *Med Oral Patol Oral Cir Bucal*. 2002; 7:103-7.
7. Scully C. Cannabis; Adverse effects from an oromucosal spray. *BDJ*. 2007;203(6):E12:336-7.
8. Wimardhani YS, Soegyanto AI. Oral mucosal ulceration caused by the topical application of a concentrated propolis extract. *Case Rep Dent*. 2014; Article ID 307646.
9. Bagga S, Thomas BS, Bhat KM. Garlic burn as self-inflicted mucosal injury— A case report and review of the literature. *Quintessence Int*. 2008;39(6):491-4.
10. KM Reddy K, M Reddy P. Toothpaste induced oral burns. *Annals Essences Dent*. 2013;5:30-1.
11. Witton R, Brennan PA. Severe tissue damage and neurological deficit following extravasation of sodium hypochlorite solution during routine endodontic treatment. *BDJ*. 2005;198(12):749-50.
12. <http://www.mims.com/Indonesia/drug/info/Albothyl> (cited April 27, 2016).
13. Gupta PJ. Suppositories in anal disorders: a review. *Eur Rev Med Pharmacol Sci*. 2007; 11: 165-170.
14. Simamora H, Lestari PA, Bangun K, Sudjatmiko G. Curettage and policresulentampon as amodality treatment in management of verucca. *JPRJournal*. 2012: 1(5):460-4.
15. <http://pubchem.ncbi.nlm.nih.gov/compound/Policresulen> (cited April 27, 2016).
16. Sapir S, Bimstein E. Cholinsalicylate gel induced oral lesion: report of case. *J ClinPediatr Dent*. 2000;24:103-6.
17. Özcan M, Allahbeickaraghi A, Dündar M. Possible hazardous effects of hydrofluoric acid and recommendations for treatment approach: a review. *Clin Oral Invest*. 2012;16:15-23.
18. Farren ST, Sadoff RS, Penna KJ. Sodium hypochlorite chemical burn: case report. *NY State Dent J*. 2008;74(1):61-2.