Dentocraniofacial Morphology in Unilateral and Bilateral Cleft Lip and Palate Following Labioplasty and Palatoplasty; Analysis at First and Second Cervical Vertebral Maturation Stage

Devina Yastani[1], Maria Purbiati[2], Ida Ayu Astuti[3,4], Krisnawati[2]*

1. Postgraduate student at Department ofOrthodontic, Universitas Indonesia.
2. Department of Orthodontic, Universitas Indonesia.
3. Department of Oral and Maxillofacial Surgery, Universitas Padjadjaran.
4. Cleft Center Dentistry Faculty, Universitas Padjadjaran.

Abstract

To evaluate dentocraniofacial morphology of children with complete unilateral and bilateral cleft lip and palate following labioplasty and palatoplasty. Analysis was made when the children were at first and second stages of cervical vertebral maturation stage, before the peak of maxillary growth.
Materials and methods: Sixteen digital cephalometric images of subjects with complete unilateral and bilateral cleft lip and palate following labioplasty and palatoplasty were compared with 16 normal stage-matched controls. Cervical vertebral maturation stage was determined by Method of Baccetti et al (2002). Statistics included tests for normal distribution, paired t test, and anova with the significance level $p < .05$.

There were significant cephalometric differences in UI / Mx Plangle between unilateral and control; ANB angle, SN / MP angle, UI/MxPlangle between bilateral and normal; SNA angle, UI/MxPl angle between unilateral and bilateral group.

The inclination of upper incisor was most affected by cleft lip and palate.The maxilla inclination was found a little retrusive for unilateral cleft lip and palate, while a little protrusive for bilateral. Sagittal relationship of bilateral was found the most protrusive followed by normal and unilateral group. Mandibular steepness was found for bilateral cleft lip and palate.

Clinical article (J Int Dent Med Res 2016; 9: (Special Issue), pp. 282-286)

Keywords: Cephalometrics, complete unilateral cleft lip and palate, bilateral cleft lip and palate, dentocraniofacial morphology.

Received date: 28 September 2016 **Accept date:** 29 October 2016

Introduction

Cleft lip and palate is the most common congenital malformation in craniofacial region. Cleft lip and palate usually impacts craniofacial development and needs multidisciplinary treatment.[1,2] The initial therapies usually are labioplasty followed by palatoplasty to restore functional activities and aesthetics. Some studies showed midfacial deficiencies a couple years after surgery.[3,4] Some studies of unilateral cleft lip and palate undergone labioplasty and palatoplasty, showed retrusion and clockwise rotation of maxillary complex, short maxilla, deficiency of posterior facial height and upper posterior facial height, excessive anterior facial height, upper incisive retroclined, steeper mandibular plane and gonial angle.[5] Patients of bilateral cleft lip and palate have initial prominent premaxilla gradually decreasing its prominence and reaching its anteroposterior approximating unilateral patients at late teen. Other features showed retrusion of mandible, steep mandibular plane, large gonial angle, longer lower anterior facial height, and reduced posterior facial height.[6]

Evaluation following labio plasty and palatoplasty is needed to assess the dentocraniofacial impairment to make treatment planning. Dentocraniofacial deformity often needs growth modification achieved by some mechano therapies (eg. facemask, combination of facemask and rapid maxillary expansion (RME), and RME) in proper timing.

Corresponding author:
Maria Purbiati,
Department of Orthodontic, Faculty of Dentistry,
Universitas Indonesia.
Jakarta, Indonesia.

According to Baccetti et al (2001) and Franchi et al (2004), the best time to treat class III malocclusion in cleft lip and palate patients is within the peak of maxillary growth. According to Baccetti et al (2002), peak of maxillary growth occurs at cervical vertebral maturation stage I and II (CVMS I and II).[7, 8]

So far, author found one scientific article regarding craniofacial features of unilateral cleft lip and palate. The parameters consisted of 11 parameters, 10 linear and 1 angular parameters. Besides, the samples were stage II and III cervical vertebral maturation stage. To date, dentocraniofacial features in stage I and II is not known. Angular parameters are preferred, instead of linear, because there is enlargement of objects in cephalometrics since it is two dimensions of patient. Treatment of unilateral and bilateral cleft lip and palate needs angular parameter of dentocraniofacial morphology. The aim of the study is to further comprehend the angular dentocraniofacial morphology in cervical vertebral maturation stage I and II.

Materials and methods

All cleft lip and palate patients were treated in Cleft Center Dentistry Faculty University of Padjadjaran. Labioplasty was done at 3 – 8 months of age, and palatoplasty at 18-36 months of age. All subjects (including normal group) had cervical vertebral maturation stage I and II. Skeletal age was determined by cervical vertebral maturation stage according to Baccetti et al (2002).[9] Normal group had class I skeletal pattern and class I incisors relation.

Kappa test was used to assess intraobserver and interobserver reliability in determining the cervical vertebral maturation stage of the subjects. Seven radiographs of each group were reassessed to examine the intraobserver and interobserver reliability.

For this study, the following angles were calculated: SNA angle, SNB angle, SNPog angle, ANB angle, SN – mandibular plane (SN/MP) angle, SN – maxillary plane (SN/MxPl) angle, maxillomandibular plane angle (MMPA), upper incisir – maxillary plane (UI/MxPl), lower incisor – mandibular plane (LI/MP).

Each radiograph was traced by Cephalometrics Ato Z version 12. All measurements were carried out by one operator. In order to assess intraobserver and interobserver reliability, 7 radiographs from each group were retraced. Intraobserver and interobserver reliability were assessed by paired t test.

Significant differences of each group were assessed using one way anova. All tests for normal distribution, paired t test, and one way anova were set at $p < .05$significance level.

Results

Table 1 and 2 showed intraobserver and interobserver substantial agreement in determining CVMS of all subjects. Table 3 and 4 showed good intraobserver and interobserver reliability in all cephalometrics tracings.

The mean cephalometrics value were compared between group (table 5-7). One way anova and post hoc showed that UI / M x Pl angle was significantly smaller (p = 0,001) between unilateral than the normal group. Between bilateral and normal group, ANB angle is significantly larger (p = 0,020) for bilateral than the normal group. SN/MP angle was also significantly larger for bilateral group (p = 0,041) while UI/MxPl angle was significantly smaller (p = 0,001).

Between unilateral and bilateral group, ANB angle was found smaller for unilateral group, and UI/MxPl angle was smaller for bilateral group (p = 0,001).

		CVMS2		Total	Kappa value
		I	II		
CVMS	I	5	1	6	0.767
	II	1	14	15	
Total		**6**	**15**	**21**	

Table1 Intraobserver CVMS reliability test result.

		CVMSKons		Total	Kappa value
		I	II		
CVMS	I	4	2	6	0,741
	II	0	15	15	
Total		**4**	**17**	**21**	

Table 2. Interobserver skeletal maturation reliability test result.

Parameter (angles)	Measurement I			Measurement II			p value
	Unilateral	Bilateral	Normal	Unilateral	Bilateral	Normal	
SNA	79°±3,2°	82,3°±3,2°	80,6°±2,4°	79°±2,5°	82,3°±3,2°	80,5°±2,1°	0.941
SNB	76,8°±4,3°	76,4°±3,9°	77,7°±3°	76,6°±4,1°	76,4°±4,1°	78°±2,5°	0.967
SNPog	77°±4,5°	76,5°±3,7°	77,4°±3,1°	77°±4,2°	76,4°±3,8°	77,7°±2,9°	0.997
ANB	2,2°±3,6°	5,8°±3,2°	3°±1°	2,4°±3,7°	5,6°±3,5°	2,9°±1,3°	0.934
SN/MxPl	8°±3,2°	10,5°±2,5°	8,7°±3,2°	9,1°±3,1°	10,1°±2,8°	7,6°±2,4°	0.683
SN/MP	39,2°±5,3°	41,6°±3,3°	33,3°±2,2°	39,4°±6,1°	41°±3°	33,2°±2,2°	0.865
MMPA	31,5°±4,2°	31°±4,2°	24,6°±3°	30,2°±4,6°	30,7°±3,8°	24,6°±3,3	0.987
UI/MxPl	100,8°±9,4°	81,9°±9°	117,4°±8,4°	101,4°±9,5°	81,3°±9,1°	117°±8,6°	0.949
LI/MP	90,8°±4°	91,1°±8,2°	99,6°±8,4°	89,4°±3,3°	91,9°±9,1°	92,2°±24,8°	0.972

Table 3. Intraobserver cephalometric reliability test result. *p<0,05, variables that are reaching significance.

Parameter (angles)	1st Observer's measurement			2 nd Observer's measurement			p value
	Unilateral	Bilateral	Normal	Unilateral	Bilateral	Normal	
SNA	79°±3,2°	82,3°±3,2°	80,6°±2,4°	78,7°±3,1°	82,1°±4°	80,3°±2,5°	0.965
SNB	76,8°±4,3°	76,4°±3,9°	77,7°±3°	76,7°±4,1°	76,4°±4 °	77,7°±2,4°	0.991
SNPog	77°±4,5°	76,5°±3,7°	77,4°±3,1°	76,8°±4,4°	76,5°±4°	77,6°±2,2°	0.989
ANB	2,2°±3,6°	5,8°±3,2°	3°±1°	2°±3,5°	5,8°±3,5°	2,6°±1°	0.984
SN/MxPl	8°±3,2°	10,5°±2,5°	8,7°±3,2°	9,3°±3,2°	10,3°±2,7°	7,6°±2,6°	0.818
SN/MP	39,2°±5,3°	41,6°±3,3°	33,3°±2,2°	40,2°±6,8°	40,9°±3,4°	32,1°±2,5°	0.958
MMPA	31,5°±4,2°	31°±4,2°	24,6°±3°	31°±4,6°	30,7°±3,8°	24,6°±3,3	0.906
UI/MxPl	100,8°±9,4°	81,9°±9°	117,4°±8,4°	101,4°±9,5°	81,3°±9,1°	117°±8,6°	0.993
LI/MP	90,8°±4°	91,1°±8,2°	99,6°±8,4°	89,5°±5°	92,1°±8,9°	99,9°±8,3°	0.949

Table 4. Inter observer cephalometric reliability test result. *p<0,05, variables that are reaching significance.

		Mean	SD	CI 95% Lower Limit	CI 95% Upper Limit	Min	Max	P one-way anova	P post hoc
SNA	Unilateral	77,26	3,65	75,32	79,21	70,67	82,81	0,003	U-N = 0.052
	Bilateral	81,85	4,50	79,45	84,24	71,92	90,56		B-N = 0.925
	Normal	80,50	2,75	79,03	81,96	76,24	86,24		U-B = 0.003*
SNB	Unilateral	76,57	3,67	74,61	78,52	70,26	84,16	0,190	
	Bilateral	75,40	4,60	72,95	77,86	67,44	83,02		
	Normal	77,95	3,22	76,23	79,66	72,33	84,20		
SNPog	Unilateral	76,64	3,75	74,64	78,64	70,42	84,58	0,237	
	Bilateral	75,43	4,76	72,90	77,97	67,11	84,55		
	Normal	77,88	3,43	76,06	79,71	71,57	84,38		
ANB	Unilateral	0,75	3,56	-1,15	2,64	-4,91	8,17	0,001	U-N = 0.198
	Bilateral	6,44	4,90	3,83	9,05	-3,20	14,24		B-N = 0.020*
	Normal	2,55	1,24	1,89	3,21	0,27	4,11		U-B = 0.002*

Table 5. Measurement results of sagittal plane together with p-value of one-way anova and post hoc. *p<0,05, variables that are reaching significance.

		Mean	SD	CI 95% Lower Limit	CI 95% Upper Limit	Min	Max	P one-way anova	P post hoc
SN/MxPl	Unilateral	9,57	3,85	7,52	11,62	2,76	17,62	0,587	
	Bilateral	8,96	3,30	7,20	10,72	2,19	13,96		
	Normal	8,30	3,22	6,58	10,01	1,98	12,97		
SN/MP	Unilateral	38,76	5,02	36,09	41,44	30,27	45,57	0,045	U-N = 0.407
	Bilateral	40,83	7,09	37,05	44,60	26,21	59,22		B-N = 0.041*
	Normal	35,77	4,21	33,53	38,01	31,28	46,58		U-B = 0.904
MMPA	Unilateral	29,37	6,25	26,03	32,70	19,41	39,71	0,118	
	Bilateral	31,87	6,21	28,56	35,18	21,51	45,82		
	Normal	27,47	5,17	24,72	30,23	18,82	37,88		

Table 6. Measurement results of vertical plane together with p-value one-way anova and post hoc. *p<0,05, variables that are reaching significance.

		Mean	SD	CI 95% Lower Limit	CI 95% Upper Limit	Min	Max	pone-way anova	ppost hoc
UI/MxPl	Unilateral	102,44	12,51	95,77	109,10	75,60	130,63	0,001	U-N = 0.001*
	Bilateral	79,06	10,92	73,24	84,88	60,91	96,19		B-N = 0.001*
	Normal	116,36	6,45	112,92	119,79	104,76	127,94		U-B = 0.001*
LI/MP	Unilateral	90,99	6,26	87,66	94,32	82,08	105,13	0,064	
	Bilateral	93,04	6,65	89,50	96,59	81,14	107,17		
	Normal	97,13	8,80	92,44	101,82	84,32	114,53		

Table 7. Measurement Result of dentoalveolar angle together with p-value one-way anova and post hoc. *p<0,05, variables that are reaching significance.

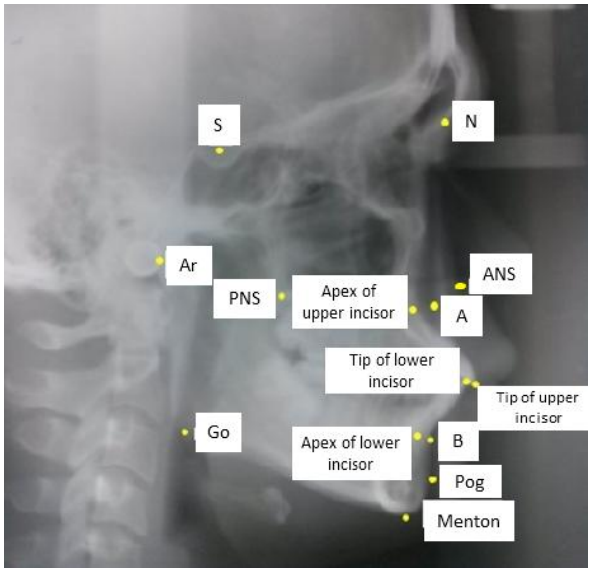

Figure 1. Anatomical landmarks of this study.

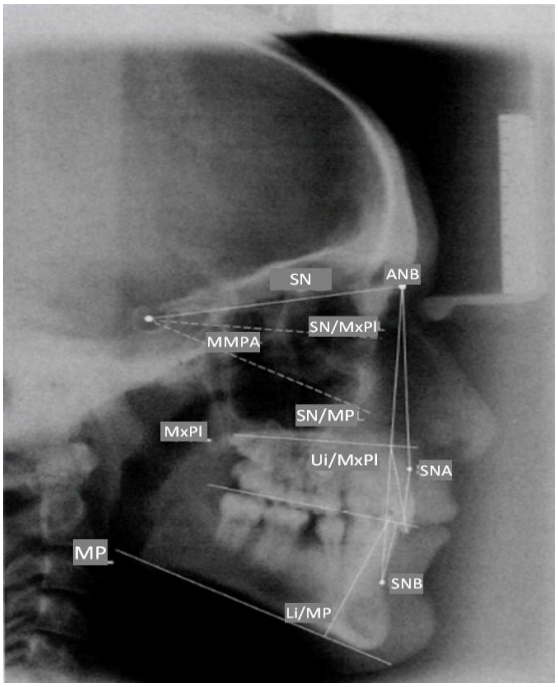

Figure 2. Planes and angles used in this study (Reproduced from Lisson et al, 2013)[18].

Discussion

Our results revealed that each group did not have equal proportion of subjects for CVMS I and II (each group had 3 CVMS I and 13 CVMS II subjects). According to Kusnoto (1988), and Ursi et al (1993), there were not any sexual dimorphism for the parameters examined in this study.[10,11]

Assuming that, so it is clear for us to compare all groups.

SNA unilateral group was found retrusive than normal and bilateral group, although not significant. The restriction of maxilla is caused by pressure of hypertonic lip muscles and alveolus scar.[5,12] Deficient maxilla in unilateral cleft lip and palate was caused by surgery treatment. It was confirmed by the finding of Shetye and Evans (2006) examining lateral cephalometrics of untreated unilateral cleft lip and palate patients found that there was normal growth of the maxilla. In other words, the scar resulted from surgeries are responsible for the restriction of maxilla.[13,14]

SNA for bilateral group was greater clinically than normal group and significantly than the unilateral. The large SNA is caused by the prominent premaxilla. Many studies showed that the initial prominence of maxilla is decreasing over time. Those studies recommended to keep the prominent premaxilla since it is decreasing until the end of skeletal maturation.[6,12,15-18].

Regarding SNB, it was found no significant differences among groups. Unilateral and bilateral had smaller value of SNB than normal group. Many studies report clockwise rotation of mandible in unilateral and bilateral cleft lip palate. It is also confirmed with the larger value of SN/MPindicating clockwise rotation in mandible of unilateral and bilateral cleft lip and palate patients.[15] The bilateral group had larger value of SN-MP significantly than normal group. According to Liao and Mars regarding mandible position, cleft lip and palate patients had nasal airway impairment which caused oral breathing. It is confirmed by the enlargement value of SN/MP and gonial angle, the same like this study, of unilateral cleft lip and palate patients who had only labioplasty and both of labioplasty and palatoplasty.[19] Other reason causing oral breathing is the lowest position of tongue in oral cavity was found in bilateral cleft lip and palate followed by unilateral cleft lip and palate according to McKee (1956).[20]

ANB was found the largest significant statistically for bilateral group. It is inferred that the sagittal relationship of bilateral cleft lip and palate tend to be protrusive at the skeletal maturation stage examined. Gnoinski (2009) stated that bilateral cleft lip and palate patients would have ANB angle larger than normal population in young children but gradually normalized without any theurapetical interference.[16]

The inclination of upper incisor showed significant differences among those groups with bilateral group had the smallest value of UI/MxPl angle. This retroclination is caused by the position of premaxilla as Ogidan and Subtelny stated. Before labioplasty, premaxilla of unilateral and bilateral cleft lip and palate patients are found protrusive. Following labioplasty, there would be molding reaction caused by labial muscles to premaxilla. This condition is worsened by scar tissue resulted from palatoplasty causing downward and backward rotation of the premaxilla.[15,94] Incisor retroclination of bilateral group was also worsened by its retrognathic skeletal pattern.[17]

Conclusions

The inclination of upper incisor was most affected by cleft lip and palate. The maxilla inclination was found a little retrusive for unilateral cleft lip and palate, while a little protrusive for bilateral. Sagittal relationship of bilateral was found the most protrusive followed by normal and unilateral group. Mandibular steepness was found for bilateral cleft lip and palate.

Acknowledgements

The authors are grateful to Mantra Nandini, Yulia Martini, Fitriyani and all the staff at the Cleft Center Dentistry Faculty, University of Padjadjaran for their kind help and support throughout this study. The publication of this manuscript is supported by the Directorate of Research and Community Engagement of the Universitas Indonesia.

Declaration of Interest

The authors report no conflict of interest.

References

1. Ladeira PR, Alonso N. Protocols in Cleft Lip and Palate Treatment : Systematic Review. Plast Surg Int 2012;2012:9.
2. El-Kassaby MA, Abdelrahman NI, Abbass IT. Premaxillary Characteristics in Complete Bilateral Cleft Lip and Palate: A Predictor for Treatment Outcome. Ann Maxillofacial Surg 2013;3(1):11-19.
3. Mitchell L. Cleft lip and palate and other craniofacial anomalies. An introduction to orthodontics. Oxford: Oxford University Press Inc.; 2007. p. 244-51.
4. Graber LW, Vanarsdall RL, Vig KWL. The orthodontist's role in a cleft palate - craniofacial team. In: Vig KWL, Mercado AM, editors. Orthodontics current principles and techniques, 5th edition. Philadelphia: Elsevier Mosby; 2012. p. 965-89.
5. Moreira I, Suri S, Ross B, et al. Soft-tissue profile growth in patients with repaired complete unilateral cleft lip and palate: a cephalometric comparison with normal controls at ages 7, 11, and 18 years. Am J Orthod Dentofacial Orthop 2014;145(3):341-58.
6. Semb G. A study of facial growth in patients with bilateral cleft lip and palate treated by the Oslo CLP team. Cleft Palate Craniofac J 1991;28(1):22-39.
7. Franchi L, Baccetti T, McNamara JA. Postpubertal assessment of treatment timing for maxillary expansion and protraction therapy followed by fixed appliances. Am J Orthod Dentofacial Orthop 2004;126:555-68.
8. Baccetti T, Franchi L, Cameron CG, Jr. JAM. Treatment timing for rapid maxillary expansion. Angle Orthod 2001;71(5):343-50.
9. Baccetti T, Franchi L, McNamara JA. An Improved Version of the Cervical Vertebral Maturation (CVM) Method for the Assessment of Mandibular Growth. Angle Orthod 2002;72(4):316-23.
10. Ursi WJS, Caroll-Ann T, Jr JAM, Behrents RG. Sexual dimorphism in normal craniofacial growth. Angle Orthod 1993;63(1):47-57.
11. Kusnoto H. Studi morfologi pertumbuhan kranio-fasial orang Indonesia kelompok etnik deutero melayu, umur 6-15 tahun di Jakarta, dengan metode sefalometri radiografi. Disertasi Universitas Padjadjaran 1988:18-20.
12. Caroll-Ann T, Ross RB. Craniofacial growth in bilateral cleft lip and palate: ages six years to adulthood. Cleft Palate Craniofac J 1993;30(3):261-73.
13. Shetye PR, Evans CA. Midfacial morphology in adult unoperated complete unilateral cleft lip and palate patients. Angle Orthod 2006;76(5):810-6.
14. Ozturk Y, Cura N. Examination of craniofacial morphology in children with unilateral cleft lip and palate. Cleft Palate Craniofac J 1996;33(1):32-6.
15. Q. AES, Ishii K, Arai T, et al. Long-term results of the two-stage palatoplasty/Hotz' plate approach for complete bilateral cleft lip, alveolus and palate patients. J Cranio-Maxillofac Surg 2003;31:215-27.
16. Gnoinski WM, Rutz G. A longitudinal cephalometric study from age 5 to 18 years on individuals with complete bilateral cleft lip and palate. J Cranifac Surg 2009;20:1672-82.
17. Holst AI, Holst S, Nkenke E, Fenner M, Hirschfelder U. Vertical and sagittal growth in patients with unilateral and bilateral cleft lip and palate - a retrospective cephalometric evaluation. Cleft Palate Craniofac J 2009;46(5):512-20.
18. Lisson JA, Heib N, Moeller Sv, Spitzer WJ, Ludwig B. Treatment results at 10, 15, and 18 years of age in patients with complete bilateral cleft lip and palate: an intercenter comparison. Cleft Palate Craniofac J 2013;50(1):19-24.
19. Liao YF, Mars M. Long-term effects of cleft on craniofacial morphology in patients with unilateral cleft lip and palate. Cleft Palate Craniofac J 2005;42:601-9.
20. McKee T. A cephalometric radiographic study of tongue position in individuals with cleft palate deformity. Angle Orthod 1956:99-109.