

EVALUATION OF MODIFIED EXTRAORAL TECHNIQUE IN ZYGOMATIC ARCH EXAMINATION

Aditya Dupare^{1*}, Apeksha Dhole (Balpande)², Mukta Motwani³, Anuraag Choudhary⁴

1. Post graduate student, Department of oral medicine and radiology, V.S.P.M. Dental college, Nagpur Maharashtra.
2. Professor, Department of oral medicine and radiology, V.S.P.M. Dental college, Nagpur Maharashtra.
3. Professor and Head Department of oral medicine and radiology, V.S.P.M. Dental college, Nagpur Maharashtra.
4. Reader, Department of oral medicine and radiology, V.S.P.M. Dental college, Nagpur Maharashtra.

Abstract

The zygomatic arch is the one of the commonest bone to get fractured in the face due to trauma, and the imaging of zygomatic arch is important in diagnosis and treatment of fractures. Occlusal and extraoral films require different exposure parameters, so the image characteristics of both the radiographs also varies. Thus we aimed to evaluate and compare the reliability of occlusal films in relation to extraoral films by modified extraoral technique in zygomatic arch examination. A total 50 subject will be randomly selected and divided equally into group A and B. Zygomatic arch in group A subjects was imaged on occlusal films while for group B subjects on extraoral films by modified extraoral technique. The image quality in two groups will be assessed by two observers and statistically analyzed using SPSS version 18.0 software. Statistically, the inter observer reliability of both the radiographs were found satisfactory and image quality was also acceptable. So this technique can be also used in dental office setup in patients having cervical injuries or suspected cervical injuries, thus overcoming the drawback of the jug handle view, and is easy to master.

Clinical article (J Int Dent Med Res 2016; 9: (1), pp. 13-17)

Keywords: Zygomatic arch, occlusal radiograph, extraoral radiograph.

Received date: 06 December 2015

Accept date: 21 January 2016

Introduction

Zygomatic arch is the one of the commonest and prominent bone of the face to fracture. Clinically, the fracture of the zygomatic arch causes a depression over the side of the face and esthetically compromised. It causes restriction of mouth opening due to interference with the movement of the coronoid process, which requiring immediate attention.^{1,2} The imaging of zygomatic arch helps in the diagnosis and treatment of its fractures. It is routinely accomplished by "jug handle radiography" which requires neck extended position. Till date it is a standard radiographic technique. There is no technique that can demonstrate suspected zygomatic arch fracture at dental setup with

patient suspected with cervical neck injury. Siddana SG et al³ performed the simplified zygomatic arch radiographic study on occlusal film to overcome the drawback of jug handle view and concluded that considerable good quality images of the zygomatic arch can be acquired by this approach as compared to the jug handle view, which can even be used in patients with cervical injuries or suspected cervical injuries, without any complications.

An ideal radiograph is one that provides a great deal of information, the image exhibit proper visual characteristic like contrast, and density; geometrical characteristics like sharpness, resolution, magnification; anatomical accuracy of radiographic images; adequate coverage of the anatomical coverage of the region of interest.⁴

Extra oral films require less exposure as compare to occlusal film. So we planned study to examine zygomatic arch on extra oral film and compare the quality of occlusal and extra oral films obtained by modified extra oral technique.

*Corresponding author:

Dr. Aditya Dupare,
Department of oral medicine and radiology,
V.S.P.M. Dental college, Nagpur Maharashtra.

E-mail: adupare@ymail.com

Material and method

Materials required are dental X-ray machine with dental chair, occlusal X-ray films, extraoral films, lead apron, film hanger, dark room equipment, cabinet drier. Exposure parameters were standardized at 70 kvp; 6 mA; except time for occlusal film is 0.55 seconds and for extraoral films is 0.35 seconds. The healthy individuals who were willing to participate in the study were included and the individual with a neuromuscular disorders, pregnant patients, patient with maxillofacial pathology or deformity and history of trauma to the maxillofacial region were excluded. The study was initiated after approval from institutional ethics committee. A total 50 subjects of age group between 20 - 50 years were randomly selected and divided into group A and group B. Group A and Group B subjects were exposed for zygomatic arch examination by modified extra oral technique on occlusal film and extra oral film radiography respectively.

Subject positioning: Standardization of subject positioning was done by allowing the subject to sit in the dental chair in an upright position with proper head support. The midsagittal plane was perpendicular and occlusal plane was parallel to the floor and Frankfort horizontal plane. Patient wear lead apron during exposure.

Film placement: The occlusal film is placed at the lower border of the mandible on the right side of the arch being radiographed with the medial side of the film approximately 1-cm medial to the lower border of the mandible and the lateral border of the film in line with the outer surface of the zygomatic arch. The anterior end of the film must be in line with the corner of the mouth. The film must be secured in the position with the subject right hand thumb. (Figure 1) The extraoral film is placed at the lower border of the mandible on the right side of the arch being radiographed. The film must be secured in the position with palm of the right hand palm. (Figure 2)

Positioning of x-ray source: For both the films, the central x-ray source is positioned in line with the lateral surface of the skull over the temporal bone so that the X-rays passes through

the zygomatic arch meeting the films at right angle.

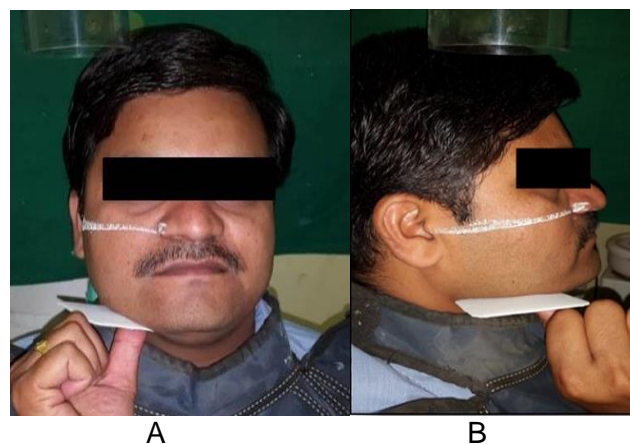


Figure 1. Subject positioning for Occlusal films radiography Facial view (A); Lateral view (B)

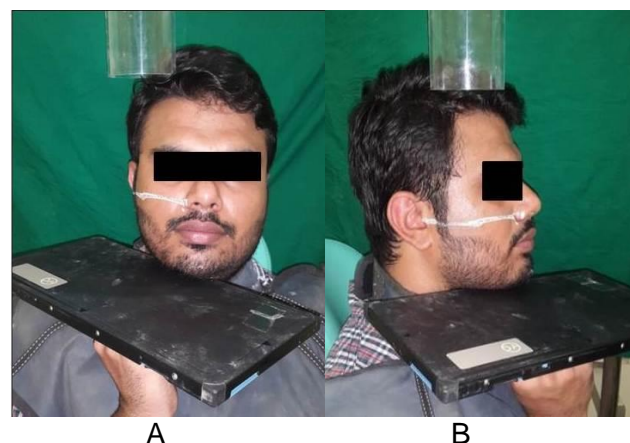

Figure 2. Subject positioning for Extra oral film radiograph Facial view (A); Lateral view (B)

Each radiograph was evaluated for image coverage (Complete and Partial) and image diagnostic quality (Excellent, Fair, Poor) by Principal investigator (Post graduate student) and Senior lecturer from the department of oral medicine and radiology. Accordingly the inter observer variability was evaluated and the image diagnostic quality was also compared.

Results

Inter observer agreement was evaluated using kappa statistical techniques. Subsequently, the image diagnostic quality in two groups was assessed using non-parametric statistical techniques and also the diagnostic potential of occlusal and extraoral radiograph by modified extraoral technique. The analysis was performed

using SPSS version 18.0 software. The level of significance was determined by probability value (p value). *P*-value <0.05 was taken as significant.

Table 1 shows the agreement between observers on image coverage and quality of occlusal and extraoral radiographs. The degree of agreement was quantified using Kappa coefficient.

Parameter	Image coverage			Image quality		
	Occlusal	Extraoral	Both	Occlusal	Extraoral	Both
Kappa coefficient	1.000	0.918	0.956	0.829	0.762	0.815
95% Confidence Interval	-	(0.761, 1.000)	(0.871 - 1.000)	(0.613 - 1.000)	(0.516 - 1.000)	(0.664 - 0.966)
Agreement strength	Perfect	Very good	Very good	Very good	Good	Very good

Table 1. Agreement between observers on image coverage and quality on two radiographs using Kappa statistics

Table 2 shows on occlusal radiographs, there was perfect agreement between two observers as regards image coverage, while on extraoral radiographs, the agreement was 0.918 (95% CI: 0.716 – 1.000), which also was very good. As regards image quality, on occlusal radiographs, the agreement between the observers was maximum as indicated by Kappa coefficient of 0.829 (95% CI: 0.613 – 1.000).

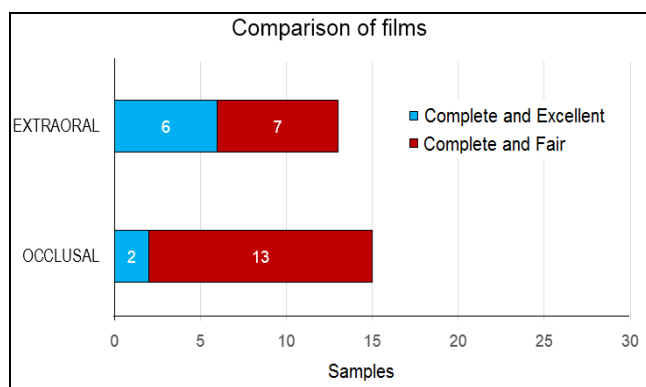


Table 2. Comparison of films for images coverage and image quality

After comparing of both the films, out of 25 samples examined using extraoral film, 6 (24%) showed complete image coverage and excellent image characteristics, and there was perfect agreement between the observers. There were 7 (28%) samples that showed complete coverage and fair characteristics, with perfect agreement between the observers. Out of 25 samples examined using occlusal film, only 2 (8%) showed complete image coverage and

excellent characteristics, and both the observers had perfect agreement. There were 13 (52%) samples that showed complete coverage and fair characteristics, as agreed by both the observers. Although the proportion of samples with complete coverage and excellent characteristics in extraoral film was higher than that of occlusal film, the difference was statistically insignificant with *p*-value of 0.2472 (*p* > 0.05) using z-test for proportion (Table 2). The proportion of samples with complete coverage and fair characteristics in occlusal films was higher than that of extraoral films, however, the difference was statistically insignificant with *p*-value of 0.1489 (*p* > 0.05).

Discussion

The zygomatic arch is part of the facial subunit known as the zygomaticomaxillary complex (ZMC) and functional and aesthetic unit of the facial skeleton. The imaging of zygomatic arch is conventionally done by the jug handle radiograph, a modification of the submentovertebral (SMV) radiograph. This technique requires the patient to extend his/her neck, so that the vertex of the skull touches the extra oral cassette. This position induces stress in the neck, and also contraindicated in a patient with cervical neck injury or suspected cervical injury. In such situations, the existing choice of imaging is computed tomographic (CT) scan. Advising a CT scan for imaging screening of small bone is not feasible. It has high radiation dose, high cost and availability of the facility, is also questionable. Singh KS et al; conducted comparative study on diagnostic utility of ultrasonography (USG) with conventional radiography (CT) and computed tomography scan in detection of zygomatic arch and mandibular fracture and concluded that USG is a very reliable tool in detection of fractures involving zygomatic arch and mandible. It can be used for screening of suspected fractures of zygomatic arch and mandible to avoid unnecessary radiation exposure from conventional radiography and CT scans.⁵ Recently, Anand D et al, conducted a preliminary study on preoperative ultrasonographic evaluation of six patients with zygomatic arch fracture, their study revealed that a sensitivity and specificity of real time imaging is 100%.⁶

Though, Sensitivity and specificity of USG in assessing zygomatic arch fractures were 100%. Factors affecting the validity of diagnostic

USG in maxillofacial fractures. These include the experience of the sonographer and the type and resolution of the transducer. The use of regular linear probes leads to problems with poor adaptation to facial topography; some investigators overcome this by using curvilinear and small size probes. Specially designed transducers suited to maxillofacial topography are desirable,⁷ and most importantly zygomatic arch screening by USG routinely is not performed in dental setups.

In the jug handle radiography, by reducing the kVp, the quality of the beam is reduced, allowing the x-rays to get absorbed within the face and the skull. Though some modifications like collimating the beam to the arch of interest are indicated to reduce the patient exposure, but the positioning of the patient remains the same. In this modified approach, the patient need not extend the neck making it possible to make the radiograph of the zygomatic arch even in cases with neck injuries, which otherwise would have been contraindication for making a jug handle view radiography.

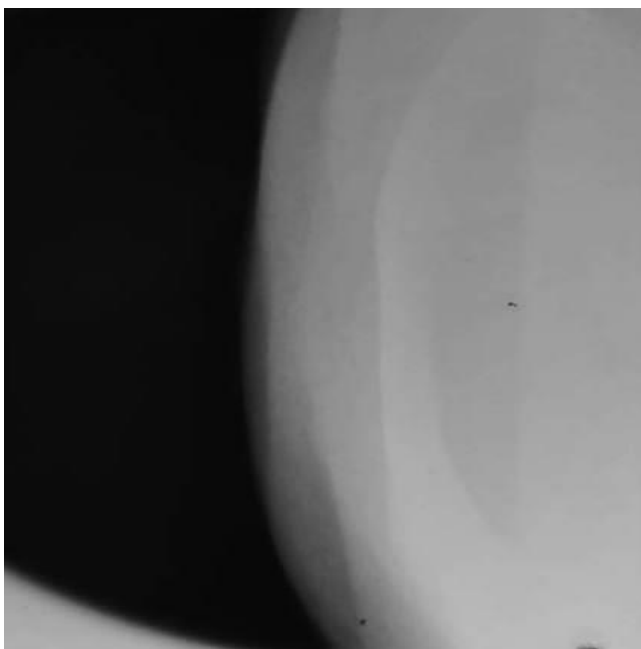


Figure 3. Zygomatic arch radiograph on occlusal film

In this suggested approach, we require conventional dental x-ray machine, occlusal film or extra oral film with cassette. Hence, this technique is very useful in a conventional dental setup to rule out or screening of zygomatic arch fractures. The advantage of using this modified

approach using dental X-ray machine is that it reduces radiation dose by using 6 mA compared to the 50 mA of a general X-ray machine and it improves the quality of the x-ray beam by operating at 70 kVp as compared to 30-40 kVp used in the jug handle radiograph, thus producing considerable good quality images of the zygomatic arch on occlusal and extraoral films. (Figure 3 and Figure 4)

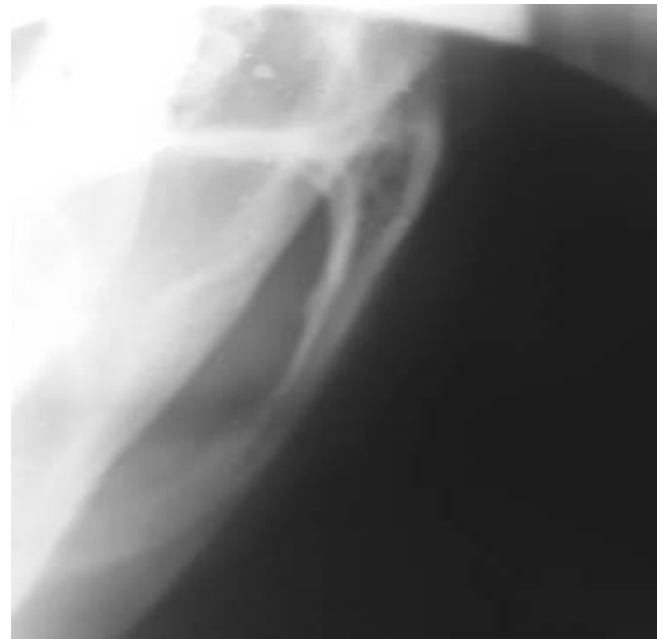

Figure 4. Zygomatic arch radiograph on extraoral film

Conclusion

By reducing the quantity and increasing the quality of the x-ray beam, the dose accumulation within the patient is considerably reduced thus satisfying ALARA principle. Also this modified technique both occlusal and extraoral cassette are feasible, readily available and it is less technique sensitive. Thus, considerable diagnostic quality images of the zygomatic arch can be acquired by this modified approach with both the films, so that we can use it for screening of zygomatic arch which can even be used in patients with cervical injuries or suspected cervical injuries.

Declaration of Interest

The authors report no conflict of interest and the article is not funded or supported by any research grant.

References

1. Fonseca RJ, Marciani RD, Turvey TA. Management of zygomatic fractures. Oral and Maxillofacial Surgery. 2nd ed. Vol. 2. St. Louis, MO: Elsevier; 2009. p. 182-3.
2. Chaurasia BD, Garg K. Osteology of head and neck. In: Chaurasia BD, Garg K, editors. BD Chaurasia's Human Anatomy: Regional and Applied Dissection and Clinical. Head, Neck and Brain. 4th ed. Vol. 3. New Delhi: CBS Publishers and Distributors; 2004. p. 3-44.
3. Siddana SG, Muniraju M. Simplified zygomatic arch radiographic technique to overcome the drawback of jug handle view. J Indian Acad Oral Med Radiol 2014;26:390-2.
4. Karjordkar FR, Essential of oral & maxillofacial radiology: 1st ed. Jaypee Brothers 2014. p. 47-54.
5. Singh KS, Jayachandran S. A comparative study on the diagnostic utility of ultrasonography with conventional radiography and computed tomography scan in detection of zygomatic arch and mandibular fractures. Contemp Clin Dent 2014;5:166-9.
6. Anand D, Kavita P, Vineeth K, Akash RR, Sudha SP. The Use of Ultrasonography in Zygomatic Arch Fractures A Preliminary Study. RJPBCS 2015;6(4):653-7.
7. Adeyemo WL, Akadiri OA. A systematic review of the diagnostic role of ultrasonography in maxillofacial fractures. Int J Oral Maxillofac Surg 2011;40:655-61.