Efficacy of Hyperbaric Oxygen Therapy as an Adjunctive Therapy of Chronic Periodontitis

Ganesha Wandawa[1,2], Dewi Nurul Mustaqimah[1], Suyanto Sidik[3], Henny Saraswati[4], Frisky Amanda Putri[5], Elza Ibrahim Auerkari[5]*

1. Department of Periodontology, Faculty of Dentistry, University of Indonesia.
2. Medical Department, Western Fleet Command, Indonesian Navy.
3. Department of Internal Medicine, Dr. Mintohardjo Hospital, Indonesian Navy.
4. Institute of Human Virology and Cancer Biology, University of Indonesia.
5. Department of Oral Biology, Faculty of Dentistry, University of Indonesia.

Abstract

Hyperbaric oxygen therapy (HBOT) is based on breathing pure oxygen in a chamber at a higher than atmospheric pressure. The use of HBOT is not uncommon in the medical practice, but not widely known or applied in dentistry. In this work HBOT has been considered as a potential treatment of chronic periodontitis.

The study aimed to evaluate the efficacy of HBOT as an adjunctive therapy for patients suffering chronic periodontitis, after applying the conventional therapy of scaling and root planing (SRP). Also, the study aimed to investigate the required number of HBOT sessions for treatment.

Fifty four patients aged 30-50 years with chronic periodontitis and 4-6 mm of pocket depth were divided into three treatment groups: SRP treatment only, SRP with 8 sessions of HBOT, and SRP with 16 sessions of HBOT. As clinical data, pocket depth, clinical attachment level and bleeding on probing were monitored for a period of up to one month.

A multivariate analysis of the clinical data indicated that a combination of conventional treatment (SRP) with 8 HBOT sessions provided significantly better results than conventional treatment alone. Further improvement by 16 HBOT sessions after SRP was slight and the difference was not statistically significant.

The results showed that HBOT can be beneficial as an adjunctive therapy of chronic periodontitis when combined with SRP, and that 8 sessions of HBOT is sufficient for the purpose.

Clinical article (J Int Dent Med Res 2017; 10: (1), pp. 72-75)

Keywords: Hyperbaric oxygen therapy (HBOT); chronic periodontitis; scaling and root planing (SRP); adjunctive therapy.

Received date: 28 September 2016 **Accept date:** 29 October 2016

Introduction

Hyperbaric oxygen therapy (HBOT) is a physical treatment of breathing pure oxygen in a chamber at a higher that atmospheric pressure.[1-5] The use of HBOT is widely accepted and applied in medical practice, but remains less common in dentistry.

HBOT basically applies oxygen as a therapeutic drug that is administered at controlled dosage and pressure. HBOT has been indicated as the main or auxiliary treatment for several acute and chronic diseases of ischemic, infectious, traumatic or inflammatory nature, when these are severe and do not respond to conventional treatment. In particular, HBOT may be indicated in cases of anaerobic infections that are not responding to other antimicrobial therapy.[6] Oxygen therapy has been found beneficial for healing of wounded tissue and infected wounds.[7] Also, increase in trabecular volume and decrease in trabecular separation has been shown by the osteoblast activity after HBOT.

Use of HBOT in dentistry has not been widely studied, and this is also true in the treatment of periodontal disease like chronic periodontitis. In principle oxygenation can prevent the growth of the anaerobic Gram negative microbes that are typically involved in chronic periodontitis, but although antimicrobial

Corresponding author:
Elza Ibrahim Auerkari
Department of Oral Biology, Faculty of Dentistry, Universitas of Indonesia
Salemba Raya No. 4, Jakarta 10430, Indonesia
E-mail: eauerkari@yahoo.com

benefits of HBOT in treating severe periodontitis has been reported, lasting from months to a year, optimal doses or sufficient number of HBOT sessions are not well defined.[8-12]

The primary objective of the study was to evaluate the effects of HBOT as an adjunctive therapy after the conventional therapy of scaling and root planing in comparison with conventional therapy alone in patients suffering chronic periodontitis. A secondary objective was to clarify the required number of HBOT sessions for sufficient impact against the disease.

Materials and methods

The study was conducted from January to March in 2010 at the Medical Department of the Western Fleet Command of Indonesian Navy, as an experimental clinical study of randomized controlled trial design.

The subjects of the study were consenting and volunteering patients participating to the end of the investigation. The following inclusion criteria were applied: non-smoking adults at 30-50 years of age, with localized or generalized chronic periodontitis and a probing depth (PD) of 4-6 mm; otherwise generally healthy with no systemic disease; no antibiotic medication for the last 3 months and no periodontal treatment within the last 6 months.

The 54 subjects were randomly divided into three groups: control group receiving conventional treatment of scaling and root planing (SRP) only (K0); treatment group receiving SRP and 8 sessions of HBOT (K8); and treatment group receiving SRP and 16 sessions of HBOT (K16). Initial and follow-up clinical observations were included on probing depth (PD, in mm), clinical attachment level (CAL, in mm) and bleeding on probing (BOP, yes/no).

Observations were made from the site of the deepest pocket, from posterior teeth (first or second molar) and anterior teeth (central incisor, lateral incisor, or canine) in upper and lower jaw, with 4-6 mm pocket depth in a localized or generalized chronic periodontitis. All evaluations of the groups K0, K8 and K16 were performed before treatment (observation PI) and 15 and 30 days (observations PII and PIII) after treatment.

Local anaesthesia was applied to the area to be treated. SRP procedure was performed using ultrasonic scaler and hand instruments i.e. Hu-Friedy Gracey curettes 1-2 and 3-4 for the front teeth, 11-12 and 13-14 for posterior teeth. SRP was followed by irrigation with 0.2% chlorhexidine solution to the gingival crevices. For all study subjects antibiotics was administered as 15 capsules of clindamycin (300 mg as 3x daily dose), to be taken until finished.

HBOT was provided at a pressure of 2.5 ata for 3x30 min, with two intermediate pauses to allow breathing of normal air for 5 minutes after the first and second 30 min treatments. For the treatment group K8, such a treatment was delivered in 5 consecutive days, 2-day break, and with another 3 consecutive delivery days. For group K16, the above treatment procedure was doubled with a 2-day intermediate break. Subjects that that could not follow the procedure for more than three consecutive days were excluded, and otherwise it was required that the subjects of groups K8 and K16 had to finish the entire HBOT procedure in 15 and 30 days, respectively.

Before execution the study was approved by the ethics commission of dentistry research at the Faculty of Dentistry, University of Indonesia. For statistical analysis and data management, the SPSS software was used.

Results

The results of the clinical data (PD, CAL and BOP) from 107 samples of 54 subjects are presented in Table 1.

	K0			K8			K16		
	PI	PII	PIII	PI	PII	PIII	PI	PII	PIII
PD									
n	36	36	36	38	38	38	33	33	33
Mean	4.78	3.56	3.44	4.68	2.63	2.53	4.97	2.64	2.33
SD	0.76	0.94	0.97	0.70	0.63	0.56	0.81	0.65	0.65
CAL									
n	36	36	36	38	38	38	33	33	33
Mean	4.92	4.08	3.92	4.97	2.97	2.87	5.36	3.33	3.09
SD	0.91	0.97	0.97	0.75	0.75	0.62	1.06	0.99	0.98
BOP									
n	36	13	9	38	3	2	33	1	1
%	100.0	36.10	25.00	100.0	7.90	5.30	100.00	3.00	3.00

Table 1. PD, CAL and BOP results in the treatment groups at initial (PI) and follow-up (PII, PIII) observations.

Notes :
PI : initial observation
PII : observation 15 days after treatment
PIII : observation 30 days after treatment
n : number of samples; SD : standard deviation

The mean probing depth (PD), mean clinical attachment level (CAL) and percentage of subjects with bleeding on probing (BOP) showed

in all treatment groups a clear decrease from the initial (PI) to second observation (PII, 15 days after treatment) but much less if any change from second to third observation (PIII, 30 days after treatment).

The extent of decrease in PD, CAL and BOP was clearly smaller in the conventional treatment group (K0) than in the treatment groups K8 and K16, but the difference between the K8 and K16 treatment groups was relatively small (Figs 1 and 2).

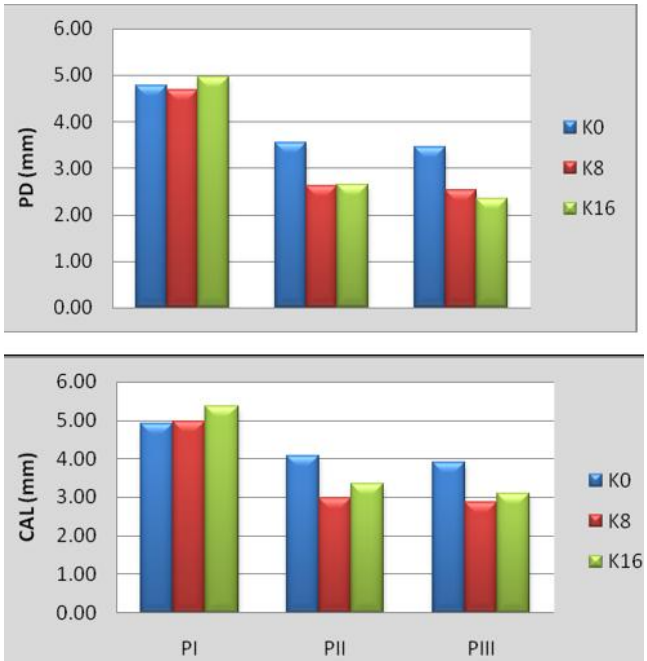

Figure 1. Mean PD and CAL values for the treatment groups at times of observation.

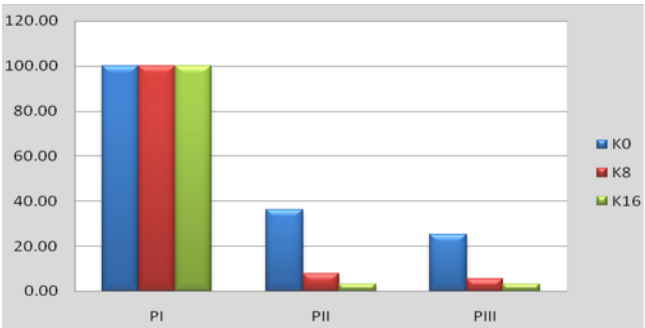

Figure 2. Percentage of subjects showing BOP in the three treatment groups at times of observation.

Discussion

The additional hyperbaric oxygen treatment after SRP was shown to significantly decrease the mean values of PD and CAL, and the percentage of subjects with BOP. As these are important clinical indicators of the extent of chronic periodontitis, the results of the present study therefore suggest that HBOT is an effective adjuvant therapy after a conventional therapy against chronic periodontitis. This is presumably because HBOT can provide an oxygenation knockout to the anaerobic Gram negative microbes that are intimately involved in the disease. The results are in agreement with the results of earlier work suggesting a significant reduction in the mean PD in the subjects treated with combined scaling and HBOT.[7] The results are also in general agreement with earlier work showing that combined SRP and HBOT can substantially reduce (by up to 99.9%) the number of Gram negative anaerobic microorganisms within the gingival microflora.[8-12] The HBOT approach is also potentiallty effective is other comparable medical and dental applications, such as protecting and healing in cases of inflammation hazard after surgery, irradiation or necrotizing infection; generally the treatment is also combined with antibiotic application.[13-15]

The accuracy and reproducibility of PD and CAL measurements are important since the case definition for periodontitis is largely based on these measurements, and a relatively small change may elicit a significant difference in the apparent prevalence of the disease. In the present study a significant reduction was found in the mean PD and CAL values from the initial to the two post-treatment observations. In contrast, the differences between the second (15 days) and third (30 days) observations were small and not significant, implying that the beneficial impact of HBOT prevails for at least over this time period. On the other hand, the more extensive K16 treatment showed only a little if any improvement in comparison with the shorter K8 treatment, and hence K8 appears sufficient for its purpose.

Gingival bleeding is a sign of inflammation, and bleeding on probing (BOP) is an important indicator of periodontitis. In this study all subjects showed BOP before treatment, and the percentage of subjects with BOP in all treatment groups significantly decreased after treatment. However, the decrease was significantly more pronounced with an additional HBOT (K8 or K16). Again, the differences between the observations at 15 days and 30 days after treatment, and between treatment groups K8 and K16 were small and not

significant, although some additional improvement was observed from K8 to K16.

In general, there was no significant difference between the treatments K8 and K16, nor was there significant difference in the mean periodontal status at 15 days and 30 days after treatment. Therefore it is concluded that 8 sessions of HBOT was an effective adjunctive measure against chronic periodontitis beyond the impact of the conventional treatment. This may justify using 8 sessions of HBOT as an adjunctive therapy against chronic periodontitis after conventional SRP treatment.

Conclusions

An additional hyperbaric oxygen treatment (HBOT) on patients with chronic periodontitis after scaling and root planing (SRP) was shown to signifantly decrease the mean values of pocket depth and clinical attachment length, and the percentage of subjects bleeding on probing. A treatment of 8 HBOT sessions, 3 times 30 min each, appears sufficient, and doubling the number of sessions made little difference to the results. On the tested timescale up to one month, such HBOT after SRP is an effective adjunctive treatment to chronic periodontitis.

Acknowledgements

The authors wish to gratefully acknowledge the financial support from the Indonesian Ministry of Education through the University of Indonesia.

Declaration of Interest

The authors report no conflict of interest.

References

1. Guo S, DiPietro LA. Factors affecting wound healing. J Dental Res. 2010; 89: 219-29.
2. Löndahl M, Katzman P, Nilsson A, Hammarlund C. Hyperbaric Oxygen Therapy Falicitates Healing of Chronic Foot Ulcers in Patients with Diabetes. Diabetes Care. 2010; 33(5): 998-1003.
3. Devaraj D, Srisakthi D. Hyperbaric oxygen therapy - can it be the new era in dentistry? J Clin Diagnostic Res. 2014; 8: 263-5.
4. Peters BM, Jabra-Rizk MA, O'May GA, Costerton JW, Shirtliff ME. Polymicrobial interactions: impact on pathogenesis and human disease. Clin Microbiol Rev. 2012; 25: 193-212.
5. Sarria JC, Norbert J, Roberts Jr. Hyperbaric Oxygen: Mandell, Douglas, and Bennett's Principles and Practice of Infectious Diseases. 8th ed. 2015
6. Mitchell SJ, Bennett MH. Unestablished Indications for hyperbaric Oxygen Therapy. Diving and Hyperbaric Medicine. 2014; 44(4): 228-234.
7. Hunt TK, Aslam RS. Hyperbaric Oxygen Therapy for Chronic Wounds. Cochrane Database of Systematic Reviews. 2012.
8. Nogueira-Filho, Getulio R, Rosa, Bruno T, David-Neto, Joao R. Biological effects of hyperbaric oxygen on human severe periodontitis. Undersea & Hyperbaric Medicine. 2010; 37(2): 107-14.
9. Vatansever F, de Melo WCMA, Avci P, Vecchio D, Sadasivam M, Gupta A, Chandran R, Karimi M, Parizotto NA, Yin R, Tegos GP, Hamblin MR. Antimicrobial strategies centered around reactive oxygen species - bactericidal antibiotics, photodynamic therapy, and beyond. FEMS Microbiol Rev. 2013; 37: 955-89.
10. Almzaiel AJ, Billington R, Smerdon G, Moody AJ. Effects of hyperbaric oxygen treatment on antimicrobial function and apoptosis of differentiated HL-60 (neutrophil-like) cells. Life Science. 2013; 93: 2-3.
11. Yan L, Liang T, Cheng O. Hyperbaric oxygen therapy in China. Med Gas Res. 2015; 5: 3.
12. Slots J. Low-cost periodontal therapy. Periodontology. 2012; 60: 110-37.
13. Oliveira PAD, Oliveira AMSD, Pablos AB, Costa FO, Silva GAB, dos Santos JN, Cury PR. Influence of hyperbaric oxygen therapy on peri-implant bone healing in rats with alloxan-induced diabetes. J Clin Periodontol. 2012; 39: 879-86.
14. Inchingolo F, Marrelli M, Annibali S, Cristalli MP, Dipalma G, Inchingolo AD, Palladino A, Inchingolo AM, Gargari M, Tatullo M. Influence of endodontic treatment on systemic oxidative stress. Int J Med Sci. 2014; 11: 1-6.
15. Kumar AJ, Anumala N, Avula H. Novel and often bizarre strategies in the treatment of periodontal disease. J Indian Soc Periodontol. 2012; 16: 4-10.