Pattern of Impacted Third Molars in Thai Population: Retrospective Radiographic Survey

*Ruchadaporn Kaomongkolgit[1], Weeraya Tantanapornkul[2]**

1. Associated Professor, Department of Oral Diagnosis, Faculty of Dentistry, Naresuan University, Phitsanulok, Thailand.
2. Assistant Professor, Department of Oral Diagnosis, Faculty of Dentistry, Naresuan University, Phitsanulok, Thailand.

Abstract

The purposes of the present study were to retrospectively assess the pattern of impacted third molars, their proximity to important structures, and the other developmental abnormalities in Thai population.

This retrospective study was performed by evaluation of digital panoramic radiographs in 1,427 patients. The patterns of impacted maxillary and mandibular third molars, developmental abnormalities were evaluated. Appropriate descriptive statistics including mean, standard deviation, and frequency were computed. Statistical significance is defined as $p< 0.05$.

Among1,427 patients, 469 (32.87%) were males and 958 (67.13%) were females. Patients' age ranged from 16-57 years (mean, 21.09 years. The number of impacted third molars was 4,834 of which 2,343 (48.47%) were maxillary and 2,491 (51.53%) were mandibular. Vertical angulation and position B were most found in maxilla. Mesioangulation, class II and position B were most found in mandible. Microdontia was most common developmental abnormalities (9.46%), followed by missing tooth (6.45%) and supernumerary tooth (6.45%), respectively.

The patterns of impacted third molars in a group of Thai population are not entirely different from that of other nationalities. The further studies including advanced imaging techniques and postsurgical recordings are needed to confirm conventional radiographic findings.

Clinical article (J Int Dent Med Res 2017; 10: (1), pp. 30-35)

Keywords: Third molar, Impaction, Thai, Panoramic.

Received date: 29 December 2016 **Accept date:** 17 January 2017

Introduction

Tooth impaction is a situation in which a tooth cannot or will not erupt into its normal functioning position.[1] Third molar is the most frequently impacted tooth, with a frequency of occurrence generally reported to be from 16.7 to 73.82 %.[2-5] Impacted third molar is a common problem affecting a large proportion of population. It is often associated with pericoronitis, periodontitis, cystic lesions, neoplasm, root resorption and can cause detrimental effects on adjacent tooth. Many reports have shown that impacted third molar weakens the angle of mandible and condyle, and makes it susceptible to fracture.[6,7] It is also implicated in the etiology of lower arch crowding, temporomandibular joint disorders, vague orofacial pain and neuralgias.[8,9]

Corresponding author:
Assistant Professor WeerayaTantanapornkul
Department of Oral Diagnosis, Faculty of Dentistry,
Naresuan University, Phitsanulok, 65000 Thailand.
E-mail: weerayatan@yahoo.com

To our knowledge, there is a few reports about the situation of impacted third molars in Thai population.[4,5] The purpose of the present study is to retrospectively assess the pattern of impacted third molars, their proximity to important structures, and the other developmental abnormalities in Thai population. We hypothesize that Thai population have a different pattern of impacted third molars from that of population through the world.Numerous studies have reported no sexual predilection in third molar impaction.[4,6-8] However, there also some studies have reported a higher frequency in females than males.[3,9-11]

Third molar impaction is a common problem affecting a large proportion of population through the world.[9] It is often associated with pericoronitis, periodontitis, cystic lesions, neoplasm, root resorption and can cause detrimental effects on adjacent tooth[12]. Removal of an impacted third molar is one of the most

frequently performed in young adults. Many reports have shown that impacted third molar weakens the angle of mandible and condyle, and makes it susceptible to fracture.[6,7] It is also implicated in the etiology of lower arch crowding, temporomandibular joint disorders, vague orofacial pain and neuralgias.[8,9,15,16] Impacted maxillary third molar is also the cause of upper arch crowding, pericoronitis, periodontitis, and affect the adjacent tooth.[9] The depth of impaction of the maxillary wisdom tooth is a possible predictor of the possibility of oro-antral perforation if removal of the tooth is required.[17] Several methods have been used to classify the impaction. This classification is based on many factors which are the level of impaction[15], the angulations of the third molars and the relationship to the anterior border of the ramus of the mandible. Depth or level of maxillary and mandibular third molars can be classified using Pell and Gregory classification system, where the impacted teeth are assessed according to their relationship to the occlusal surface of the adjacent second molar.[9]

It is generally accepted that patterns of facial growth and jaw and tooth size are inherited and are likely to differ among populations and races. To our knowledge, there is a few reports about the situation of impacted third molars in Thai population.[4, 5] We hypothesize that Thai population have a different pattern of impacted third molars from that of population through the world. The purposes of the present study were to retrospectively assess the pattern of impacted third molars, their proximity to important structures, and the other developmental abnormalities in Thai population.

Materials and methods

The present study was conducted in accordance with the Declaration of Helsinki (http://www.wma.net) and that all procedures were carried out with the adequate understanding and written consent of the subjects. The formal approval to perform this study has been obtained from our institution's human subjects review board.

Patients

In this retrospective study patients were chosen from Thai outpatients who visited Dental Hospital, Faculty of Dentistry, Naresuan University and underwent panoramic radiograph examination in August 2013 to January 2015.

All Panoramic radiographs were digitally generated on a Kodak 9000c Digital Panoramic and Cephalometric System (Carestream Health Inc., Rochester, NY, USA). The inclusion criteria are the availability in their clinical records of a panoramic radiograph of adequate quality, and no history of medical or surgical disease that could affect the presence and development of third molars. Exclusion criteria included image deformity affecting third molar visualization or panoramic radiograph showing obvious dental pathology related to the third molars.

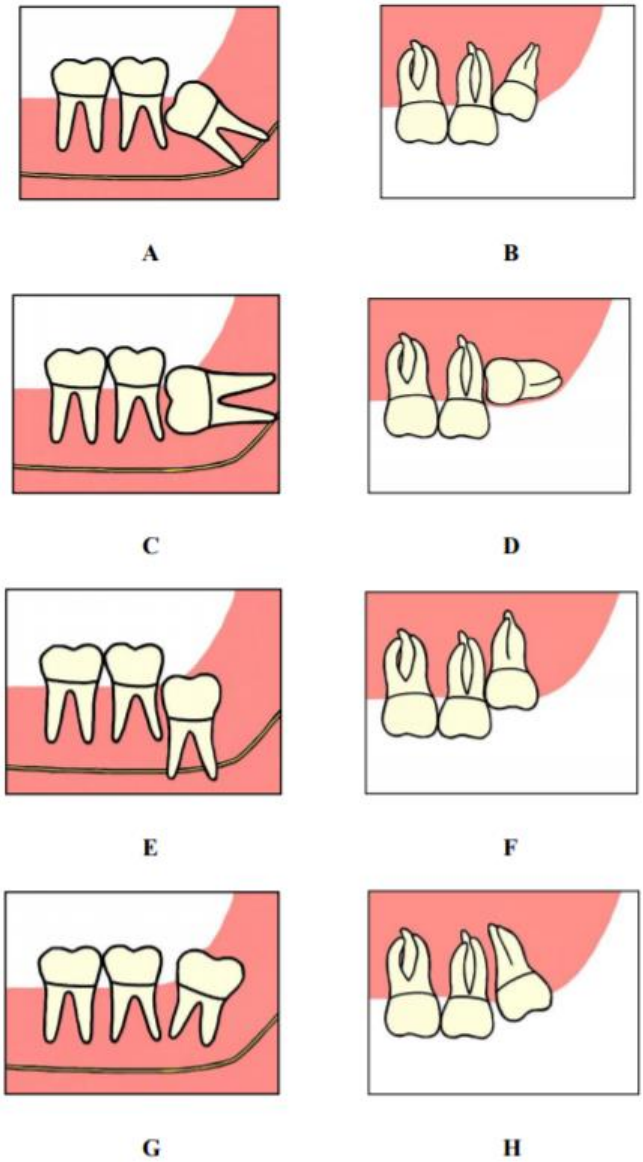

Figure 1. Schematic drawing of the Winter's classification to classify impacted mandibular and maxillary third molars (A, B: mesioangular impaction, C, D: horizontal impaction, E,F: vertical impaction, G, H: distoangular impaction).

Evaluation of impacted third molars

Panoramic radiographs were used to assess the presence, position and angulation of impacted third molars. Winter's classification was used to classify maxillary and mandibular third molars into mesioangular, horizontal, vertical and distoangular(Figure 1).[18]

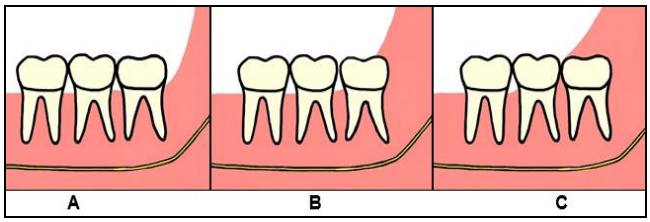

Figure 2. The relationship of mandibular third molar to the ramus of mandible according to the classification of Pell and Gregory (A: class I, B: class II, C: class III).

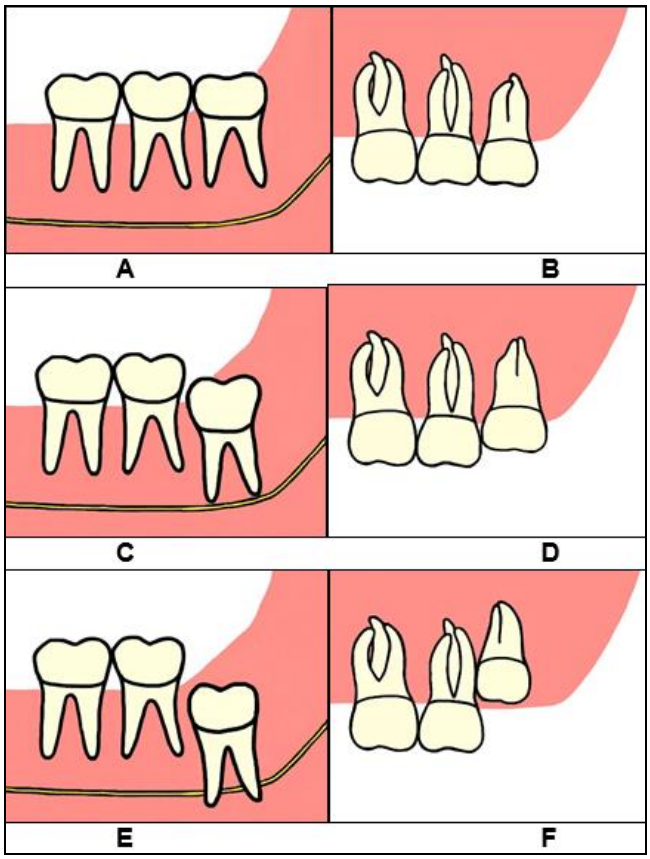

Figure 3. The relative depth of mandibular and maxillary third molars according to the classification of Archer (A, B: position A, C, D: position B, E, F: position C).

The relationship of mandibular third molar to the ramus of mandible was grouped according to the classification of Pell and Gregory[19] namely, class I: sufficient spaceis present between the ramus and the second molar to accommodate the crown of third molar, class II: space is insufficient, and class III: the third molar is located all or mostly within the vertical ramus (Figure 2).

The relative depth of maxillary and mandibular third molars were grouped according to the classification of Archer.[20] At position A, the highest point of the third molar is on the same level as, or below the occlusal plane of the adjacent second molar. At position B, the highest point of third molar is below the occlusal plane but above the cervical line of the second molar. At position C, the highest point of third molar is below the cervical line of the second molar, as shown in Figure 3. In addition, their proximity to important structures, such as maxillary sinus and inferior alveolar nerve were also evaluated.

All of the digital radiographs are viewed on the 21 inches LCD monitor, with resolution of 1600x1200 pixels (Dell LCD monitor, Dell Optiplex 990, Dell Inc., Penang, Malaysia). The assessment is performed by one oral and maxillofacial radiologist. With an interval of two months, 100 randomly chosen panoramic radiographs are graded and re-scored for testing intra- observer agreement.

Statistical analysis

Appropriate descriptive statistics including mean, standard deviation, and frequency were computed. Cohen's kappa test is performed to calculate the intra- and inter- observer agreement. All the data are analyzed using the SPSS software package (SPSS for Windows, version 17.0, Chicago, IL, USA). Statistical significance is defined as $p < 0.05$.

Results

The present study composed of 1,427 patients which 469 (32.87%) were males and 958 (67.13%) were females. Patients' age ranged from 16-57 years (mean, 21.09 years, standard deviation, 5.54).The number of impacted third molars was 4,834 of which 2,343 (48.47%) were maxillary and 2,491 (51.53%) were mandibular. Distribution of patients by number of impacted teeth and distribution of each impacted third molar were shown in Tables 1 and 2, respectively.

No. of impacted teeth	Male	Female	Total	%
1	97	145	242	16.96
2	242	329	571	40.01
3	90	157	247	17.31
4	40	327	367	25.72
Total	469	958	1,427	(100)

Table 1: Distribution of patients by number of impacted teeth.

	18	28	38	48	Total
Male	344	341	457	478	1,620
Female	653	651	963	947	3,214
Total	997	992	1,420	1,425	4,834

Table 2: Distribution of impacted third molars.

Angulation	Male No. of teeth	Female No. of teeth	Total (%)
Maxillary			
Horizontal	6	12	18 (0.77)
Mesioangular	356	413	769 (32.82)
Distoangular	147	234	381 (16.26)
Vertical	550	601	1,151 (49.13)
Buccolingual	16	8	24 (1.02)
Total	1,075	1,268	2,343 (100)
Mandibular			
Horizontal	270	407	677 (27.18)
Mesioangular	201	679	880 (35.33)
Distoangular	98	153	251 (10.07)
Vertical	237	440	677 (27.18)
Buccolingual	2	4	6 (0.24)
Total	808	1,683	2,491 (100)

Table 3: Distribution of angulation of impacted maxillary and mandibular third molars.

Most of the patients had 2 impacted tooth (571 cases, 40.01%). Impacted teeth were found more in mandible (2,845 teeth, 58.85%). There was no significant difference between left and right impacted third molars both in maxilla and mandible. Vertical angulation was most found in maxilla (1,151 teeth, 49.13%) whereas mesioangulation was most found in mandible (880 teeth, 35.33%), as shown in Tables 3 and 4.

Position	Male No. of teeth	Female No. of teeth	Total (%)
Maxillary			
A	248	263	511 (21.81)
B	532	548	1,080 (46.1)
C	295	457	752 (32.09)
Total	1,075	1,268	2,343 (100)
Mandibular			
A	168	388	556 (22.32)
B	423	699	1,122 (45.04)
C	217	596	813 (32.64)
Total	808	1,683	2,491 (100)

Table 4: Position (level) of impacted maxillary and mandibular third molars.

	Bilateral impaction (%)
Maxilla	235 (23.91)
Mandible	465 (47.30)
Both	283 (28.79)
Total	983 (100)

Table 5: Bilaterally impacted maxillary and mandibular third molars.

Relationship to ramus	No. of teeth (%)
Class I	723 (29.02)
Class II	1,698 (68.17)
Class III	70 (2.81)
Total	2,491 (100)

Table 6: Relationship between impacted mandibular third molar and mandibular ramus.

Parameters	Proximity to sinus (%)	Significant
Angulation		
Horizontal	1 (0.5)	0.637
Mesioangular	121 (60.5)	< 0.005
Distoangular	25 (12.5)	0.234
Vertical	53 (26.5)	0.167
Total	200 (100)	
Position		
A	4 (2.02)	0.8
B	71 (35.86)	0.183
C	123 (62.12)	< 0.005
Total	198 (100)	

Table 7: Relationship between angulation, position of impacted maxillary third molar and its proximity to maxillary sinus floor.

The positions (levels) of impacted maxillary and mandibular third molars were shown in Tables 5 and 6. Position B was the most found in both maxillary and mandibular impacted third molars. Bilateral impaction were found in 983 cases (68.89%), the majority of which were in the mandible, as shown in Table 7.Class II ramus relationship was more prevalent followed by Class I and Class III, respectively (Table 8).

Variable	Proximity to canal (%)	Significant
Angulation		
- Horizontal	109 (16.10)	0.33
- Mesioangular	628 (71.36)	< 0.005
- Distoangular	43 (17.13)	0.23
- Vertical	56 (8.27)	0.52
Position		
- A	132 (23.74)	0.103
- B	845 (75.31)	< 0.005
- C	685 (84.25)	< 0.005
Ramus relationship		
- Class I	455 (62.93)	< 0.005
- Class II	1,217 (67.95)	< 0.005
- Class III	15 (21.42)	0.125

Table 8: Relationship between angulation, position of impaction and ramus relationship of impacted mandibular third molar and proximity of the tooth to mandibular canal.

There was significant relationship between mesioangulation of impacted maxillary third molar and proximity of the tooth and maxillary sinus floor (Table 9). Position C impacted maxillary third molar was significant related to the proximity of the tooth to maxillary sinus floor (Table 10). Table 11 showed the relationship between angulation, position of impaction and ramus relationship of impacted mandibular third molar and proximity of the tooth to mandibular canal. There were significant relationships between impacted mandibular third molar with mesioangulation, position B and C, class I and II ramus relationship and proximity of the tooth to mandibular canal.

Microdontia was the most found developmental abnormalities (135 patients, 9.46%), followed by missing tooth (92 patients, 6.45%), and supernumerary tooth (87 patients, 6.1%), respectively. The other finding abnormalities such as dens invaginatus, fusion, and germination were also found.

Discussion

The preponderances and variations of impacted third molars are different between racial and ethnics. These may be due to racial genetic properties, as well as the other factors such as consuming habits.[21] In Thai population, we assumed that the possible etiologies of impacted third molar could be tooth jaw size discrepancy, late third third molar mineralization and early physical maturation.

There were many studies about impacted third molar patterns in different population such as in Singapore Chinese[3], Jordanians[7], Saudi community[8], Swedish[10], and Nigerians.[22] For the assessment of distribution of impacted teeth in maxilla and mandible, we found that the number of impacted mandibular third molar was higher (2,845 teeth, 58.85%). Our finding was conformed to Pillai et al.[21] who evaluated the position of impacted third molars on 1,000 panoramic radiographs of Indian population. However, our result was contrary to that of Elisabeth et al. (Swedish)[23], Hattab et al. (Jordanian)[7], which showed the higher proportion of impacted maxillary third molars. We found a more frequency of impacted third molars in female, like Queket al.[3] and Eshghpour et al. (Iranian).[11] In female, the end of the growth spurt is closely linked with the onset of menarche. Thomas et al.[24] reported that menarche is largely influenced by extrinsic factors like living conditions, for example, health and socioeconomic conditions and energy balance related to physical activities, rather than genetics. This could support to the theory of late third molar mineralization in combination with early physical maturity as an important etiologic factor.

In the present study, vertical angulation and position B impacted third molar was most common inmaxilla. Our result was different from the study by Lim et al.[17] who reported that position A impacted maxillary third molar was most common. Regarding to the patterns of impacted third molar in mandible, the tooth with mesioangulation, class II and position B were most found. These findings were in accordance with Queket al.[3] who surveyed the pattern of third molar impaction on panoramic radiographs of Singapore Chinese. They also concluded that the frequency of impacted third molars in Singapore Chinese was higher than that found in Caucasian. Of 983 patients, the number of bilaterally impacted third molar was higher in mandible (47.30%), like the study by Quek et al. (Singapore Chinese).[3]It is very hard to equate the prevalence of impacted third molar pattern because of various classification systems in different studies. In addition, most studies evaluated angulation of impacted tooth by visualization alone.

There was a few studies concerned about the relationship between patterns of impacted third molar and important adjacent structures such as maxillary sinus and mandibular canal.[17,25,26] In regard to the relation of impacted maxillary third molar to maxillary sinus, the results of our study showed that the tooth with mesioangulation and position C were found to be in the close proximity to sinus floor (p <0.005). We defined sinus proximity as no bony tissue between third molar and maxillary sinus floor observed on panoramic radiograph. Lim et al.[17] examined the patterns of impacted maxillary third molar and reported that 91.10% of the tooth had proximity to maxillary sinus, however, they did not mentioned about the pattern of the tooth that most found approximately.

For the evaluation of impacted mandibular third molars, the tooth with mesioangulation, position B and C, class I and II ramus relationship was found to be in the close proximity to mandibular canal (p <0.005). Also,

we defined mandibular canal proximity as no bony tissue between third molar and mandibular canal observed on panoramic radiograph. The present study, however, was performed only by radiographic assessment. The recording of proximity after surgery is recommended for the further study.

To our knowledge, there were two studies reported about the incidence and type of impacted third molar in Thai population.[4,5] However, both of the two studies were performed in less number of patients and they reported only the tooth angulation and concerned more about common related symptoms or complications. Thus, it may be said that our study results represent the pattern of impacted third molar in a group of Thai population.

Conclusions

It may be concluded that the patterns of impacted third molars in a group of Thai population are not entirely different from that of other nationalities. The further studies including advanced imaging techniques and postsurgical recordings are needed to confirm conventional radiographic findings.

Acknowledgements

This study was supported by Naresuan University.

Declaration of Interest

The authors report no conflict of interest.

References

1. Bishara SE. Impacted maxillary canines: a review. Am J Orthod Dentofacial Orthop. 1992; 101(2): 159-71.
2. Fanning EA, Moorrees CF. A comparison of permanent mandibular molar formation in Australian aborigines and Caucasoids. Arch Oral Biol. 1969; 14(9): 999-1006. (Abstract)
3. Quek SL, Tay KH, Toh SL, Lim KC. Pattern of third molar impaction in a Singapore Chinese population: a retrospective radiographic survey. Int J Oral Maxillofac Surg. 2003; 32(5): 548-52.
4. Tudsri S. Incidence of impacted wisdom teeth and complication in Thai community. J Dent Assoc Thai. 1988; 38(4): 163-9.
5. Unwerawattana W. Common symptoms and type of impacted molar tooth in King Chulalongkorn Memorial Hospital. J Med Assoc Thai. 2006; 89(S3): 134-9.
6. Kaya GS, Aslan M, Ömezli MM, Dayi E. Some morphological feature related to mandibular third molar impaction. J ClinExp Dent. 2010; 2(1): 12-7.
7. Hattab FN, Rawashdeh MA, Fahmy MS. Impaction status of third molars in Jordanian students. Oral Surg Oral Med Oral Pathol Oral RadiolEndod. 1995; 79(1): 24-9.
8. Haidar Z, Shalhoub SY. The incidence of impacted wisdom teeth in a Saudi community. Int J Oral Maxillofac Surg. 1986; 15(5): 569-71.
9. Hashemipour MA, Tahmasbi-Arashlow M, Fahimi-Hanzaei F. Incidence of impacted mandibular and maxillary third molars: a radiographic study in Southeast Iran population. Med Oral Patol Oral Cir Bucal. 2013; 18(1): 140-5.
10. Hugoson A, Kugelberg CF. The prevalence of third molars in a Swedish population. An epidemiological study. Community Dent Health. 1988; 5(2): 121-38.
11. Eshghpour M, Nezadi A, Moradi A, MahvelatiShamsabadi R, Rozaei NM, Nejat A. Pattern of mandibular third molar impaction: A cross-sectional study in northeast of Iran. Nig J ClinPrac. 2014; 17(6): 673-7.
12. Màaita J, Alwrikat A. Is the mandibular third molar a risk factor for mandibular angle fracture? Oral Surg Oral Med Oral Pathol Oral Radiol Endod. 2000; 89(2): 143-6.
13. Thangavelu A, Yoganandha R, Vaihyanathan A. Impact of impacted mandibular third molars in mandibular angle and condylar fractures. Int J Oral Maxillofac Surg. 2010; 39(2): 136-9.
14. Gaddipati R, RamisettyS, Vura N, Kanduri RR, Gunda VK. Impacted mandibular third molars and their influence on mandibular angle and condyle fractures-A retrospective study. J Craniomaxillofac Surg. 2014; 42(7): 1102-5.
15. Almendros-Marqués N, Alaejos-Algarra E, Quinteros-Borgarello M, Berini-Aytés L, Gay-Escoda C. Factors influencing the prophylactic removal of asymptomatic impacted lower third molars. Int J Oral Maxillofac Surg. 2008; 37(1): 29-35.
16. Beeman CS. Third molar management: a case for routine removal in adolescent and young adult orthodontic patients. J Oral Maxillofac Surg. 1999; 57(7): 824-30.
17. Lim AA, Wong CW, Allen Js JC. Maxillary third molar: patterns of impaction and their relation to oroantral perforation. J Oral MaxillofacSurg2012; 70(5): 1035-9.
18. Winter GB. Impacted third molars, American Medical Book Co.,ST. Louis. 1926: 241-79.
19. Sciller WB. Positional changes in mesioangular impacted third molars during a year. J Am Dent Assoc. 1975; 99(3): 460-4. (Abstract)
20. Archer W. Oral and Maxillofacial Surgery,Saunders, Philadelphia. 1975: 259-60, 311.
21. Pillai AK, Thomas S, Paul G, Singh SK, Moghe S. Incidence of impacted third molars: a radiographic study in people's hospital, Bhopal, India. J Oral Biol Craniofac Res. 2014; 4(2): 76-81.
22. Odusanya SA, Abayomi IO. Third molar eruption among rural Nigerians. Oral Surg Oral Med Oral Pathol. 1991; 71(2): 151-4.
23. Elisabeth S, Leif L, Madeleine R. Prevalence of impacted third molar in dental students. Swed Dent J. 1989; 13(1-2): 7-13.
24. Thomas F, Renaud F, Beneface E, Demeeus T, Guegan JF. International variability of ages at menarche and menopause: patterns and main determinants. Hum Biol. 2001; 73(2): 271-90.
25. Nakagawa Y, Ishii H, Nomura Y, Watanabe NY, Hoshiba D, Kobayashi K, et al. Third molar position: reliability of panoramic radiography. J Oral Maxillofac Surg. 2007; 65(7): 1303-8.
26. Deshpande P, Guledgud MV, Patil K. Proximity of impacted mandibular third molars to the inferior alveolar canal and its radiographic predictors: a panoramic radiographic study. J Maxillofac Oral Surg. 2013; 12(2): 145-51.