

## Gingival Hyperplasia Around Dental Implants in Jaws Reconstructed with Free Vascularized Flaps: A Case Report Series

Brauner E<sup>1</sup>, Valentini V<sup>1</sup>, De Angelis F<sup>1\*</sup>, Jamshir S<sup>1</sup>, Visca A<sup>1</sup>, Romeo U<sup>1</sup>, Tenore G<sup>1</sup>,  
Pompa G<sup>1</sup>, Di Carlo S<sup>1</sup>

1. Department of Oral and Maxillofacial Sciences, "Sapienza" University of Rome, Rome, Italy.

### Abstract

Free vascularized flaps are the gold standard for reconstruction of the facial skeleton after surgical ablation of pathologies or when important atrophy of the jaws exists. A frequent problem seen during prosthetic rehabilitation after reconstruction with free vascularized flaps is the onset of hyperplastic granulomatous reactive tissue around the prosthetic abutment of the implant. The features of this phenomenon seem to be directly related to the characteristics of the peri-implant tissue and of the manufacturing materials of the prosthesis and abutments. This complication can be seen quite often; we found it in 7 of 40 patients (17.5%). It does not seem to significantly affect the survival rate of implants. The aim of the study was to analyze the behavior of such lesions and to suggest our clinical approach with the management of these kinds of patients and complications. To remove gingival hyperplasia, we used either a traditional cold scalpel or an electric cautery or laser. We had good results using these tools.

The onset of this phenomenon was not influenced by either the kind of implant and free flaps used or by the local conditions of the patients (such as radiotherapy). The number of recurrences was highly influenced by the oral hygiene of the patients.

*Clinical article (J Int Dent Med Res 2018; 11(1): pp. 1-7)*

**Keywords:** Facial skeleton, head and neck cancer, maxillo-facial surgery, prosthetic rehabilitation.

**Received date:** 13 October 2017

**Accept date:** 24 November 2017

### Introduction

Bony gaps in the mandible or in the maxilla, after ablation of tumors or osteoradionecrosis, may cause a series of problems for patients, such as facial contour disfigurements, oro-nasal or oro-antral communication and impaired oral functions. The goal of maxillofacial surgery is to restore the shape and the function of the oral region.<sup>1</sup> Tooth loss and alveolar or basal bone loss can lead to significant impairments during mastication. The use of free vascularized flaps is a valuable instrument for rehabilitating head and neck oncological patients despite unfavorable local conditions such as large defects, irradiation, and

a paucity of surrounding soft tissues. The bone segment can be transplanted with muscle and a skin pad, allowing simultaneous reconstruction of both hard and soft tissues, resulting in considerable improvements in facial contour and oral functions such as speech and deglutition. Furthermore, the chance of positioning dental implants in the reconstructed areas makes it possible to overcome the problems related to dental rehabilitation with removable prosthesis.

A large number of donor sites, such as the iliac crest, scapula, radial forearm, or fibula, can provide vascularized bone and soft tissue for jaw reconstruction.<sup>2-7</sup>

When both hard and soft tissues are to be reconstructed, the iliac crest flap or fibula flap are widely used. Implant-supported rehabilitation provides superior performance in these cases because it provides greater stability for the prosthesis while allowing direct access to the tissues when applying screws.<sup>8-12</sup>

Rehabilitating patients undergoing surgery for head and neck pathologies is challenging. A particular kind of complication, reported in the literature, is the onset of gingival

#### \*Corresponding author:

Francesca De Angelis  
Department of Oral and Maxillofacial Sciences,  
"Sapienza" University of Rome,  
Rome, Italy.  
Phone: 0039-338 1819312  
E-mail: francescadeangelis45@gmail.com

hyperplasia around dental implants on osteomyocutaneous free flaps used to reconstruct facial structures after ablative surgery.<sup>10,13-16</sup>

This complication primarily causes bleeding, pain, and esthetic problems, but it is important to specify that the underlying peri-implant bone does not react negatively with bone reabsorption in the short term (6-12 months). To avoid this complication, various methods have been suggested, including topical application of silver nitrate and surgical application of extra-oral skin grafts around the prosthetic abutment.<sup>10,13,17,18</sup> Several researchers agree that an important role in the etiopathogenesis of this reactive tissue is played by the acrylic materials of which the provisional abutments and provisional prostheses are made.<sup>10,13,17-19</sup>

Between 2009 and 2014, we found that 7 of 40 patients (17.5%) treated with implant-supported rehabilitation on free vascularized flaps experienced this complication. In this paper, we will analyze the behavior of such lesions and suggest our clinical approach with the management in rehabilitating these patients by presenting these 7 cases, 6 of which were treated using a cold blade scalpel and electric cautery, while the other was treated with laser therapy.

### Materials and methods

While rehabilitating patients reconstructed with vascularized free flaps after ablative surgery for head and neck neoplasm, or during their follow-up, we noticed the onset of this particular granulation tissue around the fixtures. This complication has been detected quite often; we found it in 7 out of 40 patients (17.5%). It does not seem to significantly affect the survival rate of implants.

The lesions were removed as soon as they were detected.

Gingival hyperplasia was then removed as follows:

- A traditional cold blade scalpel was used with or without application of a periodontal pack to obtain histological specimens as a first approach in all patients. Specimens were subjected to histological analysis.
- Electric cautery was used in case of more than 3 recurrences.

- If further recurrence was seen, a super pulsed CO<sub>2</sub> laser (US20D; DEKA®, Italy) was used.
- A periodontal pack (COE PACK®) was used to aid in healing.

A standardized protocol of five clinical examinations every 3 months was scheduled and oral health conditions were evaluated at the first check-up (Table 1).

<i>First visit, T0:</i>
Orthopantomography (OPG) requested
Periodontal and gingival examination: PI and CPITN
<i>Second Visit, T1 (3 months later):</i>
Scaling: tartar removal using ultrasonic instruments
Instructions for oral hygiene
<i>Third Visit, T2 (6 months later):</i>
Periodontal and gingival reevaluation: PI and CPITN
Scaling: tartar removal using ultrasonic instruments
<i>Fourth Visit, T3 (9 months later):</i>
Periodontal and gingival reevaluation: PI and CPITN
Scaling: tartar removal using ultrasonic instruments (if necessary)
<i>Fifth visit, T4 (12 months later):</i>
Orthopantomography (OPG) requested
Periodontal and gingival reevaluation: PI and CPITN
Scaling: tartar removal using ultrasonic instruments

**Table 1.** Oral hygiene protocol.

The plaque index (PI) and the community periodontal index of treatment needs (CPITN) were used to assess oral hygiene and periodontal conditions, recorded on a 3-point scale (*poor/good/optimum*).

Oral hygiene instructions were given to each patient, through the use of suitable teaching aids. The brushing technique was adapted and customized for each patient, illustrating the use of a manual toothbrush (Oral-B® Pro-Expert® Cross Action®). For the cleaning of interdental spaces the indication was the use of a dental floss (GUM Expanding Floss®) or a brushing (TePe Interdental brushes-Originals®), or both.

### Outline of the cases

#### Case 1

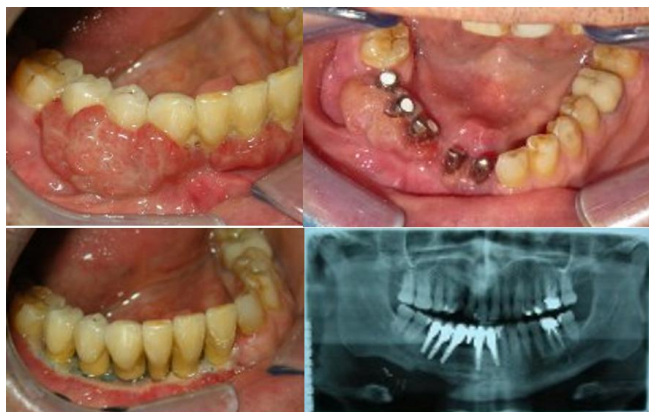A 47-year-old female presented ameloblastoma of the mandible in the symphysis region. A free vascularized iliac crest flap was used to reconstruct the missing bone. One-and-a-half years after reconstructive surgery, 8 implants (Biomet3I LLC®) were placed, 5 on the iliac crest flap and 3 on the remaining mandibular bone.

Provisional acrylic rehabilitation was immediately cemented on 5 provisional titanium abutments. It is important to underline that gingival hyperplasia formed only around implants

placed in the free vascularized flaps. Six months after implant positioning, provisional abutments were also placed on the remaining implants, and the provisional rehabilitation was cemented on all implants. After 3 surgeries performed with a cold blade scalpel for fornix deepening, gingival hyperplasia was reduced and prosthetic rehabilitation was completed. The patient practiced adequate oral hygiene and she reached *good* oral hygiene. After 18 months of follow-up, no recurrences were detected.

### Case 2

A 58-year-old male presented ameloblastoma of the mandible on the right side. A free vascularized iliac crest flap was used to reconstruct the missing bone. Eight months after surgery, 5 implants (Biomet3I LLC®) were placed on the vascularized flap. During various phases of work, the patient was rehabilitated with a provisional acrylic restoration cemented on the provisional abutment. Quick onset of gingival hyperplasia around the implants was observed.



**Figure 1.** Intraoral view of lesion's behavior.

Five months after positioning the implants, definitive metal-ceramic cemented crowns were delivered. Four weeks later, growth of exuberant granulation tissue around the definitive abutments and crowns was found. Cold blade scalpel and cautery were initially used to remove the gingival hyperplasia, but recurrence was observed after a few weeks. After four surgical removals, laser surgery was performed. SuperpulsedCO<sub>2</sub> laser (US20D; DEKA®, Italy) was used because of its photothermal effect. Settings were: 100 HZ frequency, 1.5 to 1.7 W power, 1432.12 W/cm<sup>2</sup> power density, and 14.32 J/cm<sup>2</sup> energy density in pulsed wave mode. Because of hemostatic effects obtained by the

laser, no suture was applied. After partial recurrence, the laser was used a second time.<sup>20</sup> It is important to emphasize that the patient practiced *poor* oral hygiene through the therapy period, necessitating several professional oral hygiene sessions. After 6 months of follow-up, no recurrence was observed (Figure 1).

### Case 3

A 43-year-old female underwent ablative surgery of the right mandible, oral pelvis, and ipsilateral tongue for an infiltrating carcinoma. This area was simultaneously reconstructed using an anterolateral thigh flap because the continuity of the mandible was preserved. The minor bone loss was reconstructed using intraoral mandibular grafts during a second surgical stage. The patient did not receive radiotherapy. The reconstructive phase was followed by an intervention to deepen the oral fornix, using a skin paddle to normalize the anatomy of the area.

Two years later, after rehabilitation with a removable partial denture, 2 implants (Zimmer Dental Inc.®) were placed in the right side of the mandible using a two-stage technique. Implants were uncovered after 4 months, and gingival hyperplasia was observed around the healing abutment after a few weeks. The hyperplasia was removed using a cold blade scalpel, and no immediate recurrence was seen. However, during a routine check one year after definitive metal-ceramic cemented crowns were placed, small areas of gingival hyperplasia were found. Again, removal was performed using a cold blade scalpel. The patient practiced discrete oral hygiene and she reached *good* oral hygiene. After 12 months follow-up, no signs of recurrence were seen.

### Case 4

A 68-year-old male presented with a malignant tumor of the left mandible. Ablative surgery was performed. Because of the continuity of the mandibular bone, it was simultaneously reconstructed using a radial muscle flap. The patient underwent radiotherapy.

Five years after completing radiotherapy, the patient received dental therapies. As a result of radiotherapy, some teeth had already been lost, and the remaining elements were severely compromised from a periodontal point of view. The remaining teeth were therefore extracted,

and rehabilitation was accomplished with a total removable denture with the project to replace it with a screwed implant-supported rehabilitation.

During routine radiological studies,<sup>21</sup> an implant was found submerged in the zone reconstructed by the radial muscle flap. No radiological signs of bone loss were found. This implant (Prodent Italia srl®) was placed in the zone of the element 3.6 before the oncological surgery, covered before the reconstructive surgery and not further loaded. Using a radiological surgical template obtained from the new denture, 5 implants (BioHorizons IPH, Inc®) were placed in the mandible. Four months after positioning the implants, they were uncovered, and the healing abutment was also placed on the implant replacing the element 3.6.

In the first stage, a provisional resin restoration was cemented onto the provisional abutment, and after a few weeks, granulation tissue was observed only around the implants covered by the radial flap. This tissue was removed using a cold blade scalpel, and once the definitive screwed restoration was placed, no reappearance was observed over one year of follow-up. The patient practiced adequate oral hygiene and he reached *good* oral hygiene.

#### Case 5

A 73-year-old female underwent reconstructive surgery for significant atrophy of the mandible that did not allow implant-supported rehabilitation. A fibula free flap was used to reconstruct the mandible. One year later, 8 implants (Camlog Biotechnologies AG®) were placed using a two-stage technique. Implants were uncovered after 6 months. To aid tissue healing, a skin graft was placed around the healing abutment while uncovering the implants. A provisional cemented resin restoration was placed on the abutments.

After a few weeks, gingival hyperplasia appeared. The granulation tissue was removed 3 times using a cold blade scalpel. Local conditions improved when the definitive metal-ceramic cemented restoration was placed. The patient practiced discrete oral hygiene and she reached good oral hygiene. No recurrence of gingival hyperplasia was seen after one year of follow-up.

#### Case 6

A 47-year-old female underwent ablative surgery for a malignant tumor of the mandible on

the right side. Because the demolitive phase was extensive and involved the ramus and condyle of the mandible, a fibula free flap was used in the simultaneous reconstructive phase. The patient did not receive radiotherapy.

Six months after surgery, 3 implants (Camlog Biotechnologies AG®) were placed on the flap. A two-stage technique was used, and the implants were uncovered after six months. No complications were experienced with the cemented provisional acrylic restoration or the cemented definitive cemented metal-ceramic restoration, each lasting about three months. During a routine exam ten years later, gingival hyperplasia was found around the definitive restoration. Because the hyperplasia made it difficult to achieve good oral hygiene, peri-implantitis and a peri-implant pocket developed, and 1 implant had to be removed. The patient practiced adequate oral hygiene and she reached *good* oral hygiene. The hyperplasia was removed using a cold blade scalpel and cautery, and at 6 months follow-up, no recurrence was seen.

#### Case 7

A 49-year-old male underwent ablative surgery for a malignant tumor on the left lingual margin not involving bony structures. For this reason, an anterolateral thigh flap was used in the simultaneous reconstructive phase. The patient did not receive radiotherapy.

Five years after reconstructive surgery, 5 implants (BioHorizons IPH, Inc®), 3 on the side of the free vascularized flap and 2 on the other side, were placed. A two-stage technique was used, and the implants were uncovered six months later. Three weeks after positioning the healing screws, the onset of gingival hyperplasia was seen around the implants placed under the soft tissue flap. After removal using a cold blade scalpel, the prosthetical phases could be completed, allowing placement of the definitive restoration. The patient practiced adequate oral hygiene and he reached *good* oral hygiene. Follow-up after two years showed no further recurrence of gingival hyperplasia.

#### Discussion

Progress achieved in oral pathologies and maxillofacial surgery offers early diagnosis of head and neck diseases, and surgical treatment

achieves higher success rates, enabling prosthetic rehabilitation after the surgical stage. A multidisciplinary opinion is essential and, before any decision, the surgeon examines the patient. In general, surgical approach represents the treatment of choice and a good efficacy/functional impact balance must be evaluated<sup>22</sup>. Treating this kind of patient is challenging and represents a new scope, exposing new and unknown difficulties that occur every day<sup>23</sup>. Implant-supported rehabilitation is considered the gold standard, improving patients' quality of life and allowing health care workers (dentists, maxillo-facial surgeons, and oral pathologists) to check oral tissues at any moment to prevent recurrences<sup>24-25</sup>.

Producing an implant-supported restoration for these patients obviously presents difficulties because of anatomical changes and local conditions related to previous treatments the patient may have undergone, such as chemo- and/or radiotherapy<sup>26</sup>. These seven cases document an important and frequent problem during prosthetic rehabilitation of patients reconstructed using free vascularized flaps<sup>27</sup>.

Gingival hyperplasia primarily causes bleeding, pain, and esthetic problems, yet it is important to underline that the underlying peri-implant bone does not react negatively with bone resorption. This exuberant and extremely soft tissue can cause problems while taking dental impressions and during various phases of prosthetic work. Three surgical techniques cold blade scalpel, cautery, and laser were used to remove the hyperplasia, and various behaviors were seen.

The cold blade scalpel was the first choice because its immediate use allowed a piece of tissue, which could be subjected to histopathological examination, to be obtained. This allowed determination of the kind of pathology present. Cautery was used to remove the hyperplasia in recurrences, taking advantage of its coagulative and cutting abilities for removing friable and vascularized tissue. When further recurrences were seen, the superpulsed CO<sub>2</sub> laser was used because it employed a wavelength between 9.4 and 10.3 micrometers and was absorbed by water. This laser has the advantages of rapid execution, hemostasis control (cutting precision and absence of suture), comfort during and post-surgery, no implant

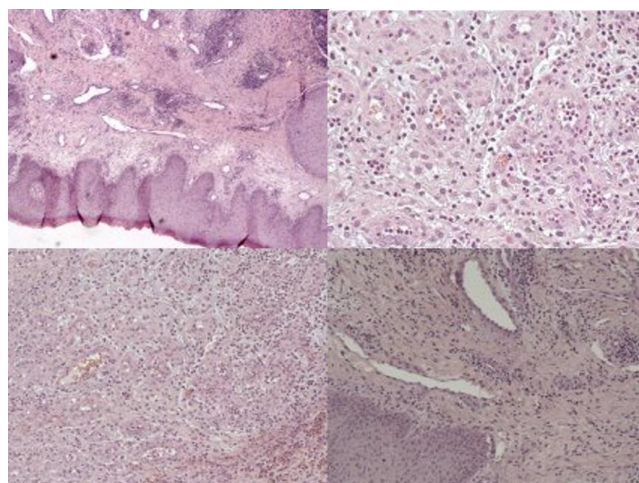
damage (if used in safe parameters), good healing, lower risk of relapse as a consequence of minor collagen formation, and capillary proliferation.<sup>20</sup>

Hyperplasia was observed when the implants were uncovered and also after the definitive restoration was placed. Recurrences were noted during both short- and long-term follow up. Gingival hyperplasia appears more frequently in patients who practiced poor oral hygiene, and it is not influenced by the type of dental implants used, sometimes prosthetic devices imply accumulation of bacterial plaque and food.<sup>28</sup> Only one implant had to be removed, and in this case, it was after 10 years and because of the onset of peri-implantitis supported by the presence of hyperplasia, which prevented adequate oral hygiene around the implant. The hyperplasia did not damage the peri-implant bone, and there was no bone resorption around the implants once the hyperplasia was removed, soon after its appearance.

## Conclusions

The key points to emphasize are:

The particular type of behavior of this lesion is probably due to the lack of keratinized gingiva and by the presence in its place of cutaneous tissue.



**Figure 2.** Images of histological pieces of different lesions.

The results of histopathological examinations always showed oral mucosa with parakeratosis, papillomatosis, and acanthosis with normal maturation of the squamous epithelium. The typical feature of this lesion was the aspect of the submucosa characterized by an

inflammatory lymphoplasmacytic and neutrophilic infiltrate and a vascular proliferation resembling granulation tissue (Figure 2). The onset of hyperplasia was not influenced by the type of free vascularized flap used for reconstruction. The behavior of gingival hyperplasia was not influenced by the characteristics of the fixtures used; its onset was observed in patients rehabilitated with six different dental implant brands. The recurrence rate was highly related to the quality of oral hygiene practiced by the patients; those with good oral hygiene had no recurrence or a lower recurrence rate than those with poor oral hygiene. The onset of gingival hyperplasia was not influenced by the type of prosthetic rehabilitation provisional vs. definitive or screwed vs. cemented, gingival hyperplasia was detected in all of these situations.

This particular complication did not cause resorption of the peri-implant bone by itself, but could contribute to poor oral hygiene, causing the onset of peri-implantitis.

We have described our experience with this particular complication and have suggested a proper way to address it. The main idea to underline is that such patients need continuous follow-up spanning years, and proper emphasis should be given to good oral hygiene and the conditions of the prosthetic rehabilitation to avoid this complication.

### Declaration of Interest

Authors declare that they have no conflict of interest and did not receive funding from any organization.

### References

1. Pacifici L., De angelis F., Orefici A., Cielo A. Metals used in maxillofacial surgery. *Oral Implantol (Rome)*. 2017 Feb 14;9(Suppl 1/2016 to N 4/2016):107-111.
2. Ferri J, Caprioli F, Peuvrel G, et al: Use of the fibula free flap in maxillary reconstruction: a report of 3 cases. *J Oral Maxillofac Surg*. 2002;60:567-574.
3. Hidalgo DA. Fibula free flap: a new method of mandible reconstruction. *Plast Reconstr Surg*. 1989;84:71-79.
4. Hidalgo DA, Rekow A. A review of 60 consecutive fibula free flap mandible reconstructions. *Plast Reconstr Surg*. 1995;96:585-596.
5. Van Gemert JT1, Van Es RJ, Rosenberg AJ, et al: Free vascularized flaps for reconstruction of the mandible: complications, success, and dental rehabilitation. *J Oral Maxillofac Surg*. 2012;70:1692-1698.
6. Pompa V, Valentini V, Pompa G, et al: Treatment of high-flow arteriovenous malformations (AVMs) of the head and neck with embolization and surgical resection. *Ann Ital Chir*. 2011;82:253-260.
7. Cassoni A., Valentini V., Della Monaca M. et al. Keratocystic odontogenic tumor surgical management: retrospective analysis on 77 patients. *Eur J Inflamm*. 2014;12(1):209-15.
8. Chiapasco M, Abati S, Ramundo G, et al: Behavior of implants in bone grafts or free flaps after tumor resection. *Clin Oral Implants Res*. 2000;11:66-75.
9. Riediger D. Restoration of masticatory function by microsurgically revascularized iliac crest bone grafts using enosseous implants. *Plast Reconstr Surg*. 1988;81:861-877.
10. Chiapasco M, Biglioli F, Autelitano L, et al: Clinical outcome of dental implants placed in fibula-free flaps used for the reconstruction of maxillo-mandibular defects following ablation for tumors or osteoradionecrosis. *Clin Oral Implants Res*. 2006;17:220-228.
11. Brauner E, Valentini V, Jamshir S, et al: Two clinical cases of prosthetic rehabilitation after a tumor of the upper maxilla. *Eur Rev Med Pharmacol Sci*. 2012;16:1882-1890.
12. Pompa G, Saccucci M, Di Carlo G, et al: Survival of dental implants in patients with oral cancer treated by surgery and radiotherapy: a retrospective study. *BMC Oral Health*. 2015;15:5.
13. Ciocca L, Corinaldesi G, Marchetti C, et al: Gingival hyperplasia around implants in the maxilla and jaw reconstructed by fibula free flap. *Int J Oral Maxillofac Surg*. 2008;37:478-480.
14. Ferrari S, Copelli C, Bianchi B, et al: Rehabilitation with endosseous implants in fibula free-flap mandibular reconstruction: a case series of up to 10 years. *J Craniomaxillofac Surg*. 2013;41:172-178.
15. De Angelis F., Papi P., Mencio F., Rosella D., Di Carlo S., Pompa G. Implant survival and success rates in patients with risk factors: results from a long-term retrospective study with a 10 to 18 years follow-up. *Eur Rev Med Pharmacol Sci*. 2017;21:433-437.
16. Valentini V, Terenzi V, Cassoni A, et al: Giant cell lesion or langerhans' cell histiocytosis of the mandible? A case report. *Eur J Inflamm*. 2012;10: 159-164.
17. Alpert A. A rationale for attached gingiva at the soft-tissue/implant interface: esthetic and functional dictates. *Compendium*. 1994;15:356,358,360-2 passim; quiz 368.
18. Jaquiéry C, Rohner D, Kunz C, et al: Reconstruction of maxillary and mandibular defects using prefabricated microvascular fibular grafts and osseointegrated dental implants – a prospective study. *Clin Oral Implants Res*. 2004;15:598-606.
19. Masuelli L, Pompa G, Fabrizi M, et al: Patients with peri-implantitis, unlike those with a healthy periimplant microenvironment, display antibodies to more than one heat shock protein (HSP 27, HSP 65 and HSP 90) linear epitope. *Eur J Inflamm*. 2011;9:257-267.
20. G. Palaia, A. Del Vecchio, A. Impellizzeri, et al: Histological Ex Vivo Evaluation of Peri-Incisional Thermal Effect Created by a New-Generation CO2 Superpulsed Laser. *Scientific World Journal*. 2014;2014:345685.
21. Cassetta M, Di Carlo S, Pranno N, et al: The use of high resolution magnetic resonance on 3.0-T system in the diagnosis and surgical planning of intraosseous lesions of the jaws: Preliminary results of a retrospective study. *Eur Rev Med Pharmacol Sci*. 2012;16:2021-2028.
22. De Felice F, De Vincentiis M, Valentini V et al. Management of salivary gland malignant tumor: the Policlinico Umberto I, "Sapienza" University of Rome Head and Neck Unit clinical recommendations. *Critical Reviews in Oncology / Hematology*. 2017; 120: 93–97.
23. Pagnoni M, Amodeo G, Cassoni A. et al. Juvenile idiopathic/rheumatoid arthritis and orthognatic surgery without mandibular osteotomies in the remittent phase. *Journal of craniofacial surgery*. 2013;24(6).
24. Brauner E, Guarino G, Jamshir S. et al. Evaluation of Highly Porous Dental Implants in Postablative Oral and Maxillofacial Cancer Patients: A Prospective Pilot Clinical Case Series Report. *Implant Dent*. 2015;24(5):631-7.

25. Brauner, E., Pompa, G., Quarato, A. et al. Maxillofacial prosthesis in dentofacial traumas: A retrospective clinical study and introduction of new classification method. *Biomed Res Int.* 2017;2017:8136878.
26. Brauner E., Valentini V., Guarino G. et al. Osteoradionecrosis of a mandible: a case report of implant supported rehabilitation. *Eur J Inflamm.* 2013;11(2):565-571.
27. Brauner E, Valentini V, Jamshir S. et al. Retrospective review of 78 rehabilitated head and neck postoncological patients: a new classification method. *Minerva Stomatol.* 2016;65(1):17-32.
28. Pompa, G., Brauner, E., Jamshir, S., De Angelis, F., Giardino, R., Di Carlo, S. Quality of life in patients rehabilitated with palatal obturator without reconstruction versus fixed implant-prosthesis after reconstruction of maxillectomy defects. *J Int Dent Med Res.* 2017;10(1):1-8.