Effect of Stichopus Hermanni to Remodeling Maxillary Suture Expansion on Craniofacial Structure and Teeth

Noengki Prameswari[1*], Henry Sebastian[1], Rahma Ariesti[1], Kristin Gaby Rosari[1], Kenny Rama Widya[1], Ela Amelia[1], Fatimah Batul[1], Fenny Felia[1], Flavia Pratamaningdyah[1], Pambudi Rahardjo[1], Lisdiana Mardanus[1], Sarianoferni[2], Emy Khoironi[2]

1. Orthodontic department. Dentistry Faculty Hang Tuah University, Surabaya, Indonesia.
2. Radiology department. Dentistry Faculty Hang Tuah University, Surabaya, Indonesia.

Abstract

Expansion appliance is one of many types of orthodontic appliance that make tooth movement and expand maxilla suture. Maxilla suture opening will affect cranial width, bizygomatic width, bigonial width, and insisivi distance. Stichopus hermanii contains flavonoid, glycosaminoglycan and fat acid that enhances bone remodeling.

This research aims to know the effect of Stichopus hermanii gel on maxilla suture expansion remodeling towards craniofacial structure and teeth by using cephalometric analysis.

24 Male Cavia cobaya were divided into 4 groups (n=6). K(-) as the negative control group. Helical spring were applied to the other 3 groups for 10 days. K(+) was given NaCMC 2% gel, P1 and P2 were given Stichopus hermanii gel 3%. P2 was enforced retention period for 10 days after activation period. Experimental units were decapitated and cranial width, bizygomatic width, bigonial width as craniofacial structures and teeth had been observed by using cephalometric analysis, then collected data were analyzed with One Way ANOVA test and continued with LSD test. One Way ANOVA test result showed significant difference in treated group p=0,004 (p<0,05). LSD test showed significant difference between K(-) and K(+) (Sig. 0,016), K(-) and P1 (Sig. 0,003), as well K(-) and P2 (Sig. 0,001).

According to the research, 3% of Stichopus Hermanni's gel with a slow maxillary expansion showed that appliance can increase the cranial width and insisivi distance but can't increase the bizygomatic and bigonial width using cephalometric analyze, so that the expansion appliance only expanded in the small distance. The use of retension in this research give a role to maintain the result of expansion and give the best result.

Experimental article (J Int Dent Med Res 2020; 13(1): 73-79)

Keywords: Orthodontic movement, Expansion appliance, Stichopus hermanni, Craniofacial Structure, Teeth.

Received date: 10 March 2019 **Accept date:** 19 May 2019

Introduction

Orthodontic treatment is commonly for Psychological factors, to improve the aesthetically of teeth[1]. Inharmonious dental irregularities and relationship between jaws can affect the mastication system, digestive system and also the articulation system or pronounciation[2]. Malocclusion has a high prevalence around the world, including Indonesia. The high prevalence of malocclusion is in line with the increasing demand for orthodontic treatment[3].

The prevalence of malocclusion in Indonesia remains high at around 80% of the total population. Malocclusion is one of the major dental and oral health problems after dental caries and periodontal disease[4]. Malocclusions are the clinical manifestation of dentomaxillary abnormalities, the etiology is multifactorial and both hereditary factors and bad habits play a large role[5]. Malocclusion or irregular teeth in dental arch is a big problem for some individual since it caused mouth function problem, temporomandibular disorder, mastication, digestive and talking[6].

Corresponding author:
Noengki Prameswari.
Dentistry Faculty Hang Tuah University. Jl. Arif Rahman Hakim no 150 Surabaya. Indonesia.
E-mail: noengki.prameswari@hangtuah.ac.id

Expansion is one of procedure to expand the dental arch in sagittal plane or transversal plane. Dental arch widening can be done with orthodontics and very effective on mixing dentition, when the palatine suture are active [2].

Os Maxillary is the part of cranium[7]. Os maxillary connected to os palatum through the suture. The suture let the bone to expand and to contact with the other bone surrounding. The suture system makes the maxillary and the palatum move forward and downward to the cranium anterior basis as growing. The maxillary curve being taller and wider as growing, while maxillary palatum will be transversally bigger (the separating horizontal line between upside and downside) and sagittal (the separating line between right side and left side) since child till adult[8].

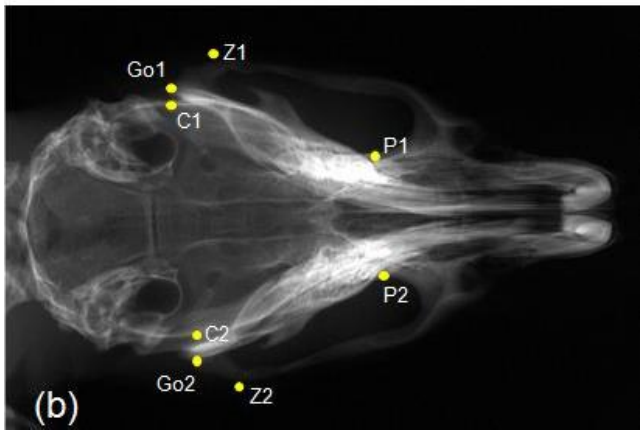

Figure 1. Location of cephalometric points on transverse radiograph.
C1-C2 : points on the skull which produce the widest skull width,
Go1-Go2 : the outermost point of the angulus mandible
Z1-Z2 : lateral point of zygomaticum called byzigomatic width;
P1-P2 : the most anterior and medial point in fossa.

Transverse craniofacial structures can be analyzed using cephalometric reference points. Orthodontic treatment commonly uses cephalometric radiography to describe the morphology and facial skeletal growth, predicting the growth, treatment planning and the evaluatin of the treatment[9]. At Rodentia cephalometric points with transverse sections, there are 8 points that can be observed and 6 of they are Go1, Go2, C1, C2, Z1, Z2, P1and P2 as seen as figure 1[1]. Transverse sizes of C1 and C2 on cephalometric radiographs are points on the skull which produce the widest skull width, also called cranial width. Go is an abbreviation of gonion, which is the meeting point between the most inferior border of the mandible with the most posterior border of the mandible or the ramus of mandible The transverse size of Go1 and Go2 on cephalometric radiography is the outermost point of the angulus mandible and made the largest width, also called bigonial width; also Z1 and Z2 as a lateral point of zygomaticum called byzigomatic width; and P1-P2 is the most anterior and medial point in fossa[10].

Cranial bone is one such constituent structure. Cranial bone is in essence a layered panel consisting of inner and outer tables of compact bone separated by a cancellous diploe. Layered beam theory is a mathematical model used to predict the mechanical responses of a layered panel material, such as cranial bone, from the properties and geometry of its constituent materials[11]. The change adaptation to mandibles occurs in the use of maxillary expansion appliances[12].

The Os Zigomaticum growth can be seen through Cephalometric analysis. The cephalometric picture (cephalogram) is an ordontic record which is very useful to determine skeletal disorder, tooth position, profile, and much more[13]. The lateral Cephalometry shows the anatomy structure of the head, face, and oral from the lateral perspective. Moreover, the structural reference point referred to the angle and distance measurement can be described in order to assess the growth pattern[14].

Stichopus Hermanni contains big bioactive materials, one of which is glycosaminoglycan[15]. Many previous researches show that glycosaminoglycans (GAG) sulphate, such as chondroitin sulphate and heparan sulphate, have a positive effect on the wound healing process[16]. According to previous studies, Stichopus Hermanni can increase number of fibroblasts that helps to prevent the tooth relaps after orthodontic treatment. The previous research results showed that using Stichopus Hermanni with 3% content is more effective rather than 2,5%[17]. The Stichopus Hermanni (with 3% in content) utilization in suture maxillary remodeling expansion on craniofacial structures and teeth have never been examined before, cephalometric analysis was used to analyzes it.

Materials and methods

The studies were kind of laboratory experimental, with research design completely

randomized control group post test only design. The experimental units are 24 male Cavia cobaya age 2-3 months. The samples taken using simple random sampling.

The tools used are cage and Cavia cobaya scales, Stichopus hermanii gel tube, Waring Commercial Model HGBTWT blender, incisive band, helical spring, separator rubber, 1 ml insulin syringe, Extraoral cephalometric radiographic tool Toshiba/D-051 type VATECH PaX-400C, glossy photo paper 200gms, calipers, ruler, tweezers, cotton pellet, scissor, sandpaper, electric oven, mortar and pestle, hotplate, scanner. The materials are Stichopus hermanni powder 100%, NaCMC 2% (Natrium Carboxymethyl Cellulose 2%), ketamine (0,033 mg/gr BB)-acepromazin (0,003mg/gr BB), glass ionomer cement type 1.

Figure 1: Helical spring (expansion appliance).

The Stichopus hermanii that had been dried for 6-7 days in 28°C with electric oven is blended to powder. The making process of Stichopus hermanii process is done in Hang Tuah University Biochemical Laboratory Surabaya. Stichopus hermanii powder as much as 0,3 gr is mixed with 0,2 gr NaCMC powder, then it is dissolved with 10 ml aquadest until we get Stichopus Hermanni with 3% concentration. The 2% NaCMC powder is obtained from mixing 0,2 gr NaCMC powder with 10 ml aquades using mortar and pestle on the hotplate.

Cavia cobaya is prepared and grouped into 4 groups, negative control group (K-), positive control (K+), 1st treatment (P1) , and 2nd treatment (P2). The K- group doesn't receive any treatment, K+ group is given expansive tool for 10 days dan NaCMC 2% powder start from 4th day since start. P1 group is given expansive tool for 10 days and Stichopus hermanii 3% powder start from the 4th day since start, while for group P2, it is given same treatment as P1 group and the retention period for 10 days and Stichopus Hermanni powder 3% for the period.

The separator rubber is applied to produce diastema between Cavia cobaya incisive to facilitate the incisive band appliance. The Stichopus Hermanni powder 3% and NaCMC 2% is injected using insulin syringe that is dulled, injected into Cavia cobaya incicive sulcus, 2 times a day with 0,025ml doze. Decapitation is done after treatment period finished, followed by placing the head and the jaw of Cavia cobaya in buffer formalin solution to prevent changes in specimen.

The Cephalometry radiography is done by putting the Cavia cobaya head on the photo surface lingually to the side direction (perpendicular to the light direction) and the head near ear rod cephalometric tool. The result is printed on the glossy photo paper 200 gsm, then scan it with increasing the contrast by 30% and 600dpi resolution. Scan result is processed using photoshop software to crop 8cm x 5cm (length x width) as the original size, then zoom it until 2 times by inputting 16 cm x 10 cm in image size menu. The analysis starts by determine the Cavia cobaya cephalometric reference points along with left and right gonion points position. Measure the craniofacial structures that consist of cranial width, bizigomatic width, bigonial width, and insisivi distance using ruler and record the result in cm unit.

Results

Measurement of craniofacial structures (cranial width, bizygomatic width, bigonial width), and insisivi distance average results.

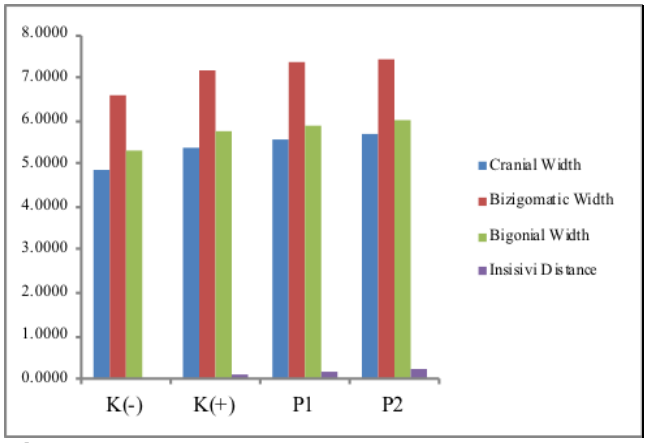

Figure 2. Histogram of mean measurement on cranial width, bizygomatic width, bigonial width, and insisivi distance Towards Stichopus hermanii gel giving on maxillary suture expansion remodeling using cephalometric analysis in K(-), K(+), P1, and P2.

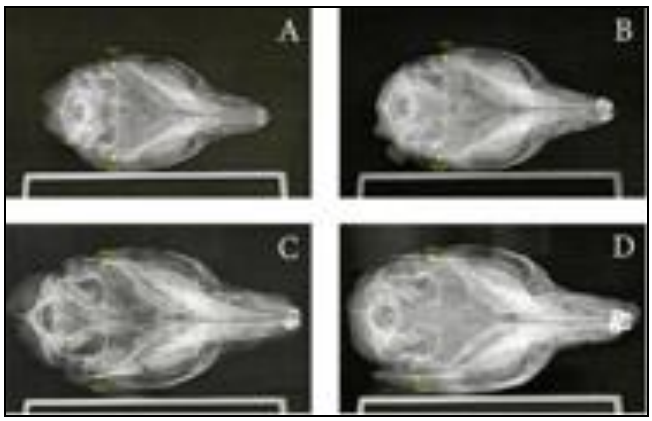

Figure 3. Results of the Cephalometric Image of the Cavia cobaya skull that consist of cranial width, bizygomatic width, bigonial width, and insisivi distance between groups of K (-) (in A section); with K (+) (in B section), groups P1 (C section) and P2 (D section).

Group	K(+)	P1	P2
K(-)	0.004*	0.000*	0.000*
K(+)		0.161	0.037*
P1			0.442

Table 1. Post Hoc LSD Result of Cranial Width. *There are significant differences

The result showed the largest cranial width was found ingroup P2 compared to the other control. The result of Post Hoc LSD test showed significant differences between K- and the other control (p<0,05), the K+, P1, and P2 had no significant differences (p>0,05)

Group	K(+)	P1	P2
K(-)	0.016*	0.003*	0.001*
K(+)		0.432	0.230
P1			0,667

Table 2 . Post Hoc LSD Result of Bizigomatic width. * There are significant differences

The result showed the largest bizigomatic width was found in group P2 compared to the other control. *One Way ANOVA* test showed significant differences (Sig=0,000). The result of *Post Hoc LSD* test showed significant differences between K- and the other control (p<0,05), the K+, P1, and P2 had no significant differences (p>0,05).

Group	K(+)	P1	P2
K(-)	0.004*	0.001*	0.000*
K(+)		0.422	0.094
P1			0.360

Table 3. Post Hoc LSD Result of Bigonial Width.
* There are significant differences

The results showed that the largest bigonial width was found in group P2 compared to the other control. One Way ANOVA test showed significant differences (Sig. = 0,000). The results of the LSD Post Hoc test showed significant differences between the K- groups and all other control (p <0.05), while the K +, P1, and P2 groups had no significant difference (p> 0.05).

Group	K(+)	P1	P2
K(+)		0.026*	0.000*
P1			0.048*

Table 4. Post Hoc LSD Result of Insisivi Distance * There are significant differences

The result showed that the largest bigonial width was found in group P2 compared to the other control. One Way ANOVA test showed significant differences (Sig. = 0,000). The results of the LSD Post Hoc test showed significant differences (p< 0,05) between the K+ groups and P2, P1 and K(+) , P1 and P2, all other control (p <0.05), while the K +, P1, and P2, P2 and K(+), and between P2 and P1.

Discussion

The results shown in Figure 2 show the difference in mean of cranial width, bizygomatic width, bigonial width, and insisivi distance between groups of K (-) with K (+), groups P1 and P2. Group K (-) is a negative group that is not given expansion appliance and is not treated. Group (+) is a positive group given expansion appliance. Group P1 is one treatment group which is given expansion appliances and Stichopus hermanni gel. Group P2 is a treatment group of two given expansion device and Stichopus hermanni gel is also given a retention period for 10 days. The expansion led to maxillary suture rupture in the suture area of palatina mediana[18]. Mechanical expansion of the sutura palatina mediana will cause soft tissue between the sutures to be necrosis[19].

Expansion produces a destructive process that causes the soft tissues of the sutures to be disturbed and edematous, accompanied by enlargement of blood vessels or bleeding[20]. A stretched suture will experience bleeding, necrosis and wound healing responses. A vascular invasion of a frozen blood clot in a stretched suture is a requirement for new bone formation. Following the process of vascularization, the spreading midpalatal sutura will produce new osteoblasts[21]. Osteoblasts synthesize bone matrix, especially collagen and regulate newly formed bone mineralization[22].

Previous studies on rapid maxillary expansion (RME) have a significant effect on zygomaticomaxillary suture and nasal bone, but not on frontozygomatic and frontomaxillary. RME shows high tension pressure in the zygomaticomaxillary, except along the anteromedial surface. The zygomaticomaxillary support is the main site of osteotomy in surgical expansion. Significant expansion studies on the zygomaticomaxillary can be seen in all groups which may be an indication of effective skeletal expansion to increase the maxillary curve width[23]. The reasoning behind rapid maxillary expansion is that the orthopedic forces exerted by the expansion appliance can, up to a certain age, open the mid-palatal suture and widen the palate and promote suture opening. In this research used helical spring as a slow maxillary expansion showed that appliance can increase the cranial width and insisivi distance but can't increase the bizygomatic and bigonial width, so that the expansion appliance only can expand in the small distance. The use of retension in this research give a role to maintain the result of expansion.

Stichopus hermanii is rich in growth factors that can repair damaged cells and protein that reaches up to 82% of all components of the stichopus hermanii, 80% of which is collagen[24]. Stichopus hermanni gel can accelerate the remodelling of teeth movement. The Stichopus hermanni is one of the sea creatures that provides high protein and it its proved to be nutritious[25], however the utilization in Indonesia is still rare.

Collagen plays a very important role at every stage of wound and bone healing process in suture opening. Collagen possesses many abilities such as homeostasis, interaction with platelets, interaction with fibronectin, increasing the fluid exudation, increasing cellular components, increasing the growth factors and encouraging the process of fibroplasia and sometimes on the epidermis proliferation[26]. Collagen also have role in stimulate VEGF. Platelets aggregate around exposed collagen. Platelets then secrete factors, which interact with and stimulate the intrinsic clotting cascade, which strengthens the platelet aggregate into a stable hemostatic "plug." inflammation. Cleavage products resulting from collagen degradation stimulate fibroblast proliferation. The collagen cleavage products also stimulate vascular endothelial cell proliferation[27].

The content of Stichopus hermanii is associated with increased thickness of collagen fibers in wound healing processes such as chondroitin sulphate and glycosaminoglycans. Chondroitin sulfate is able to bind to fibroblast growth factor-2 to trigger proliferation and adhesion of fibroblasts and increase the speed of wound closure in vitro. Fibroblasts are cells that play a role in the process of collagen synthesis, so the proliferation of fibroblasts directly affects the increase of collagen synthesis[28]. The content of Stichopus hermanni is also involved in the formation of collagen and elastic fibers, the movement of cells, the formation of basal membrane zone is glycosaminoglycans[29]. Collagen is part of the bone matrix. More than 90% bone matrix contains collagen to be formed into bone[27].

Glycosaminoglycans consist of hyaluronic acid (AH), chondroitin sulphate (KS), dermal sulfate (DS), heparin sulphate (HS), and heparin[30]. Hyaluronic acid has a complex role in cell proliferation[31]. Sulfate groups in chondroitin play a role in fibroblast proliferation chondroitin sulfat and and sulfate dermatan are bound to fibroblast growth factor-2 (FGF-2) and stimulate FGF-2 to induce cell proliferation[32]. Heparin may also accelerate the production and deposition of collagen[33]. Glycosaminoglycans also facilitated to regulate the differentiation and stimulation of osteoblast function through Smad 1/5/8 phosphorilation and Cbfa1 transcrition factor activity and also increase alkalin phosphatase activity[34].

The active phenolic component is contained in the walls of the Stichopus hermanni[35]. Phenolic components, especially flavonoids, result in the anti-oxidant properties of teripang[36] and anti-inflammatory IL-10 useful in

the health field. Flavonoids cause an inflammatory reaction that occurs as a result of the animal body's reaction to the pressure of the expansion tool can be reduced. Inflammation in the pressure zone will produce secreted IL-1 pro- and IL-6 proinflammatory cytokines as well as anti-inflammatory IL10. Then proceed with wound healing process. Flavonoid also have role in osteoblast differentiation through bone morphogenetic protein-2/extracellular signal-regulated kinase 1/2 Pathway and influence bone mass[37]. The benefits of wound healing Stichopus hermanni obtained from saponin content in the Stichopus hermanni[15].

The 10-day retention period enacted in this P2 group affects the average of cranial width, bizygomatic width, bigonial width, and insisivi distance. The result group P2 yields the largest average. Retention serves to hold the teeth in good positions and restore soft tissue to physiological conditions and compact bone structure after orthodontic treatment[13]. Retention in this study was undertaken in the hope that no bizigomatic shrinkage was observed after the previous helical spring activation. During the retention period, the gel application of Stichopus hermanni is still give in treatment group, so the effect of bioactive content of sea cucumber is still running.

The effect of the 3% Stichopus hermanii gel with the retension was seen in the average result indicated by each group. Group K (-) denotes the difference in weightedness to the K (+), P1, and P2 groups. This difference occurs because groups of K (+), P1, and P2 use expansion appliances, given Stichopus hermanni gel and given a retention period for 10 days.

In group K (+) did not have significant differences with group P1 and P2. The provision of Stichopus hermanni and a 10-day retention period is not strong enough to increase significant results in bizygomatic bigonial width. Groups P1 and P2 have larger mean result compared to K (+) groups. Stichopus hermanii function to increase wound healing[38], as well as increase and differentiation of osteoblast cells[39]. Increasing suture as new bone formed in cranial width parameter and insisivi distance showed in this research with Stichopus hermanni gel 3% application.

This research initiated with Stichopus hermanii gel on day 4 after the installation of an expansion appliance. There are three stages of bone deposition: (1) early phase of bone resorption (3-5 days), (2) reversal stage (5-7 days), and (3) final phase (7-14 days)[40], so that Stichopus hermanni application might be need more days to function.

Conclusions

According to the research we can conclude that 3% of Stichopus Hermanni's gel with a slow maxillary expansion showed that appliance can increase the cranial width and insisivi distance but can't increase the bizygomatic and bigonial width using cephalometric analyze, so that the expansion appliance only expanded in the small distance. The use of retension in this research give a role to maintain the result of expansion and give the best result.

Declaration of Interest

The author report no conflict of interest for this article

References

1. Abbassy MA, Watari I, Bakry AS, and Ono T. The Effect of Type 1 Diabetes Mellitus on the Dento-Craniofacial Complex. Intechopen. 2013: P50-51.
2. Sulandjari, H. Buku Ajar Ortodonsia 1 KGO 1. Yogyakarta: Universitas Gadjah Mada. 2008:6:47;60, 39-37,51-40,52-40.
3. Utari E, Krisnawati and Ismah N. Relationship between Orthodontic Treatment Outcome and Patient Satisfaction. Journal of International Dental and Medical Research. 2017: 10(specialissue): 503.
4. Purwanegara MK, Wulandari NNS and Purbiati M. Effect of Various Motivation Methods on Oral Hygiene Index Scores of Fixed Orthodontic Patients. Journal of International Dental and Medical Research. 2018:11(2): 390.
5. Figueroa FR, Bancalari C, Velásquez RC, Sanhueza M and Palma C. Prevalence of Malocclusion and its Psychosocial Impact in a Sample of Chilean Adolescents Aged 14 to 18 Years Old. Journal of International Dental and Medical Research. 2017:10(1): 14.
6. Susilowati and Sulastry. Korelasi Antara Lebar Mesiodistal Gigi Dengan Kecembungan Profil Jaringan Lunak Wajah Orang Bugis-Makassar. Dentofacial. 2007:2(6): 73.
7. Koesoemohardja HD, Indrawati A and Jenie I. Tumbuh Kembang Dentofacial Manusia. 2th ed. Jakarta: Universitas Trisakti.2008: 59-38.
8. Budiman JA, Hayati R, Sutrisna B, and Soemantri ES. Identifikasi bentuk lengkung gigi secara kuantitatif. Dentika Dental Journal. 2009:14(2): 120-4.
9. Nalcaci R, Ozturk F, and Sokucu O. A Comparison of Two-Dimensional Radiography and Three-Dimensional Computed Tomography in Angular Cephalometric Measurements. Dentomaxillofacial Radiology. 2010:39(2): 106-100.
10. Phulari, BS. An Atlas on Cephalometric Landmarks. 1th ed. New Delhi: Jaypee Brothers Medical Publisher. 2013: 93.
11. Hubbard RP. Flexure of layered cranial bone. Journal of Biomechanics. 1971: 4351-263.

12. Defraia E, Marinelli A, Baroni G, Tollaro I. Dentoskeletal Effects of a Removable Appliance for Expansion of the Maxillary Arch: A Postero-Anterior Cephalometric Study. European Journal of Orthodontics 2007:30(1): 60-57.
13. Rahardjo, P. Diagnosis Ortodontik. Surabaya: Airlangga University Press. 2011: 71.
14. Weems RA. Radiographic Cephalometry Technique. New Malden, Surrey: Publishing Co; 2006: 43-33.
15. Bordbar S, Anwar F and Sari N. High-Value Components and Bioactives from Sea Cucumber for Functional Food – A Review. Marine Drugs. 2011:9(10): 1805-1761.
16. Miller JD, Stevens ET, Smith DR, Wight TN, Wrenshall LE. Perlecan: A major IL-2-binding proteoglycan in murine spleen. Immunology Cell Biology. 2008:86(2): 192-9.
17. Rahardjo, C. Pengaruh Gel Teripang Emas Terhadap Jumlah Fibroblas di Daerah Tarikan pada Relaps Gigi setelah Perawatan Ortodonsi. Surabaya: Denta Jurnal Kedokteran Gigi. 2014:8(1) 34-42.
18. Muchitsch AP, Wendl B, Winsauer H, Pichelmayer M, and Payer M. Rapid Maxillary Expansion Screws on the Test Bench-a pilot study. European Journal of Orthodontics. 2010:33(3): 262-256.
19. Khrisnan V and Davidovitch Z. Biological Mechanisms of Tooth Movement. 2th ed. UK: John Wiley. 2015: 78.
20. Graber LW, Vanarsdall RL and Vig. Orthodontics: Current Principles and Techniques. 5th ed. Philadelphia: Mosby Elsevier.2012: 4.
21. Misch CE. Contemporary Implant Dentistry. 3th ed. Canada: Mosby Elsevier: 2008:585.
22. Thomas SDC. Bone Turnover Markers. Australian Prescriber. 2012:35: 158-156.
23. Kanomi R, Deguchi T, Kakuno E, Yamamoto TT and Roberts E. CBCT of Skeletal Changes Following Rapid Maxillary Expansion to Increase Arch-Length with a Development-Dependent Bonded or Banded Appliance. Angle Orthodontist. 2013:83(5): 857.
24. Arundina I, Suardita K, Setiabudi H and Ariani MD. *Stichopus hermannii* as Growth Factors of Stem Cells. Journal of International Dental and Medical Research. 2016:9(3): 243-242.
25. Prameswari N, Brahmanta A, Mulawarmanti D. Bone-immune interaction in osteogenesis Relapse Orthodontic after Nanopowder *Stichopus hermanii* Application. Journal of International Dental and Medical Research 2018:11(1): 323-329.
26. Rosdiani AF, Widiyanti P and Rudyarjo DI. Synthesis and Characterization Biocomposite Collagen-Chitosan- Glycerol as Scaffold for Gingival Recession Therapy. Journal of International Dental and Medical Research. 2017: 10(1):119.
27. Brett D. A Review of Collagen and Collagen-based Wound Dressings. Wounds**.** 2008:20(12): 347-56.
28. Au-Yeung GKC, Lu J, Moochhala SM, Bay B, and Yip GW. Pathology of Wound Healing: Chondroitin Sulfate Synthase 1 Regulates the Expression and Activity of Caspase 1. Proceedings of the World Medical Conference. 2011: 30-36.
29. Prameswari N, Prabowo PB. FGF-2, MMP-8 and Integrin α2β1 Expression in Periodontal ligament Remodelling Tension Area with Nanopowder Stichopus hermanii Application to Prevent Orthodontic Relapsing. International Journal of Materials Science and Applications. 2017: 6(6): 284-289.
30. Khan Al, Kerfoot SM, Heit B, et al. Role of CD44 and Hyaluronan in Neutrophil Recruitment. Journal Immunology. 2004:173: 7601-7594.
31. Marrigio MA, Cassano A, Vinella A, et al. Enhancement of Fibroblast Proliferation, Collagen Biosynthesis and Production of Growth Factors as a Result of Combining Sodium Hyaluronate and Amino Acids. International Journals of Immunopathology and Pharmacology. 2009:22(2): 492-485.
32. Zou XH, Foong WC, Caol T, Bay BH, Ouyang HW and Yip GW. Chondroitin Sulfate in Palatal Wound Healing. Journal of Dental Research. 2004:83(11): 885-880.
33. Durmus AS, Yaman M and Canet HN. Effect of Extractum Cepae, Heparin, Allantoin Gel and Silver Sulfadiaxin on Burn Wound Healing: An Experimental Study in a Rat Model. Veterinary Medicina. 2012:57(6): 292-287.
34. Ye Y, Hu W, Guo F, Zhang W, Wang J, Chen A. 2012.Glycosaminoglycan Chain of Biglycan Promote Bone Morphogenetic Protein-4- induced Osteoblast Differentiation. International Journal of Molecular Medicine. 2012:30(5): 1075-1079.
35. Esmat AY, Said MM, Soliman AA, El-Masry KSH, and Badiea EAB. Bioactive Compounds, Antioxidant Potential, and Hepatoprotective Activity of Sea Cucumber (Holothuria atra) against Thioacetamide Intoxication in Rats. Nutrition. 2012:30: 10-1.
36. Husni A, Shin IS, You SG, and Chung DH. Antioxidant Properties of Water and Aqueous Ethanol Extracts and Their Crude Saponin Fractions from a Far-eastern Sea Cucumber Stichopus japonicas. Food Science Biotechnology. 2009:18(2): 424-419.
37. Hsu YL, Liang HL, Hung CH, Kuo PL. Syringetin, a Flavonoid Derivative in Grape and Wine, induces Human Osteoblast Differentiation through Bone Morphogenetic Protein-2/Extracellular Signal-Regulated Kinase 1/2 Patway. Molecular Nutritional and Food Research. 2009:53(11): 1452-61.
38. Alawaiyah T and Sianita PP. Retensi dalam Perawatan Ortodonti. Jurnal Ilmiah dan Teknologi Kedokteran Gigi FKG UPDM. 2012:9(2): 35-29.
39. Masre SF, Yip GW, Sirajudeen KNS, and Ghazali FC. Wound Healing Activity of Total Sulfated Glycosaminoglycan (GAG) from *Stichopus vastus* and *Stichopus hermanni* Integumental Tissue in Rats. International Journal of Molecular Medicine and Advance Sciences. 2010:6(4): 53-49.
40. Shahrulazua A, Samsudin AR, Iskandar MA, and Amran AS. The IN-Vitro Effects of Sea Cucumber (*Stichopus sp1*) Extract on Human Osteoblast Cell Line. Malaysian Orthopaedic Journal. 2013:7(1): 48-41.
41. Kaya FA, Arslan SG, Kaya CA, Arslan H, and Hamamci O. The Gingival Crevicular Fluid Levels of IL-1β, IL-6, and TNF-α in Late Adult Rats. International Dental Research. 2011;1: 12-7.