Accuracy of Digital Periapical Radiography and Cone Beam Computed Tomography for Evaluation of Root Canal Configuration in Human Mandibular first Premolars

Phiangfah Kongkiatkool[1], Peraya Puapichartdumrong[1]*, Weeraya Tantanapornkul[2], Thosapol Piyapattamin[3], Kessiri Wisithphrom[1]

1. Department of Restorative Dentistry, Faculty of Dentistry, Naresuan University.
2. Department of Oral Diagnosis, Faculty of Dentistry, Naresuan University.
3. Department of Preventive Dentistry, Faculty of Dentistry, Naresuan University.

Abstract

To compare the accuracy of digital periapical radiography (DPR) and cone beam computed tomography (CBCT) in evaluating the root canal configuration (RCC) of mandibular first premolars by using a clearing technique (CLT).

122 extracted human mandibular first premolars were radiography by DPR and CBCT, then cleared and stained. All radiographs were interpreted by three evaluators, who classified the RCC by using Vertucci's classification. All interpreted data from DPR and CBCT were statistically compared with CLT by using a chi-square test at a significance level of $\alpha = 0.05$.

Post-analyses of the RCC's percentages of correct identifications by three techniques, chi-square test revealed no significant difference (P = .156) between CBCT and CLT, but with some significant differences (P = .000) between DPR and CLT, together with those between DPR and CBCT (DPR = 94.26% and CBCT = 98.36% in the overview; and DPR = 76.67% and CBCT = 93.33% in the teeth with two root canals). For those with single root canal, no significant difference among three techniques was observed.

CBCT gave as accurate evaluations of the mandibular first premolars' RCC as CLT, while DPR provided the least accuracy.

Experimental article (J Int Dent Med Res 2020; 13(1): 80-85)

Keywords: CBCT, Digital periapical radiography, Mandibular first premolar, Root canal configuration.

Received date: 19 May 2019 **Accept date:** 03 July 2019

Introduction

Basic knowledge on root canal morphology is important to endodontic treatment. The accuracy of identification, thorough debridement, shaping, and filling the root canal system are required for a successful endodontic therapy. In human dentition, mandibular first premolar is a tooth with the most complex internal anatomies, due to a high prevalence of multiple canals that join and separate at different levels of root[1] and the lingual canal is often divided from the buccal canal with a sharp angle that is difficult to access.[2] Moreover, its C-shaped root canals have been found.[3,4] Such variations may cause failure in the treatment.[5]

Root canal morphology can be seen by several methods, including direct observation under a microscope,[6] sectioning and macroscopic observation,[7] conventional or digital radiography,[8] micro-computed tomography,[3] and cone beam computed tomography (CBCT),[9] canal staining and tooth clearing technique (CLT)[10] claimed in some researches[10,11] to be the gold standard. Its advantages are consisted of a three-dimensional view, high accuracy, simplicity, convenience, inexpensiveness, and non-invasiveness.[12]

Instead of conventional radiography, digital periapical radiography (DPR) is commonly used in root canal treatment currently. Apart from an image enhancement, it reduces radiation dose,[13] chemical handling, and digital data storage.[14] When the root canal morphology needs to be identified, a usage of two-dimensional radiography and an alteration of the horizontal angulation for the extra root canals

***Corresponding author:**
Peraya Puapichartdumrong,
Department of Restorative Dentistry, Faculty of Dentistry, Naresuan University,
Amphoe Muang, Phitsanulok Province 65000, Thailand
E-mail: perayap@nu.ac.th

with a buccolingual alignment can be useful. To separate the mandibular first premolar's canals, some report has recommended a 20° mesial shift in the horizontal plane of the X-ray tube head.[15] By using the tube-shift method with a horizontal angulation between 20° and 30° to find the mandibular first premolar's multiple root canals, some different angulations of the preoperative radiographs have been reported to increase the detection rate.[16] With a placement on the stand with a circular goniometer, the mandibular first premolar's root canal numbers could be best revealed by a 40° horizontal angulation, when compared to those by 0° and 20° angulations.[8]

A structure with a three-dimensional anatomy generally appears superimposed on a two-dimensional DPR image. Despite its provision of three sectional planes (axial, sagittal, and coronal) and reduction of the surrounding structures' superimpositions, CBCT is expensive and has a scattering artifact, together with higher radiation dose.[17] Because of some complexities of the mandibular first premolar's RCC, an accurate method for finding all extra root canals is important and challenging. The appropriate one enables a better endodontic treatment, resulting in a good prognosis. In spite of numerous comparisons with other techniques in RCC researches,[10, 18] CBCT compared with DPR in mandibular first premolars, particularly at a 40° horizontal angulation has never been reported. Hence, the objective of this study was to compare the accuracy of DPR and CBCT in evaluating the mandibular first premolars' RCC by using CLT. In addition, cadaver's mandible and a film holder with adjustable aiming rod angle (0°, 20°, and 40°) were used to enable more clinical tooth alignment and to guide an x-ray cone angulation, respectively.

Materials and methods

The study protocol was approved by the Ethics Committee (IRB Number 0226/61, Expedited Review). Human mandibular first premolars (N = 122) with complete root formations extracted to serve an orthodontic purpose were collected from private dental clinics. Exclusion criteria were those with dental caries, wear, crack, fracture, resorption, calcification, or restoration. All teeth included in this study were cleaned and stored in 10% formalin until use.

A human cadaver's mandible was obtained from Khon Kaen University, Thailand. The teeth were mounted in the prepared alveolar sockets to simulate a natural alignment. Post radiography by using DPR and CBCT, all samples were cleared and stained, respectively. Pre-commencement of the radiographic interpretations, three evaluators (an endodontist, a radiologist, and a postgraduate student) were calibrated three times with a 1-week interval using 10% of all samples. Intra- and inter-examiner agreements were verified by the Cohen's kappa statistics. All images were interpreted twice by the evaluators (except the radiologist) with a 1-week interval between each conduction. In case of any disagreement, the radiologist made the final decision.

Radiography of the mandible with the teeth was conducted with a digital x-ray unit (Myray; Cefla Dental Group, Imola, Italy) and an image plate plus size 2 (Dürr Dental AG, Bietigheim-Bissingen, Germany) at 65 kVp, 6 mA, 1 s exposure time. Three radiographs were taken in a buccolingual direction with 0° and 40° mesial- and distal-tube shifts, with an additional usage of a film holder (NU-Rayshift; Naresuan University, Thailand). The images were processed in a VistaScan Mini processor (Dürr Dental AG) and observed on an LCD monitor (Acer; Guangdong, China). According to Vertucci's classification,[19] RCC were classified into eight types by the two evaluators.

With a 0.5 mm-slice thickness, CBCT were scanned by a Veraview X800 (J. Morita, Kyoto, Japan). At 90 kVp, 5 mA, and 9.40 s, a voxel size of 0.125 mm and 8×8 cm field of view were used. The teeth were viewed on axial, coronal, and sagittal planes on the LCD monitor with high resolution, allowing each evaluator to modify angulation or contrast according to individual preference. RCC were then classified into the eight types, according to Vertucci's classification.

After an access-opening procedure through the occlusal surface had been performed, the root canal was identified and negotiated through the apical foramen with a #10 K-file (Dentsply, Ballaigues, Switzerland). The teeth were then immersed in 5.25% sodium hypochlorite for 12 h and washed by tap water run for 4 h. Clearing and staining the teeth described elsewhere[12] were adopted, followed by a decalcification in 5% nitric acid and an agitation

by hand twice a day. Post-determination of the decalcification's end-point by using a needle method, the teeth were rinsed by tap water run for 4 h and dehydrated in ascending grades of ethanol. The teeth were placed in methyl salicylate (Loba Chemie, Mumbai, India) for 2 h, until transparent and glass-like appearance was observed. By using a centralized vacuum system (Gibthai, Bangkok, Thailand), India ink (Kenton Intertrade, Bangkok, Thailand) for staining the root canal system was injected into the pulp chamber proper and drawn through the root canal system with an application of a negative pressure at the apical foramen. All teeth's RCC were examined under a surgical microscope (OPMI PROergo; Zeiss, Jena, Germany) by the evaluators.

Statistical analysis

By conversions of the data from Vertucci's classification to 0 and 1 designated as the incorrect and the correct data, respectively, all interpreted images from DPR and CBCT were statistically compared with CLT. By using an SPSS Version 23.0 (IBM, NY, USA), statistical analyses were performed using a chi-square test at a significance level of α = 0.05.

Results

Table 1 shows RCC's types detected by DPR and CBCT, when compared to those with CLT and Table 2 the correct identifications described in percentage of RCC detected by the three techniques. Images of mandibular first premolar with two root canals are shown in Figures 1 and 2.

RCC type	CLT	CBCT	DPR
I (1)	92 (75.41 %)	93 (76.23 %)	99 (81.15 %)
II (2-1)	0	0	0
III (1-2-1)	5 (4.10 %)	6 (4.92%)	2 (1.64%)
IV (2)	0	0	0
V (1-2)	23 (18.85 %)	22 (18.03 %)	21 (17.21 %)
VI (2-1-2)	0	0	0
VII (1-2-1-2)	2 (1.64 %)	1 (0.82%)	0
VIII (3)	0	0	0

Table 1. Distributions of root canal configurations (RCC) by using Vertucci's classification among clearing technique (CLT), digital periapical radiography (DPR), and cone beam computed tomography (CBCT).

Method	Total	One-canal	Two-canals
CLT	100*	100	100*
CBCT	98.36*	100	93.33*
DPR	94.26†	100	76.67†

Different superscripted symbols in the same column indicate statistically significant differences at $P < 0.05$.

Table 2. Correct identifications (percentage) of root canal configurations among clearing technique (CLT), digital periapical radiography (DPR), and cone beam computed tomography (CBCT).

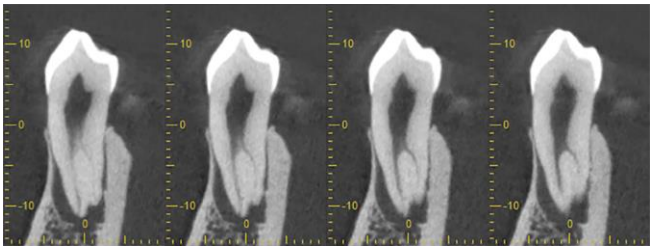

Figure 1. CBCT showing a coronal section of mandibular first premolar with type V canal determined by Vertucci's classification and the separation of its buccal and lingual root canals with a sharp angle.

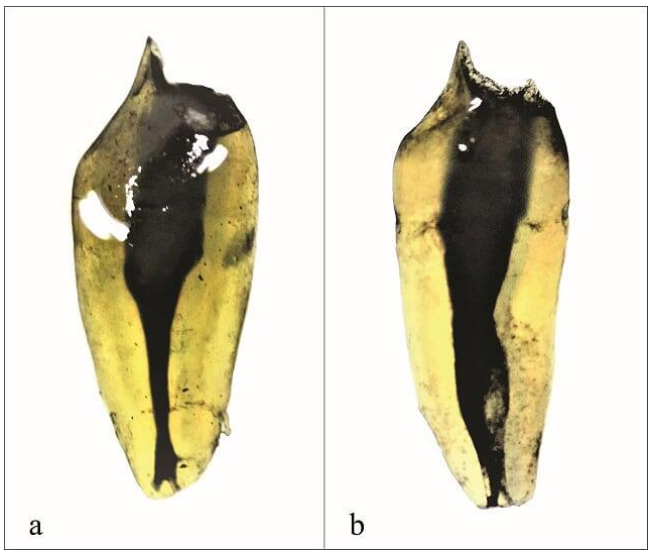

Figure 2. Proximal views of Vertucci's canal types V (a) and VII (b) of the teeth undergone a clearing technique.

After the correct identifications (in percentage) of the RCC by three techniques were analyzed, the chi-square test revealed their non-significant difference (P = .156) between CBCT and CLT, but with some significant differences (P = .000) between DPR and CLT,

together with those between DPR and CBCT (in the overview and in the teeth with two root canals). For those with single root canal, no significant difference among three techniques was observable. By using DPR, misidentifications of the RCC were mostly found in type VII, followed by types III and V, respectively. By using CBCT, type VII was classified as type III and type V as type I.

Table 3 shows intra- and inter-examiner agreements for the detections of RCC by three methods. The obtained results indicated very good agreements among all techniques (kappa values > 0.81 for all assessments).

Method	Intra-examiner			Inter-examiner
	Examiner #1	Examiner #2	Examiner #3	
CLT	1.00	1.00	1.00	1.00
CBCT	0.90	0.91	0.90	0.94
DPR	0.91	0.83	0.91	0.89

Table 3. Intra- and inter-examiner agreements for the detections of root canal configurations among clearing technique (CLT), digital periapical radiography (DPR), and cone beam computed tomography (CBCT).

Discussion

Accuracy of the identification methods to determine the RCC is important, because a successful endodontic therapy is involved with knowledge on root canal morphology to gain access and debridement. The present results found that 75.4% and 24.6% of human mandibular first premolars possessed one and two root canals, respectively. In the latter, the lingual canal was often deviated from the buccal one at a sharp angle (Figure 1), causing it to be difficult for an access. Their configuration has been reported to look similar to a lowercase "h". The straight line part of the 'h' was the buccal canal, while the lingual canal was deviated from the buccal one about mid-root at a sharp angle.[2] Consequently, the opening requires sufficient flaring in the buccolingual direction to provide an access into the lingual canal.

Because of their simplicity and provision of the root canal system's accurate three-dimensional view, the canal staining and CLT were the gold standards in this study. Due to its larger particle size (10 μm)[20] than those of dentinal tubules,[21] India ink was used to deliberately identify only the main canal. Since the tubules were unpenetrated by the ink, research interpretations were easy and unquestionable. These were supported by the kappa values for CLT, both intra- and inter-examiner agreements, revealing very good agreements among all values.

By using DPR with a 40° horizontal angulation, correct identifications were 94.26% of all samples. Despite some significant differences from CLT and CBCT, DPR with such angulation revealed some higher percentage of correct identifications than those in other research.[22] In addition, DPR helped to provide 100% and 76.67% correct identifications of RCC type I and other types, respectively. Periapical radiography has been documented to misdiagnose almost all RCC types, except type I.[22] An alteration of our horizontal angulation might contribute to such higher results of correct identifications in teeth with two root canals. The most frequent misinterpretations in this study were seen in RCC type VII, followed by types III and V, respectively. RCC with some complexities or irregularities may be divided by or joined with a very acute angle, or contained a very small divided canal. When combined with a low resolution, a superimposition, or some anatomical noise of periapical radiograph's two-dimensional structures,[23] some identifications of such RCC may be unsuccessful.

Periapical radiography's different horizontal angulations may be affected by intra-arch dental positions, root's angle, or canal separation. The mesial shift with a 20° horizontal angulation has been reported the best for identifying the mandibular first molar's four canals.[24] Mandibular first premolar is naturally located at mandible's arc. In addition, RCC of that with a two-canal type is separated at an acute angle.[2] Hence, a greater horizontal angulation is necessary for separating its multiple canals lining up in a buccolingual direction. Nonetheless, some interpretations possibly turned difficult, due to a greater degree of angulation from radiographic distortion. In this study, such distortion was often observed in the image obtained from a distal-shift, particularly at canines, because of the tooth's position in the arc. Some alteration of a periapical radiograph's horizontal angulations resulted in a better identification of root canal morphology. It suggested some further investigations into

optimal horizontal angulations for other teeth at different positions on maxilla and mandible.

With its advantage over the two-dimensional radiographs on eliminating the surrounding structures' superimposition, CBCT has been used to reconstruct the three-dimensional images. Our results of a non-significant difference in the detections of RCC between CLT and CBCT correspond well with those in some researches.[10, 18, 25] However, two specimens were misinterpreted and RCC type VII was classified as type III by CBCT. In human mandibular first premolar undergone CLT, a wide single canal was found to extend from its pulp chamber proper, divide and re-join within the root's body, and re-divide into two separate canals adjacent to the apex (Figure 2b). CBCT images were unable to reveal such canal's re-divided part, probably due to the divided part being covered by the fusion part in the same CBCT section. RCC type V was classified as type I by CBCT and this was consistent with those in previous investigation.[22] A single canal observed in this tooth leaves the pulp chamber proper and divides into two separate canals near the root apex with separate apical foramina (Figure 2a). CBCT images were unable to identify the lingual one, possibly due to the canal's smaller diameter than CBCT's voxel size. Moreover, the scanned images' noise from the surrounding hard tissues may contribute to some effects and misinterpretations.[25]

CBCT provided more accurate identifications of RCC than DPR. In addition, its images portrayed the variants of internal anatomy including root canal shape, fin, and isthmi. Using a CBCT will assist an endodontist in improving diagnoses, treatment planning, and outcomes. However, it has not yet been recommended for routine endodontic diagnosis or screening, because of its high radiation dose. For this reason, it is suggested that the periapical radiography with a 40° horizontal angulation is necessary to identify the mandibular first premolar's RCC for pre-operative assessment of its anatomy. In case that periapical radiography shows some doubtful extra canals or a complex morphology, CBCT should be used for further clarifications.

Conclusions

CBCT was accurate as CLT in evaluating the RCC of human mandibular first premolars, whereas DPR was less accurate than both CBCT and CLT.

Acknowledgements

This study was supported by the Research Funds for graduate students from Faculty of Dentistry, Naresuan University.

Declaration of Interest

The authors declare no conflict of interest.

References

1. Cleghorn BM, Christie WH, Dong CC. The root and root canal morphology of the human mandibular first premolar: a literature review. J Endod. 2007;33(5):509-16.
2. Endodontic and clinical considerations in the management of variable anatomy in mandibular premolars: a literature review. Available at : "https://www.hindawi.com/ journals / bmri / 2014 / 512574 / ". Accessed December 10, 2017.
3. Alkaabi W, AlShwaimi E, Farooq I, Goodis HE, Chogle SM. A micro-computed tomography study of the root canal morphology of mandibular first premolars in an Emirati population. Med Princ Pract. 2017;26(2):118-24.
4. Yang H, Tian C, Li G, Yang L, Han X, Wang Y. A cone-beam computed tomography study of the root canal morphology of mandibular first premolars and the location of root canal orifices and apical foramina in a Chinese subpopulation. J Endod. 2013;39(4):435-8.
5. Lin LM, Skribner JE, Gaengler P. Factors associated with endodontic treatment failures. J Endod. 1992;18(12):625-7.
6. Schwarze T, Baethge C, Stecher T, Geurtsen W. Identification of second canals in the mesiobuccal root of maxillary first and second molars using magnifying loupes or an operating microscope. Aust Endod J. 2002;28(2):57-60.
7. Lu TY, Yang SF, Pai SF. Complicated root canal morphology of mandibular first premolar in a Chinese population using the cross section method. J Endod. 2006;32(10):932-6.
8. Martínez-Lozano MA, Forner-Navarro L, Sánchez-Cortés JL. Analysis of radiologic factors in determining premolar root canal systems. Oral Surg Oral Med Oral Pathol Oral Radiol Endod. 1999;88(6):719-22.
9. Abdulmajeed KR, Mustafa NS, Kashmoola MA, Jabbar OA, Razak LSA, Noor SNM. The diagnosis and determination of C-shaped canal in lower second molar. J Int Dent Med Res. 2018;11(3):810-8.
10. Neelakantan P, Subbarao C, Subbarao CV. Comparative evaluation of modified canal staining and clearing technique, cone-beam computed tomography, peripheral quantitative computed tomography, spiral computed tomography, and plain and contrast medium-enhanced digital radiography in studying root canal morphology. J Endod. 2010;36(9):1547-51.
11. Moshfeghi M, Sajadi SS, Sajadi S, Shahbazian M. Conventional versus digital radiography in detecting root canal type in maxillary premolars: an in vitro study. J Dent (Tehran). 2013;10(1):74-81.
12. Robertson D, Leeb IJ, McKee M, Brewer E. A clearing technique for the study of root canal systems. J Endod. 1980;6(1):421-4.
13. Mouyen F, Benz C, Sonnabend E, Lodter JP. Presentation and physical evaluation of RadioVisioGraphy. Oral Surg Oral Med Oral Pathol. 1989;68(2):238-42.
14. Christensen GJ. Why switch to digital radiography? J Am Dent Assoc. 2004;135(10):1437-39.

15. Walton RE. Diagnostic Imaging. In: Ingle JI, Bakland LK, Baumgartner JC, eds. Ingle's Endodontics. 6th ed. Ontario, Canada: BC Decker; 2008:554-99.
16. He BZ, Wang H, Yin XZ, Wang QQ, Zhang C. Clinical evaluation of different angulation radiograph in diagnosing multiple canals of mandibular first premolars in vivo. Hua Xi Kou Qiang Yi Xue Za Zhi. 2007;25(2):156-8.
17. Patel S, Durack C, Abella F, Shemesh H, Roig M, Lemberg K. Cone beam computed tomography in Endodontics – a review. Int Endod J. 2015;48(1):3-15.
18. Domark JD, Hatton JF, Benison RP, Hildebolt CF. An ex vivo comparison of digital radiography and cone-beam and micro computed tomography in the detection of the number of canals in the mesiobuccal roots of maxillary molars. J Endod. 2013;39(7):901-5.
19. Vertucci F, Seelig A, Gillis R. Root canal morphology of the human maxillary second premolar. Oral Surg Oral Med Oral Pathol. 1974;38(3):456-64.
20. Ahlberg KM, Assavanop P, Tay WM. A comparison of the apical dye penetration patterns shown by methylene blue and india ink in root-filled teeth. Int Endod J. 1995;28(1):30-4.
21. Lenzi TL, Guglielmi Cde A, Arana-Chavez VE, Raggio DP. Tubule density and diameter in coronal dentin from primary and permanent human teeth. Microsc Microanal. 2013;19(6):1445-9.
22. Sousa TO, Haiter-Neto F, Nascimento EHL, Peroni LV, Freitas DQ, Hassan B. Diagnostic accuracy of periapical radiography and cone-beam computed tomography in identifying root canal configuration of human premolars. J Endod. 2017;43(7):1176-9.
23. Patel S, Dawood A, Whaites E, Pitt Ford T. New dimensions in endodontic imaging: part 1. Conventional and alternative radiographic systems. Int Endod J. 2009;42(6):447-62.
24. Zhang LD, Chen XW, He Y, Han JL, Wang HN. Evaluation of X-ray beam angulation for successful four canals identification in the mandibular first molars. Shanghai Kou Qiang Yi Xue. 2010;19(4):354-8.
25. Zhang D, Chen J, Lan G, et al. The root canal morphology in mandibular first premolars: a comparative evaluation of cone-beam computed tomography and micro-computed tomography. Clin Oral Investig. 2017;21(4):1007-12.