Analysis of Accessory Canals as Important Anatomical Structures in the Anterior Maxilla with Cone Beam Computed Tomography

Zurab Khabadze[1], Ferdaus Taraki[1], Oleg Mordanov[1]*, Saida Abdulkerimova[1], Yusup Bakaev[1], Mariam Shubitidze[2], Shamil Solimanov[2], Shamil Nazhmudinov[2]

1. Department of Therapeutic Dentistry, RUDN university, Medical institute Moscow, Russia.
2. Private practice, Moscow, Russia.

Abstract

The aim of this study is to analyze the diameter and localization of terminal part CS to prevent its damage during implant placement in the anterior maxilla.

150 CBCT scans of 61 males and 89 females in the age span of 24 to 80 years using 8 x 8 field of view. were analyzed in Ez3D2009 (Vatech) software on panoramic and cross-sectional views with 0.5mm, 1mm, 3 mm and 10 mm slice thickness. The CS visualization was graded with the four-point rating scale and the localization was distributed according to Oliveira-Santos.

Evaluating CBCT scans with 0.5 mm slice thickness the alveolar process part of CS was evident in 101 of 150 patients (67% of total patients). 22 of these 101 patients (21.7%) presented with CS on the right side, 32 (31.6%) patients on the left side and 47 (46.7%) patients on both sides.

Most frequently CS was localized in the lateral incisor region (33.5%, n=50).

Analyzing CBCT scans with 0.5 mm and 1 mm slice thickness on both sides CS was visualized in 49%, with 3 mm slice thickness in 40% and with 10 mm slice thickness in 18%. Mean diameter and length of terminal part CS were 0,95 ± 0,24 and 11,78 ± 3,32 consequently.

CS was located palatally in 76% (n=113), centrally in 12% (n=18) and buccally in 12% (n=18).

It is important to plan dental implant placement with CBCT and by not neglecting the use of surgical guides.

Clinical article (J Int Dent Med Res 2020; 13(1): 162-165)

Keywords: Canalis sinuosus, anterior maxilla, dental implant placement, cone-beam computed tomography, anterior superior alveolar nerve.

Received date: 20 May 2018 **Accept date:** 03 September 2019

Introduction

The anterior maxilla is considered to be a difficult clinical region due to high esthetical and functional demands. One of the key stages of evaluating an edentulous ridge prior to dental implant placement is the analysis of neighbouring anatomical structures [1]. In the anterior maxilla one of such structures is canalis sinuosus [2,3,4].

Canalis sinuosus (CS) is an intrabony structure which carries anterior superior alveolar neurovascular bundle[1]. It begins on the infraorbital canal behind the homonymous foramen and goes to the anterior-lateral direction. After the canal reaching the anterior wall of the maxilla it turns medially and goes along the lateral wall of the nasal cavity [5]. Some authors call the terminal part of CS, residing in the alveolar process of maxilla, differently: continuation of the CS [1,6,7], the accessory canal of the CS [5,8] or lateral incisive canal [9] (Fig. 1)

It is important to note that terminal part of CS or accessory canals may locate in three directions: palatal, central and buccal [1,5,8,10].

Damage of this canal during implant placement can lead to a range of complications such as bleeding and sensory disturbances [1,8]. For example, Arruda et al. presented the description of the clinical case, where a 51 year-old woman suffered from paresthesia for 22 months after dental implant placement in the maxillary lateral incisor region. CBCT scan analysis revealed that the implant was placed into the CS, that led to pain and sensory disturbance in the upper lip region on the right side [11]. There are other clinical reports describing the appearance of pain after dental implant placement with CS damage[8].

Corresponding author:
Oleg Mordanov
107140, Russia, Moscow, Verhnyaya Krasnoselskaya street 19/2 – 105.
E-mail: mordanov19@gmail.com

The aim of this study is to analyze the diameter and localization of terminal part CS to prevent its damage during implant placement in the anterior maxilla.

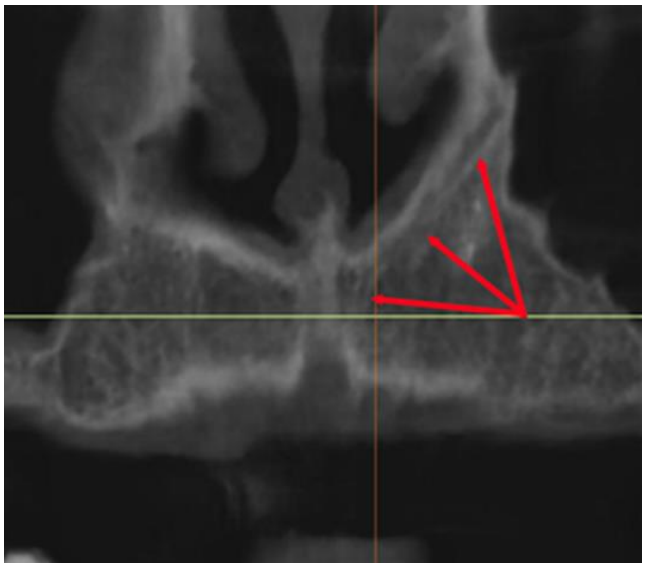

Figure 1. Panoramic view CBCT, CS is visualized in the lateral wall of nasal cavity, passing through maxillary alveolar crest.

Materials and methods

150 CBCT scans of 61 males and 89 females in the age span of 24 to 80 years using 8 x 8 field of view were analyzed in Ez3D2009 (Vatech) software on panoramic and cross-sectional views with 0.5mm, 1mm, 3 mm and 10 mm slice thickness. The CS was identified according to its anatomical description in the literature [8]. The localization was distributed according to Oliveira-Santos et al. classification (Fig. 2).

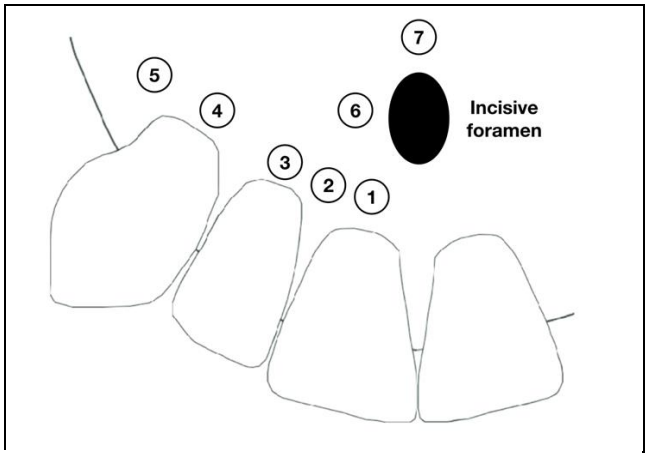

Figure 2. Schematic localization of CS according to Oliveira-Santos et al. (1- central incisor region, 2- region between the central and lateral incisors, 3- lateral incisor region, 4 - canine region, 5 - first premolar region, 6 -lateral to incisive foramen, 7 - posterior to incisive foramen)

The statistical analysis was provided with the Mann-Whitney U-test ($p<.01$ considered as statistically significant).

Results

Evaluating CBCT scans with 0.5 mm slice thickness the alveolar process part of CS was evident in 101 of 150 patients (67% of total patients). 22 of these 101 patients (21.7%) presented with CS on the right side, 32 (31.6%) patients on the left side and 47 (46.7%) patients on both sides.
In total 148 CS were identified on both sides with 0.5 mm slice thickness (49.6% of 300 sides evaluated in 150 patients). 46.3% of CS were visualized on the right side and 53.7% were visualized on the left side consequently.
Visualization (%) of the CS on CBCT scans with different slice thickness is shown in total on Figure 3.

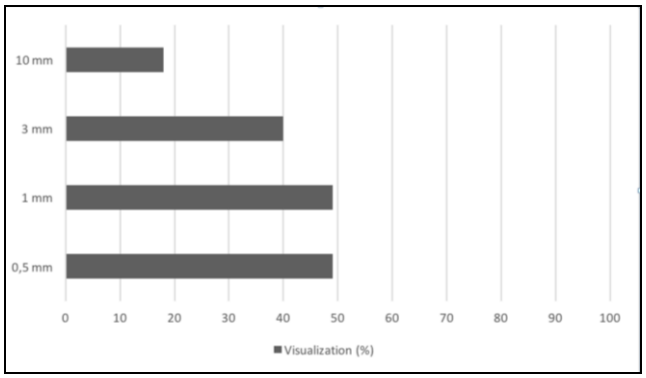

Figure 3. Visualization of CS in the right or/and left maxilla depending on thickness of section.

CS according to Oliveira-Santos et al [12] was more often localized in the lateral incisor region (33.5%; n=50), following by central incisor (24,2 %; n=36), canine region (21,5%; n=32), between central and lateral incisors region (10,7%; n=16), first premolar region (9,4%; n=14) and lateral to incisive foramen (0,7% n=1)

Analysis of diameter and length of the alveolar ridge part of the CS is demonstrated in Tables 1 and 2.

	Mean (mm)	Minimal (mm)	Maximal (mm)	U-test
Total	0,95 ± 0,24	0,3	2,1	
Female	0,94 ± 0,13	0,46	2,1	P=.6
Male	0,97 ± 0,22	0,3	1,7	

Table 1. Mean, maximal and minimal values of the diameter of CS residing in the maxillary alveolar process.

	Mean (mm)	Minimal (mm)	Maximal (mm)	U-test
Total	11,78 ± 3,32	2,42	21,54	
Female	11,3 ± 3,48	2,42	21,54	P=.8
Male	12,57 ± 2,8	6	20,85	

Table 2. Mean, maximal and minimal values of the length of CS residing in the maxillary alveolar process.

Then we evaluated 149 visualized CS in regard to its location in the alveolar process. We established that 76% of the CS had palatal location, and both central and vestibular locations were identified in 12% consequently (Fig. 4 a,b,c). This data is demonstrated in Table 3.



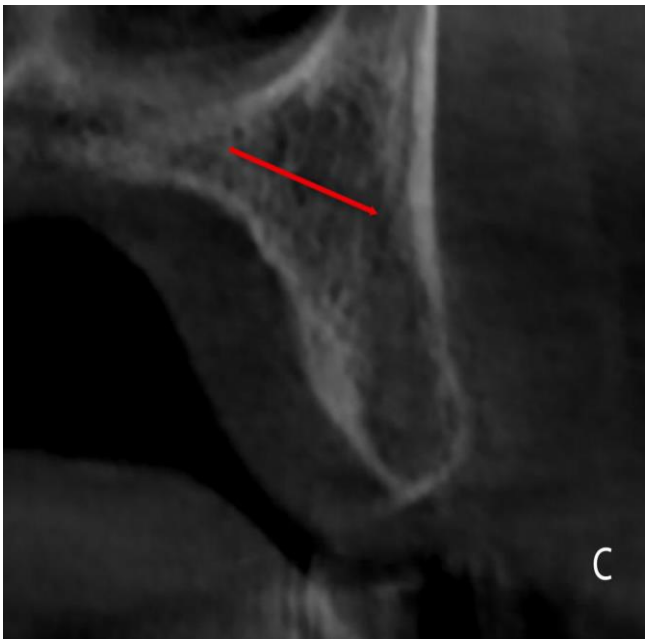

Figure 4. Visualization of CS depending on location: a – palatal location; b – central and c- buccal locations.

CS location	Palatal	Central	Vestibular
Number	113	18	18
%	76%	12%	12%
U-test	P<.01		

Table 3. CS location in the alveolar process.

Discussion

Canalis sinuosus was first described by Wood-Jones in 1939. Von Arx et al. established that more than a half of accessory canals in maxilla are connected with this structure [9]. A range of studies and clinical cases showed that the best visualization technique of this structure is CBCT [6,7,8,9,11,12].

Our 150 CBCT scan analysis demonstrated that the CS was located more often in the central incisor region, the lateral incisor region and the canine region, and it didn't have anastomosis with the nasopalatal canal.
The importance of the diagnostic slice thickness should be mentioned. CS was visualized equally good with 0.5 mm and 1 mm slice thickness and it was enough to define its sizes. Qualitative and quantitative evaluation of visualization rates of the canal decreased with 3 mm and 10 mm slice thickness.

In average the measurements of CS diameter and length was higher in men than in women. The more diameter is, the better visualization is and the less the safety zone for surgery. Consequently, these features should be taken in count to prevent CS damage.

While dental implant planning one more nuance is defining canal location in vestibule-palatal direction, because implant basically placed in the available volume of the alveolar ridge. As a result, it can lead to implant placement in the CS with possible complications.

Conclusions

Awareness of this anatomical structure plays an essential role in the dental implant planning. Damage of CS can cause the patient discomfort in the form of various symptoms, and consequently waste of time on various specialists in finding out the etiology of symptoms.

It is important to plan dental implant placement with CBCT and by not neglecting the use of surgical guides.

At the moment, we are conducting CS analysis in regard to the age and morphological features in different locations of the CS.

Declaration of Interest

The authors report no conflict of interest and the article is not funded or supported by any research grant.

References

1. Len Tolstunov. Horizontal Alveolar Ridge Augmentation in Implant Dentistry: A Surgical Manual. Wiley-Blackwell. February 2016 – 320
2. Williams P. L., Warwick R., Dyson M., et al. *Gray's Anatomy*. 37th. Livingstone: Edinburgh:Churchill; 1989.
3. Mraiwa N., Jacobs R., Van Cleynenbreugel J., et al. The nasopalatine canal revisited using 2D and 3D CT imaging. *Dentomaxillofacial Radiology*. 2004;33(6):396–402.
4. White S. C., Pharoah M. J. *Oral radiology: Principles and Interpretation*. 4th. St Louis: Mosby; 2000.
5. von Arx T[1], Lozanoff S. Anterior superior alveolar nerve (ASAN). Swiss Dent J. 2015;125(11):1202-9.
6. Manhães Júnior L. R., Villaça-Carvalho M. F., Moraes M. E., et al. L. Location and classification of Canalis sinuosus for cone beam computed tomography: avoiding misdiagnosis. *Brazilian Oral Research*. 2016;30(1):1–8.
7. Gokhan Gurler, Cagri Delilbasi, Emine Esen Ogut,Kader Aydin, et al. Evaluation of the morphology of the canalis sinuosus using cone-beam computed tomography in patients with maxillary impacted canines Imaging Sci Dent. 2017 Jun;47(2):69-74.
8. Machado V. D. C., Chrcanovic B. R., Felippe M. B., et al. Assessment of accessory canals of the canalis sinuosus: a study of 1000 cone beam computed tomography examinations. *International Journal of Oral and Maxillofacial Surgery*. 2016;45(12):1586–1591.
9. Von Arx T., Lozanoff S., Sendi P., et al. Assessment of bone channels other than the nasopalatine canal in the anterior maxilla using limited cone beam computed tomography. *Surgical and Radiologic Anatomy*. 2013;35(9):783–790.
10. Neves F. S., Crusoé-Souza M., Franco L. C. S., et al. Canalis sinuosus: A rare anatomical variation. *Surgical and Radiologic Anatomy*. 2012;34(6):563–566.
11. José Alcides Arruda, Pedro Silva, Luciano Silva,Pâmella et al. Dental Implant in the Canalis Sinuosus: A Case Report and Review of the Literature Case Rep Dent. 2017; 2017: 4810123.
12. Oliveira-Santos C, Rubira-Bullen IRF, Monteiro SAC, et al Neurovascular anatomical variations in the anterior palate observed on CBCT images. Clin Oral Implants Res. 2013;24(9):1044-8.