Evaluation of the Use of Platelet-Rich Fibrin in Socket Preservation in Patients with Chronic Periodontitis

Iyad Alsayed[1]*, Ali Abousulaiman[1], Ahmad Al Jawish[2], Mohammed Monzer Alsabbagh[1]

1. Department of Periodontology, Faculty of Dentistry, Damascus University, Damascus, Syria.
2. Department of Pediatric, Faculty of Dentistry, Damascus University, Damascus, Syria.

Abstract

Tooth extraction procedure triggers osteoclasts resulting in different levels of bone resorption in the crestal bone around the extracted tooth, which will eventually lead to diminishing the height and width of the alveolar bone. Socket preservation is essential to ensure that the quantity of the remaining bone is adequate for future procedures to restore the edentulous ridge. The aim of this study was to assess the outcomes of PRF in preserving sockets of teeth extracted due to chronic periodontitis both clinically and radiographically.

A total of 20 patients who have indications for bilateral extraction due to chronic periodontitis were included in this study. Extraction sockets were allocated randomly into the PRF group or normal healing group (NH). Cone beam computed tomography (CBCT) were obtained immediately after extraction and 6 months later for radiographic assessment whereas for clinical assessment an acrylic stent was used.

This study demonstrated that applying PRF resulted in a statistically significant difference 6 months post extraction in terms of reducing alveolar bone resorption both clinically and radiographically. However, there was no statistical difference with regard to bone density between the two groups. In conclusion, this study demonstrated that using PRF in socket preservation of teeth extracted due to chronic periodontitis resulted in minimizing bone resorption but PRF had no effect on bone density when compared with normal healing of the socket.

Clinical article (J Int Dent Med Res 2020; 13(1): 246-251)

Keywords: Extraction, socket preservation, periodontitis, PRF.

Received date: 08 October 2019 **Accept date:** 24 November 2019

Introduction

Tooth extraction has been indicated for managing various cases such as severe periodontitis, trauma, untreatable endodontic lesions and developmental deformities. The extraction procedure triggers osteoclasts resulting in different levels of bone resorption in the crestal bone around the extracted tooth, which will eventually lead to diminishing the height and width of the alveolar bone[1]. Several studies have been carried out to evaluate the minimization of bone resorption or acceleration in bone healing utilizing a variety of materials such as bone grafts, bone substitutes and growth factors[2,3].

Corresponding author:
Iyad Alsayed
Department of Periodontology, Faculty of Dentistry, Damascus University, Damascus, Syria.
E-mail: iyad.alsayed@gmail.com

Periodontitis is described as a disease that causes rapid destruction involving soft and hard tissues[4]. Despite bacteria being the main etiologic factor in periodontitis, factors such as race, age, sex, genetics and smoking play a role in the pathogenesis of this disease[5]. Although chronic periodontitis (ChP) affects patients aged over 35, it can be seen in young adults and is characterized by plaque accumulation, attachment loss and bone resorption[5]. ChP can be either localized or generalized depending on having attachment loss affecting less than 30% of teeth or more respectively[4].

In 2001, Choukroun et al. introduced platelet rich fibrin (PRF) and it was considered as the second generation of platelet rich plasma (PRP). PRF preparation technique does not require anticoagulant or bovine thrombin as opposed to other platelet concentrates[6,7]. The PRF clot consists of large quantities of platelets and leukocytes cytokines supported by a fibrin matrix. The fibrin mesh allows the gradual

release of cytokines throughout 7-11 days, which is the time required for the fibrin matrix to resolve[8]. The effect of PRF differs from that of PRP since the fibrin matrix supporting the cytokines in the former lasts longer than the latter[9]. This is as a result of the limited amount of thrombin that exists in the blood sample which contributes to the slow formation of the fibrin clot of the PRF. Thus, the fibrin matrix lasts longer than that of the PRP which requires bovine thrombin to form[10]. PRF has an essential role in supporting the immune system and regulating the inflammatory process because it contains leukocytes and cytokines that contribute to reducing pain and edema after surgical procedures and might reduce the incidence of infection[11].

Several lines of research were conducted to assess the role of PRF in minimizing bone resorption after extraction. A study by Alzahrani et al., showed that using PRF resulted in greater bone fill and decreased bone width resorption compared to normal healing[12]. Houser et al., concluded that applying PRF without elevating a flap yielded a significant difference in reducing bone resorption both vertically and horizontally compared to normal healing group and PRF with elevating a flap group[13]. Nonetheless, Zhang et al., reported that whilst bone formation in the PRF group was higher compared to normal healing, no statistically significant difference was found between the two groups in reference to reducing bone resorption[14]. Moreover, Suttapreyasri et al., demonstrated that the PRF group showed accelerated bone formation without any statistically significant difference between the PRF group and control group [15]. Similar findings were reported by Srinivas et al., who also revealed statistically significant bone density in the PRF group [16]. On a similar note, studies by Rau et al., and Gurbuzer et al., illustrated that bone density was better in the PRF group but with no statistically significant difference [17, 18].

The purpose of this study was to evaluate the clinical and radiographical outcomes of PRF in preserving the crestal bone in sockets of teeth extracted due to chronic periodontitis.

Materials and methods

This comparative prospective randomized clinical trial lasted 19 months, between March 2017 and November 2018. It included 20 participants, 11 males and 9 females, aged between 24-49 years and were referred to the Department of Periodontology, Faculty of Dentistry, Damascus University for periodontal treatment. A thorough medical and dental histories were obtained from each patient using a designated study form.

A complete periodontal chart was obtained for each patient. In addition, panoramic radiographs were used to confirm the diagnosis. Ethical clearance was obtained from Damascus University and patients' written consents were collected.

To be included in the study, patients should be: aged between 20 and 50 years old with no systemic diseases, diagnosed with generalized chronic periodontitis, indications for bilateral extraction due to periodontal disease involving bone loss more than two thirds of the root.

The exclusion criteria were: subjects with periapical or periodontal abscesses, pregnant or lactating females, alcohol users, smokers, subjects who underwent chemo or radio therapy and subject who used antibiotic / anti-inflammatory drugs over the last three months before treatment.

Split-mouth study design was implemented and a total of forty teeth were haphazardly (a lot draw) allocated into two groups. Group PRF comprised twenty extraction sockets treated with PRF, whereas in group (NH) the other twenty extraction sockets were left to heal normally.

Preparation of PRF:

20 ml of patient's blood was collected by venipuncture of the median cubital vein, and blood was distributed into two 10 ml glass tubes. The tubes were shaken before they were placed into a centrifuge to prevent clots from developing, and the centrifuge was set for 3000 revolutions per minute for 10 minutes. Having been centrifuged, three layers will be found in each tube, the red blood cells in the bottom, the PRF layer in the middle and the platelet poor plasma at the top.

Surgical Procedures:

local anesthesia, Lidocaine 2% with epinephrine 1:80000 was administrated. Elevators were applied to gradually luxate the teeth, afterwards forceps used for extraction to ensure that the trauma to the alveolar bone is as minimum as possible.

In group PRF flapless atraumatic extraction of the specified tooth was performed. Utmost care was taken to protect the bone plates (palatal and buccal). Soft tissue in the socket were removed gently using curettes. Subsequently, sockets were filled with PRF which was held in place by non-absorbable silk mattress suture. Whilst in group NH, the other socket, the same surgical protocol adopted without PRF clot.

Postsurgical instructions included: administration of systemic antibiotic (amoxicillin 500 mg Amoxi ®, Unipharma, Damascus, Syria) three times a day for a week. Additionally, patients were asked to refrain from tooth brushing for at least two weeks post-surgery, and chlorhexidine mouthwash 0.12% (Biofresh ®, Unipharma, Damascus, Syria) was prescribed twice a day for a week. Sutures were removed after ten days.

Clinical Assessment:

The clinical evaluation of the alveolar bone height was done by measuring the distance between a premade acrylic stent and the highest point in the buccal, mesial, distal and lingual plates using a UNC-15 probe. These measures were taken immediately after extraction, and six months later.

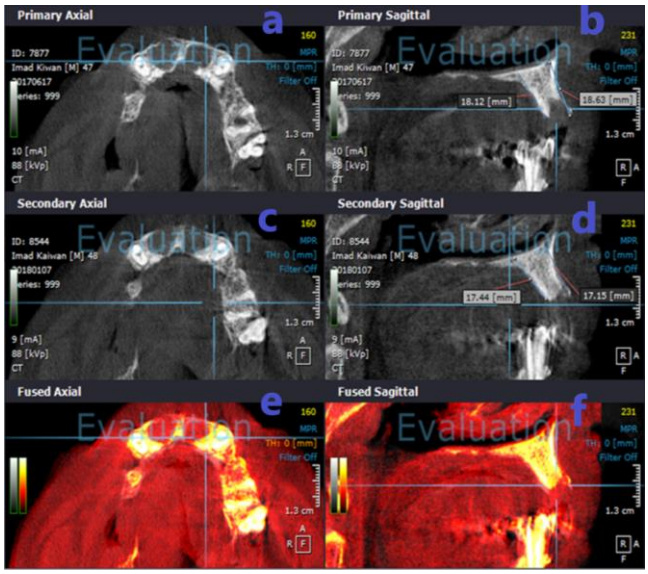

Figure 1. (a. b) Measuring socket height on the primary CBCT radiograph in the sagittal plane immediately after extraction. (c, d) measuring socket height on the secondary CBCT radiographs in the axial and sagittal planes 6 months after extraction. (e, f) the fused radiographs of the primary and secondary radiographs.

Radiographic Assessment:

A cone beam computed tomography CBCT was done at baseline and six months intervals to measure the bone resorption both horizontally and vertically and to measure the bone density. Radiographical socket height was obtained by measuring the distance between the crest midline for the buccal and lingual/ palatal plates and the maxillary/mandibular basal bone, Figure [1]. Socket width was measured from the highest point of the lower plate to its perpendicular projectile on the opposite plate, Figure [2: a, b]. Furthermore, bone density was assessed using the profile tool attached with CBCT software (OnDemand 3D Dental version 1.0.9.3223) in the secondary radiograph, 6 months after extraction, Figure [2: b].

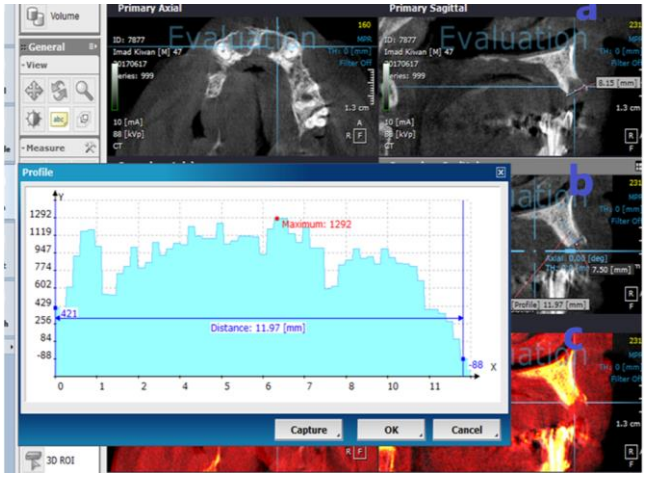

Figure 2. (a) Measuring socket width on the primary CBCT radiograph in the sagittal plane immediately after extraction. (b) measuring socket width and bone density on the secondary CBCT radiograph in the sagittal plane 6 months after extraction. (c) the fused radiographs of the primary and secondary radiographs.

The data of the two radiographs was combined by the aforementioned software to produce a fused imaged and ensure measurements were recorded at the same plane.

Statistical Analysis:

Data was analyzed using statistical software (IBM SPSS Statistics version 22). Paired Student t Test was used to evaluate the alterations in bone dimensions between baseline and six months after extraction within the same group. Unpaired Student t Test was used to analyze the difference in bone dimensions between baseline and six months after extraction

between the two groups. Results were considered significant at P < .05 with 95% confidence intervals.

Results

Extraction resulted in statistically significant decrease of bone dimensions, alveolar crest height and radiographical socket height and width, in both groups six months after the extraction, (P < .05) as noted in [Table 1].

Group	Variable	Mean ± SD Baseline	Mean ± SD 6 months	Difference in means ± SD	T	P Value
NH Group	Alveolar crest height	11.53 ± 1.95	9.73 ± 1.95	1.80 ± 0.38	21.354	<0.001
	Radiographical socket height	10.54 ± 1.29	8.82 ± 1.15	1.72 ± 0.45	16.909	<0.001
	Radiographical socket width	7.51 ± 0.69	6.57 ± 0.78	0.94 ± 0.42	10.025	<0.001
PRF Group	Alveolar bone height	11.58 ± 1.58	10.78 ± 1.46	0.80 ± 0.34	10.514	<0.001
	Radiographical socket height	10.37 ± 1.09	9.66 ± 0.98	0.71 ± 0.35	8.966	<0.001
	Radiographical socket width	7.42 ± 0.67	6.79 ± 0.75	0.63 ± 0.44	6.406	<0.001

Table 1. P < .05 denotes significant differences between baseline and 6 months within the same group according to Paired Student t Test.

As for the effect of PRF, it contributed to declining the bone resorption significantly compared to the NH group in terms of alveolar Crest level and radiographical socket height and width, (P < .05) [Table 2].

Variable	Difference in means between the two groups after 6 months	T	P Value
Alveolar crest height	1.00	8.806	<0.001
Radiographical socket height	1.02	7.895	<0.001
Radiographical socket width	0.31	2.297	0.027

Table 2. P < .05 denotes significant differences between baseline and 6 months between the two groups according to Unpaired Student t Test.

Variable	Mean ± SD 6 months		Difference in means	T	P Value
	NH Group	PRF Group			
Bone Density (Hounsfield)	697.95 ± 334.05	575.10 ±293.84	122.85	1.235	.224

Table 3. P > .05 denotes no significant difference between the two groups according to Unpaired Student t Test.

Regarding bone density, applying PRF resulted in no statistically significant difference when comparing the two groups 6 months after extraction, (P > .05) [Table 3].

Discussion

The present study was conducted to assess the clinical and radiographical effects of PRF in reducing alveolar bone resorption in sockets of teeth extracted due to chronic periodontitis. The present study showed that there were statistically significant differences in the clinical alveolar crest level and the radiographical socket height and width between the PRF group and the NH group 6 months after extraction. This could be attributed to the role that PRF plays as fibrin contains a huge number of leukocytes which aid the immune system and regulate the inflammatory response[1911]. Moreover, the growth factors that exist in the fibrin matrix are released progressively which eventually lead to forming new blood vessels, new collagen fibers and bone remodeling as well as inhibiting osteoclast formation and inducing the formation of osteoblast[2021,22]. In terms of bone density, applying PRF resulted in better bone density, but there was no statistically significant difference between the two groups 6 months after extraction. This finding could be explained within the light of the actual properties of PRF itself. it is well documented that growth factors are actively released during the first weeks post-surgery reaching a peak at 14 days after surgery and then decline gradually[23]. Thus, PRF is thought to be effective in the early days of healing. Nonetheless, bone density is dependent on the maturation and remodeling of the newly formed bone, which could be noticed at a later stage following the subsidence of the effects of the growth factors released from the PRF.

The present study showed that the average clinical and radiographical bone resorption in the vertical dimension in normal healing group was 1.72 ± 0.45 mm and 1.8 ± 0.38 mm respectively, and PRF group was 0.7 ± 0.35 mm and 0.8 ± 0.34 mm respectively. These findings were in accordance with Alzahrani et al., and Richard et al., as their results demonstrated that using PRF yielded less vertical bone resorption. Notwithstanding, our findings contradict with Zhang et al., and Srinivas et al., who reported that there was no significant difference when using PRF to reduce bone resorption compared with normal healing both

clinically and radiographically. This disagreement could be due to the fact that the follow up visits in these studies were arranged three months post extraction whereas in our study it was 6 months post extraction, as well as the radiographical evaluation was achieved using anatomical landmarks rather than superimposing radiographs as what was done in our study. Furthermore, our observations were in disagreement with Suttapreyasri et al., who concluded that there was no significant difference between the PRF group and the normal healing group both clinically and radiographically. This might be attributed to the utilization of different radiographic examination technique as they used periapical radiograph to measure bone dimensions.

This study demonstrated that the average horizontal bone resorption in PRF group was 0.63 ± 0.44 mm and in normal healing group was 0.94 ± 0.42 mm. These results were reflected in the study of Alzahrani et al., who reported that the horizontal bone resorption was significantly less when PRF was applied.

Our study also reported that the average bone density in the PRF group was 675.95 Hounsfield whereas in the normal healing group was 575.10 Hounsfield, and these findings were not significant 6 months post extraction. Our findings were in agreement with Rau et al., Richard et al., and Gurbuzer et al. On the other hand, the results of our study contradict with those of Srinivas et al., who found that the use of PRF yielded a significant difference when it comes to bone density compared with the blood clot group. These discrepancies can be as a consequence of measuring the bone density on periapical radiographs as opposed to our study, which utilized CBCT.

Conclusions

This study demonstrated that using PRF in socket preservation of teeth extracted due to chronic periodontitis resulted in minimizing bone resorption in the vertical and horizontal dimensions. In addition, using PRF in socket preservation had no effect on bone density when compared with normal healing of the socket.

Declaration of Interest

The authors report no conflict of interest and the article is not funded or supported by any research grant.

References

1. Altundal H, Güvener Ö. The effect of alendronate on resorption of the alveolar bone following tooth extraction. International journal of oral and maxillofacial surgery 2004;33(3):286-93.
2. Indovina Jr A, Block MS. Comparison of 3 bone substitutes in canine extraction sites. Journal of oral and maxillofacial surgery 2002;60(1):53-58.
3. Peck M, Marnewick J, Stephen L. Alveolar ridge preservation using leukocyte and platelet-rich fibrin: A report of a case. Case Rep Dent. 2011; 2011: 345048.
4. Armitage GC. Development of a classification system for periodontal diseases and conditions. Annals of periodontology 1999;4(1):1-6.
5. Albandar JM, Tinoco EM. Global epidemiology of periodontal diseases in children and young persons. Periodontology 2000 2002;29(1):153-76.
6. Raja VS, Naidu EM. Platelet-rich fibrin: evolution of a second-generation platelet concentrate. Indian Journal of Dental Research 2008;19(1):42.
7. Sunitha Raja V, Munirathnam Naidu E. Platelet-rich fibrin: evolution of a second-generation platelet concentrate. Indian J Dent Res 2008;19(1):42-6.
8. Toffler M, Toscano N, Holtzclaw D, Corso MD, Ehrenfest DD. Introducing Choukroun's platelet rich fibrin (PRF) to the reconstructive surgery milieu. J Implant Adv Clin Dent 2009;1(6):21-30.
9. Djais AI, Akbar FH, Adam M, et al. Application of Platelet Rich Fibrin (PRF) on Endodontic-Periodontic Lesion in Periodontal Tissue Regereneration: Case Report. Journal of International Dental & Medical Research 2019;12(3).
10. Saluja H, Dehane V, Mahindra U. Platelet-Rich fibrin: A second generation platelet concentrate and a new friend of oral and maxillofacial surgeons. Annals of maxillofacial surgery 2011;1(1):53.
11. Simonpieri A, Del Corso M, Sammartino G, Ehrenfest DMD. The relevance of Choukroun's platelet-rich fibrin and metronidazole during complex maxillary rehabilitations using bone allograft. Part I: a new grafting protocol. Implant dentistry 2009;18(2):102-11.
12. Alzahrani AA, Murriky A, Shafik S. Influence of platelet rich fibrin on post-extraction socket healing: A clinical and radiographic study. The Saudi dental journal 2017;29(4):149-55.
13. Hauser F, Gaydarov N, Badoud I, et al. Clinical and histological evaluation of postextraction platelet-rich fibrin socket filling: a prospective randomized controlled study. Implant dentistry 2013;22(3):295-303.
14. Zhang Y, Ruan Z, Shen M, et al. Clinical effect of platelet-rich fibrin on the preservation of the alveolar ridge following tooth extraction. Experimental and therapeutic medicine 2018;15(3):2277-86.
15. Suttapreyasri S, Leepong N. Influence of platelet-rich fibrin on alveolar ridge preservation. Journal of Craniofacial Surgery 2013;24(4):1088-94.
16. Srinivas B, Das P, Rana MM, et al. Wound healing and bone regeneration in postextraction sockets with and without platelet-rich fibrin. Annals of Maxillofacial Surgery 2018;8(1):28.
17. Gürbüzer B, Pikdöken L, Tunalı M, et al. Scintigraphic evaluation of osteoblastic activity in extraction sockets treated with platelet-rich fibrin. Journal of Oral and Maxillofacial Surgery 2010;68(5):980-89.
18. Rao SG, Bhat P, Nagesh K, et al. Bone regeneration in extraction sockets with autologous platelet rich fibrin gel. Journal of maxillofacial and oral surgery 2013;12(1):11-16.
19. Margono A, Asrianti D, Meydiawati R. The Efficacy of Advanced Platelet-rich Fibrin (A-PRF) on Fibroblast Cell Regeneration. Journal of International Dental and Medical Research 2017;10:789-92.

20. Asri SR, Setiati HD, Asrianti D, et al. Optimum Concentration of Platelet-Rich Fibrin Lysate for Human Dental Pulp Stem Cells Culture Medium. Journal of International Dental and Medical Research 2019;12(1):105-10.
21. Anitua E, Alkhraisat MH, Orive G. Perspectives and challenges in regenerative medicine using plasma rich in growth factors. Journal of controlled release 2012;157(1):29-38.
22. Nauth A, Ristevski B, Li R, Schemitsch EH. Growth factors and bone regeneration: how much bone can we expect? Injury 2011;42(6):574-79.
23. He L, Lin Y, Hu X, Zhang Y, Wu H. A comparative study of platelet-rich fibrin (PRF) and platelet-rich plasma (PRP) on the effect of proliferation and differentiation of rat osteoblasts in vitro. Oral Surgery, Oral Medicine, Oral Pathology, Oral Radiology, and Endodontology 2009;108(5):707-13.