Anatomical Variations of the Osteomeatal Complex in the Lateral Wall of Nose a Cadaveric Study

Vijaya Ramanathan[1], Anitha Krishnan Pandarathodiyil[2], Anand Ramanathan[3,4], Phrabhakaran Nambiar[5]

1. Department of Anatomy, Meenakshi Medical College and Research Institute, Enathur, Kanchipuram, 631552, India.
2. Faculty of Dentistry, SEGi University, 9 Jalan Teknologi, Taman Sains Selangor, PJU 5, Kota Damansara, 47810 Petaling Jaya, Selangor, Malaysia.
3. Department of Oral Diagnostic Sciences, Faculty of Dentistry, SEGi University, 9 Jalan Teknologi, Kota Damansara, 47810, Petaling Jaya, Selangor.
4. Oral Cancer Research and Coordinating Centre, Faculty of Dentistry, University of Malaya, Kuala Lumpur, 50603, Malaysia.
5. Faculty of Dentistry, MAHSA University, Saujana Putra, 42610, Malaysia.

Abstract

The morphology of the osteomeatal complex at the lateral wall of the nose varies greatly among different races and ethnic groups, indicating mandatory study of the surgical anatomy of this area for different populations. The aim of this study is to identify the shape, variations of the middle turbinate, distances, posterior extent measured between the three turbinates and the site of opening of maxillary sinus ostium in a sect of South Indian population. Twenty hemi sections of adult cadaveric heads were utilized for this study. Direct visual measurements were performed using a vernier caliper and a protractor. Majority of the specimens i.e., 85% showed Type I shape of the middle turbinate. The mean distance between anterior attachments of superior turbinate and middle turbinate was 16.95 mm. Posterior margin of middle turbinate ended more posteriorly in 90% specimens compared to inferior turbinate. The ostium of maxillary sinus opened in posterior 1/3rd of middle meatus in 60% specimens. Accessory middle turbinate was observed in 2 hemi sections. The ethnic anatomical variations were evident when compared with the Koreans. Being aware of these variations can guide the neurologist, otorhinolaryngologist, ophthalmologist and oral and maxillofacial surgeons who use the middle meatus and osteomeatal complex as a gateway to approach their respective regions of interest for surgical procedures.

Experimental article (J Int Dent Med Res 2020; 13(3): 880-886)

Keywords: Accessory middle turbinate, Chronic rhinosinusitis, Middle meatus, Osteomeatal complex, Turbinate bones.

Received date: 03 December 2019 **Accept date:** 29 January 2020

Introduction

The anatomy of lateral wall of the nasal cavity is highly variable with the superior and middle turbinate developing from the ethmoidal bone whereas the inferior turbinate develops as a separate bone. Noticeably the lacrimal and sinus drainage system can be viewed clearly just by removing the anterior attachment of inferior and middle turbinate [1].

The main features of the lateral wall in the middle meatus region are a rounded elevation, the bulla ethmoidalis and a curved cleft, the hiatus semilunaris[2]. This hiatus leads into the ethmoidal infundibulum, which is bordered medially by the uncinate process and laterally by the orbital plate of the ethmoid. The infundibulum extends upwards and forwards and is continuous with frontonasal recess into which the frontal sinus opens. The anterior ethmoidal cell/sinus opens into the infundibulum or the frontonasal recess, whereas the middle ethmoidal air cell/sinus opens on or above the bulla. The maxillary sinus ostium opens usually on the lateral aspect of the infundibulum between the middle third and posterior third of middle meatus. The area under the middle turbinate into which the maxillary sinus, frontal sinus and anterior ethmoidal system open is termed as the osteomeatal complex (OMC) [3].

***Corresponding author:**
Dr. Anand Ramanathan
Department of Oral & Maxillofacial Clinical Sciences,
Faculty of Dentistry, University of Malaya,
50603, Kuala Lumpur, Malaysia.
E-mail: drranand@um.edu.my

The OMC is bounded by the middle turbinate medially, lamina papyracea laterally, basal lamella superiorly and posteriorly. The inferior and anterior borders of OMC are open. The contents of this space are agger nasi, nasofrontal recess, infundibulum, bulla ethmoidalis and anterior group of ethmoidal air cells. The agger nasi is a prominence seen in the anterior attachment of middle turbinate. Obstruction free OMC and mucociliary clearance are the key factors for ventilation and drainage of maxillary, frontal and anterior ethmoidal air cells [4].

Many sinuses open into the small expansible area of OMC making it more complex. Moreover, there is multitude of variations in each of these structures present in OMC, which is challenging to the otorhinolaryngologist who deals with this region.

Obstruction of the OMC in the middle meatus leads to mucosal congestion, which decreases the air flow and can significantly lead to obstruction of the paranasal drainage sites [5,6], leading to chronic rhinosinusitis [7-9]. An estimated 134 million Indians suffer from chronic sinusitis, which is more than the population of Japan. Extensive surgeries for OMC disease have been replaced by a minimally invasive surgery. Functional Endoscopic Sinus Surgery (FESS) treats chronic rhino sinusitis that is refractory to medical management [10].

The shape of middle turbinate has been classified into 3 types namely Type I where the anterior border of middle turbinate runs posteroinferiorly from its attachment to the conchal plate making an obtuse angle. In Type II, the anterior border run inferiorly and then in a posteroinferior direction making a right angle. In Type III, the anterior border bulges anteriorly before it courses posteroinferiorly[11].

Physical templates of human cadaveric[12] specimens and CT images have been evaluated to understand the anatomical variations of structures in the lateral wall of nose. The morphology of the lateral wall of the nose varies greatly among different races and ethnic groups, indicating mandatory study of the surgical anatomy of this area for different populations[11]. Studies on morphological details of OMC and related structures from the population of Indian subcontinent are indeed scarce.

The aim of this study, performed on hemisected cadaveric heads in a sect of South Indian population, is to identify the shape of the middle turbinate, distances between the three turbinates, the extent of the posterior margins of middle and inferior turbinates, determine any variations in the middle turbinate and ascertain the site where the ostium of the maxillary sinus opens.

Materials and methods

Institutional and ethical clearance were obtained for this study [103/MMCH & RI/2016]. Twenty hemi sections of adult cadaveric heads of both the genders were utilized for this study.

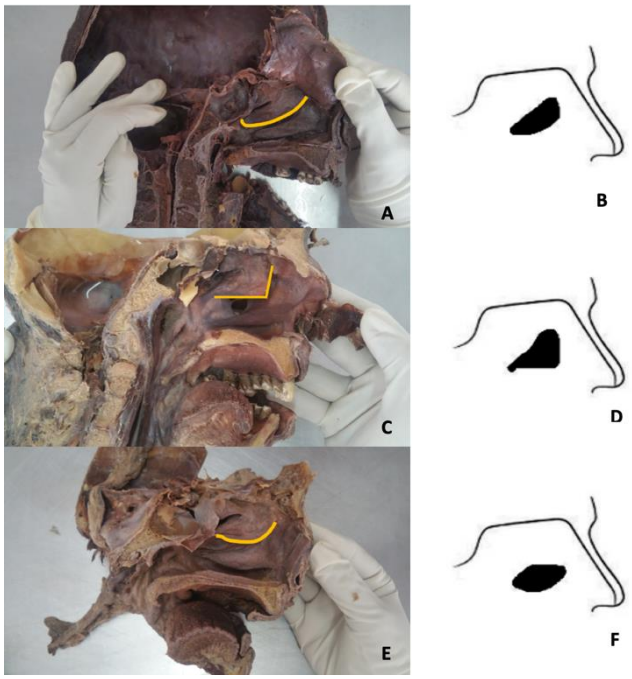

Figure 1. Photograph and illustration of (A & B) type I (C & D) type II and (E & F) type III shape of middle turbinate.

This research was conducted in the Department of Anatomy of a Private Medical College in Tamil Nadu. A protractor and vernier caliper instruments were used for obtaining the necessary measurements. The following were the parameters studied: (i) Shape of the middle turbinate was noted, photographed and classified into the 3 types (Fig.1a to c). (ii) The distance between the anterior limit of superior and middle turbinate, middle and inferior turbinate. In addition, the distance between the posterior limit of superior and middle turbinate and middle and inferior turbinate (Fig. 2a). (iii) The extent of the posterior margins of middle and inferior turbinate

(Fig. 2b, c). (iv) Other variations near the middle turbinate (Fig. 2d). (v) Site of opening of the ostium of maxillary sinus, whether in the anterior (Fig. 2e), middle (Fig. 2f) or posterior thirds of middle meatus (Fig. 2g) was noted.

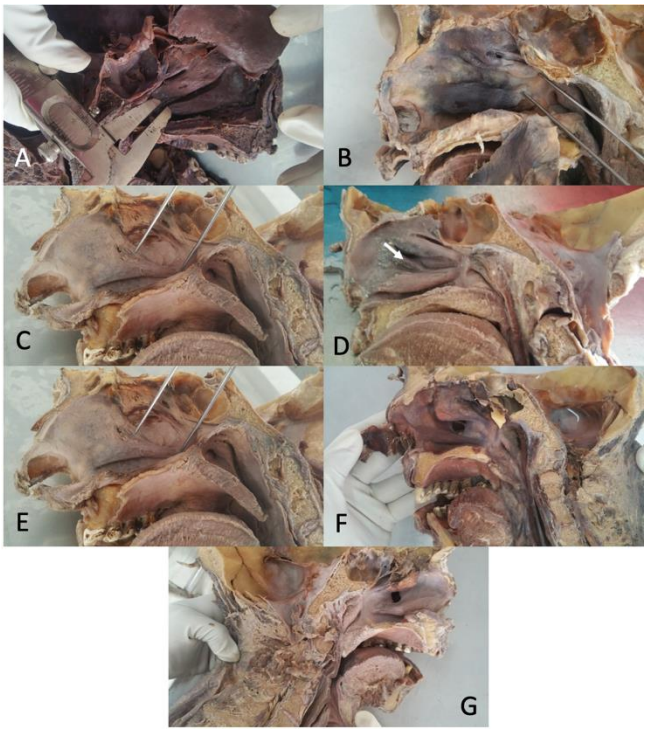

Figure 2. Photographs showing (A) distance between the posterior limit of middle and inferior turbinate (B) the posterior end of middle turbinate extends more posteriorly than inferior turbinate (C) the posterior end of inferior turbinate extends more posteriorly to middle turbinate (D) accessory middle turbinate (white arrow) (E to G) site of opening of maxillary ostium in the (E) anterior (F) middle and (G) posterior one third of the middle meatus.

Results

In this study, three types of shape of middle turbinate were observed. About 85% of the specimens were of the Type I (Fig. 1a), 10% showed Type II (Fig. 1b) and about 5% of the specimens showed the Type III variety (Fig. 1c). The mean distance between anterior attachments of superior turbinate and middle turbinate was 16.95 mm whereas the mean distance between middle and inferior turbinate was 20.60 mm. Mean distance between posterior attachments of superior turbinate and middle turbinate was 9.4 mm, whereas between middle turbinate and inferior turbinate was 13 mm. The minimum, maximum, mean and standard deviation data for the above parameters are recorded in Table 1.

Distance between	Minimum	Maximum	Mean	SD
Anterior limit of superior and middle turbinate	12.00	22.00	16.95	3.017
Posterior limit of superior and middle turbinate	6.00	15.00	9.40	2.326
Anterior limit of middle and inferior turbinate	6.00	32.00	20.60	5.744
Posterior limit of middle and inferior turbinate	10.00	17.00	13.00	2.026
Middle turbinate angle	90.00	140.00	120.80	14.17

Table 1. Statistical analysis of distances between turbinates and angle of middle turbinate.
SD – standard deviation.

On comparing the posterior termination of the middle turbinate, it was observed that they ended more posteriorly to the inferior turbinate in 90% of the specimens (Fig.2a). In 2 hemi sections, accessory middle turbinate was seen and its length was 26 mm whereas in another it was 20 mm. They extended from the posterior end of lower border of middle turbinate to middle of upper border of inferior turbinate (Fig. 2d). The ostium of maxillary sinus opened in posterior 1/3rd of the middle meatus in 60% of specimens (Fig. 2e), in the middle 1/3rd in 35% specimens (Fig. 2f) and in 5% it opened in anterior 1/3rd of the middle meatus (Fig. 2g).

Discussion

Endoscopy is being used both for evaluating and treating diseases of nasal passage and paranasal sinuses. Hence the anatomy of the nasal passage and paranasal air sinuses has gained much attention in recent years [13]. Moreover, as seen with most anatomical structures, the middle meatus and lateral nasal wall are also subjected to normal variations and this must be distinguished from pathologic changes [14]. Interestingly cadaveric studies of anatomical variations in the lateral wall of nose [15,16] can collectively reconstruct the three-dimensional geometry, which becomes useful for the operating otorhinolaryngologists.

Present study explores the morphological features of the lateral wall of nose in a sect of South Indian population. Morphological data on the lateral wall of the nose has been studied in

other ethnic population like Koreans [11] who belong to the Mongoloid race. The South Indian population represented in the present study exhibited the Type I shape of the middle turbinate, in contrast to the Korean population where Type I and II were predominant. This highlights the ethnic and racial differences present in the shape of middle turbinate amongst the Asian subpopulations. The middle turbinate has multiple functions such as olfaction, filtration, humidification, lubrication of upper airways, regulating airflow and temperature [17]. Partial turbinectomy enhances the surgical access to the middle meatus during FESS [18] and improves the surgical outcome in paradoxical middle turbinate, high septal deviation, narrow nasal pyramid and septal mucosal hypertrophy. However, if the anterior portion of middle turbinate is extensively removed it leads to destabilization. Hence, based on the anatomical findings presented here, it becomes logical to suggest that in Type I cases, care should be taken so as not to remove the olfactory filaments distributed in the anterior part of middle turbinate to ensure prevention of destabilization [19]. However, in Type III cases, the middle turbinate appears large and bulged anteriorly and its removal ensures wider view during surgery [11]. Endoscopic sinus surgery (ESS) may fail to control chronic rhinosinusitis due to anatomic variations that may prevent adequate mucociliary clearance and drug delivery. One of such anatomical variations is the resected middle turbinate, which may require revision ESS [20].

The mean distance between the anterior attachment of superior and middle turbinate in this study (actual mean) was less compared to the Koreans (theoretical mean) [11]. The wider distance between the anterior ends of the superior and middle turbinate may be due to the flat and wide based contour of the nose seen in the Korean subpopulation as compared to the Indians. In this study the mean distance between: (i) anterior attachment of middle and inferior turbinate, (ii) the posterior attachment of superior and middle turbinate and (iii) posterior attachment of middle and inferior turbinate were measured. Interestingly these values have not been reported so far. Variations in these parameters may prove to be of importance for surgeons who may have to deduce these distances and identify any overcrowding in this area. It forms potential drainage site for most of the paranasal sinuses. In addition, the width of the OMC is a significant predictor of effectiveness in the treatment of odontogenic maxillary sinusitis [21].

In this study, majority of the specimens showed that the middle turbinate extending more posteriorly than the inferior turbinate (90%) compared to only 40% in the study conducted by Lee et al (2006). In contrast, the posterior margin of inferior turbinate ended more posteriorly than middle turbinate in only 10% of specimens when compared to 26.3% in the study by [11]). Moreover, there were no specimens in the present study, which had the posterior ends of middle and inferior turbinates proximal to each other. This is unlike in the Korean study where Lee et al. (2006) reported that 33.7% of their specimens had such an arrangement.

The middle turbinate should be preserved to avoid leaks, anosmia, frontal sinusitis [22,23] and they play a pertinent role in maintaining laminar flow and efficient air conditioning [24,25]. However if surgery is warranted, wide resection is necessary to expose the drainage sites and reduce the risk of complications [14,26].

In the present study, an accessory middle turbinate was seen in only 2 hemi sections. Lin, Lin, Su, Wang [27] reported that a secondary middle turbinate co-existed with an accessory middle turbinate, thereby complicating any surgical procedure. However, the presence of a double middle turbinate and its removal significantly improved the blocked nose and frontal headache. Presence of accessory turbinate can aggravate rhinosinusitis and awareness of such variations can assist the treating surgeon to modify his management [28]. However, there was no second middle turbinate reported in the present study.

The position of the opening of the ostium of maxillary sinus in the middle meatus was observed, and majority of them opened at the posterior 1/3rd of the middle meatus which is in agreement to other studies [29-33]. This has direct implication towards the airflow pattern, mass flux and infection of the sinus. Airflow pattern within the nasal cavity models, with presence of only one ostium of maxillary sinus, either anteriorly or posteriorly in the middle meatus was studied. On inspiration, the airflow generated a high velocity vortex (swirl) at the ostium area with half of the velocity vectors going towards the maxillary sinus whereas the rest returning to the nasal cavity

even before entering the sinus. During expiration the airflow circulates at the ostium entrance without going into the sinus. Therefore, the entering mass flux at the anterior ostium during peak inspiration was higher compared to the exhalation whereas, if the ostium is present posteriorly in the middle meatus, the entering mass flux was equal at peak inhalation and exhalation [34,35]. Ventilation was less when the ostium was placed anteriorly [34,35] that prevents the surface of the maxillary lining from drying and it maintains a high nitric oxide concentration [36] which helps in prevention of pathogens from spreading within the sinus [37,38]. Additionally, the entering mass flow rate is higher during inspiration, which may be related to its function of warming and humidifying the inhaled air [34,35]. The presence of a second or accessory ostium causes different pattern of the airflow and the mass flux [34,35]. It may also cause circular flow of the mucous from the accessory ostium to the natural ostium thus resulting in mucous recirculation [39].

Accessory maxillary ostium (AMO) have been reported in 19.1% of the subjects studied by CT scan [40], whereas 0% [41] to 43% [42] in cadaveric studies. Cadaveric studies in Indians have reported the presence of AMO from 18.5% [31], 18.75% [33], 22.5% [30] to 30% [43]. Endoscopic study in Indians also reported 21% had AMO [44]. However, in the present study no such accessory ostium was observed in any of the hemi sections. Caution may need to be expressed here because there may be possible shrinkage of the accessory ostium in cadavers stored for an extended period. As stated earlier, the presence of AMO alters the mucociliary clearance and result in chronic rhinosinusitis. Enlarging the AMO becomes necessary when the maxillary ostium is obstructed and it may help in aeration of the maxillary sinus [31].

Since the maxillary ostium is located below the orbital floor, mostly in the posterior 1/3rd of the middle meatus, care should be taken to avoid perforation of the lateral wall of the nose superior to the maxillary ostium, such that the floor of the orbit is not injured while performing endoscopy. Nibbling with forceps and blind probing in this region too may lead to orbital complications [45]

Each nasal structure has its specific function [13]. In some CT studies the anatomical structures that recorded variations are the concha bullosa, paradoxical middle turbinate, uncinate process (pneumatized), infraorbital ethmoidal cell, nasal septum (deviated), paradoxical curvature of the middle turbinate and Haller cells [4,46-48]. The obstructive anatomic variations in the middle meatus can result in secondary infection of adjacent sinuses [43,49,50]. In a related study 53.7% of patients with chronic sinusitis had 2 or more anatomical variations in OMC and 33.3% of cases showed at least a single anatomical variation [51]. Patients with bilateral OMC obstruction were more likely to have asthma than unilaterally obstructed or unobstructed cases [52]. In yet another study reported in India, patients in the age group of 11-30 years who suffered headaches due to a rhinogenic etiology was contributed by OMC diseases [31].

Thus, variations in normal anatomy of OMC could contribute to many pathologic conditions.

By understanding the anatomical variations, the otorhinolaryngologist and sinus surgeons can probably avert damages to the critical structures closely related to this area, including the orbit and base of skull [53]. Patients usually show considerable improvement and relief of their symptoms after undergoing FESS. Preoperative evaluation of the various anatomical structures in the lateral wall of nose and OMC is important for ensuring surgical safety and success [54, 55]

Conclusions

The lateral wall of nose at the middle meatus region overlies the osteomeatal complex, where numerous anatomical structures are sited. The present cadaveric study on South Indians was focused on the surgical anatomy at this area, there were considerable differences in the shape of middle meatus, distance between turbinates, variations in the posterior ends of middle and inferior turbinates. Variations in the middle turbinate in the form of accessory turbinate were observed and the position of the opening of ostium of maxillary sinus in the middle meatus has also been investigated. The present cadaveric study can complement the findings of nasal endoscopies and CT scans and thus help correlate the findings of other researchers on the anatomical structural variations that occur in this constrained yet an important region. This added

information from the cadaveric study would assist the neurologist, ophthalmologists, otorhinolaryngologist and oral and maxillofacial surgeons who might choose the OMC site for approaching their region of interest in various surgical techniques.

Acknowledgements

The authors would like to thank Dr. Srijaya Chandrabose Thekkeparambil for her help in formatting this manuscript and the illustrations of the figures. The authors also would like to thank Ms. Thamilarasi Thanaperumal and Mr. Wong Gou Rean for their help in citing and referencing of the document.

Declaration of Interest

The authors report no conflict of interest.

References

1. Balasubramanian DT. Advanced anatomy of lateral nasal wall. https://drtbalu.com/ana_latnose.html. Published 2006.
2. Standring S. The Anatomical Basis of Clinical Practice. 40th Edition ed: Elsevier; 2008.
3. Chummy S, Sinnatamby RJ. Last's Regional and Applied Anatomy. 11th ed: Churchill Livingstone Elsevier 2006.
4. Bandyopadhyay R, Biswas R, Bhattacherjee S, Pandit N, Ghosh S. Osteomeatal Complex: A Study of Its Anatomical Variation Among Patients Attending North Bengal Medical College and Hospital. Indian J Otolaryngol Head Neck Surg. 2015;67(3):281-86.
5. Mamatha H, Shamasundar NM, Bharathi MB, Prasanna LC. Variations of Ostiomeatal complex and its applied anatomy: a CT scan study. Indian journal of Science and Technology 2010;3(8):904-07.
6. Sasirekha M, Ashokkumar A. A Study of Anatomical Variations of Ostiomeatal Complex in correlation with Computed Tomography. Indian Journal of Applied Research 2014;4(1):428-29.
7. Neto SAdA, Martins PdSL, de Souza AS, Baracat ECE, Nanni L. The Role of Ostiomeatal Complex Anatomical Variants in Chronic Rhinosinusitis. Radiol Bras 2006;39(3):227-32.
8. Tonai A, Baba S. Anatomic variations of the bone in sinonasal CT. Acta Otolaryngol Suppl. 1996;525:9-13.
9. Tao Z, Zhang J, Yang Q, Xiao B, Kong Y. Differences of anatomic variations in ostiomeatal complex between two sides of the deviated septum. Zonghua Er Bi Yan Hou Ke Za Zhi 2001;36(2):132-34.
10. Stewart MG, Smith TL, Weaver EM, et al. Outcomes after nasal septoplasty: results from the Nasal Obstruction Septoplasty Effectiveness (NOSE) study. Otolaryngol Head Neck Surg. 2004;130(3):283-90.
11. Lee HY, Kim CH, Kim JY, et al. Surgical anatomy of the middle turbinate. Clin Anat. 2006;19(6):493-96.
12. Hornung DE, Leopold DA, Youngentob SL, et al. Airflow patterns in a human nasal model. Arch Otolaryngol Head Neck Surg. 1987;113(2):169-72.
13. Mirza A, Sajad Majid Q, Aijazul H. CT Evaluation of Anatomical Variations in Ostiomeatal Complex in Patients with Deviated Nasal Septum. Bangladesh J Otorhinolaryngol 2015;21(2):90-93.
14. Biedlingmaier J, Whelan P, Zoarski, Rothman M. Histopatholoy and CT analysis of partially resected middle turbinates. Laryngoscope. 1996;106:102-04.
15. Sato TJ, Murakami G, Tsubota H, Isobe M, Akita K, Kataura A. Morphometric study of the medial aspect of the human maxillary sinus with special reference to the nasal fontanelle. Auris Nasus Larynx. 2000;27(2):121-30.
16. Kim KS, Kim HU, Chung IH, Lee JG, Park IY, Yoon JH. Surgical anatomy of the nasofrontal duct: anatomical and computed tomographic analysis. Laryngoscope. 2001;111(4 Pt 1):603-08.
17. Swanson P, Lanza D, Kennedy D, Vining E. The effect of middle turbinate resection upon frontal sinus disease. Am J Rhinol Allergy. 1995;9:191-95.
18.Giacchi RJ, Lebowitz RA, Jacobs JB. Middle turbinate resection: issues and controversies. Am J Rhinol. 2000;14(3):193-97.
19. Kim KS, Choi YS, Kim HJ, Yoon JH. The risk of olfactory disturbance from conchal plate injury during ethmoidectomy. Am J Rhinol. 2003;17(5):307-10.
20. Bewick J, Egro FM, Masterson L, Javer AR, Philpott CM. Anatomic findings in revision endoscopic sinus surgery: Case series and review of contributory factors. Allergy Rhinol (Providence). 2016;7(3):151-57.
21. Tomomatsu N, Uzawa N, Aragaki T, Harada K. Aperture width of the osteomeatal complex as a predictor of successful treatment of odontogenic maxillary sinusitis. Int J Oral Maxillofac Surg. 2014;43(11):1386-90.
22. Kennedy DW. Middle turbinate resection: evaluating the issues--should we resect normal middle turbinates? Arch Otolaryngol Head Neck Surg. 1998;124(1):107.
23. Vleming M, Middelweerd RJ, de Vries N. Complications of endoscopic sinus surgery. Arch Otolaryngol Head Neck Surg. 1992;118(6):617-23.
24. LaMear WR, Davis WE, Templer JW, McKinsey JP, Del Porto H. Partial endoscopic middle turbinectomy augmenting functional endoscopic sinus surgery. Otolaryngol Head Neck Surg. 1992;107(3):382-89.
25. Kelly JT, Prasad AK, Wexler AS. Detailed flow patterns in the nasal cavity. J Appl Physiol (1985). 2000;89(1):323-37.
26. Stammberger H. Endoscopic endonasal surgery--concepts in treatment of recurring rhinosinusitis. Part I. Anatomic and pathophysiologic considerations. Otolaryngol Head Neck Surg. 1986;94(2):143-47.
27. Lin YL, Lin YS, Su WF, Wang CH. A secondary middle turbinate co-existing with an accessory middle turbinate: an unusual combination of two anatomic variations. Acta Otolaryngol. 2006;126(4):429-31.
28. El-Shazly AE, Poirrier AL, Cabay J, Lefebvre PP. Anatomical variations of the lateral nasal wall: The secondary and accessory middle turbinates. Clin Anat. 2012;25(3):340-46.
29. Van Alyea O. The ostium maxillare. Anatomic study of its surgical accessibility. Arch Otolaryngol Head Neck Surg. 1936;24:553-69.
30. Prasanna LC, Mamatha H. The location of maxillary sinus ostium and its clinical application. Indian J Otolaryngol Head Neck Surg. 2010;62(4):335-37.
31. Kaur A, Singh A. Clinical study of headache in relation to sinusitis and its management. J Med Life. 2013;6(4):389-94.
32. Gnanavelraja C. Primary Maxillary Sinus Ostium- A Cadaveric Study. Journal of Evidence Based Medicine and Healthcare. 2014;1(7):569-73.
33. Jyothi N, Nayak, Varalakshmi KL, Sangeetha M, Shilpa N. An Anatomical Study on Location of Maxillary Sinus Ostium and It' S Surgical Importance. Int J Cur Res Rev. 2014;6(18):39-41.
34. Afiza E, Takakura Y, Atsumi T, Masahiro I. A Study on Ostia Variation for Airflow Patterns within Nasal Cavity Models with Maxillary Sinus Vol 402015.
35. Takakura Y, Atsumi T, Iida M. Effects of Ostia Variation for Airflow Patterns within Nasal Cavity Models with Maxillary Sinus Journal of Medical and Bioengineering. 2016;5(2):98-102.
36. Rennie CE, Hood CM, Blenke EJ, et al. Physical and computational modeling of ventilation of the maxillary sinus. Otolaryngol Head Neck Surg. 2011;145(1):165-70.
37. Hood CM, Schroter RC, Doorly DJ, Blenke EJ, Tolley NS. Computational modeling of flow and gas exchange in models of the human maxillary sinus. J Appl Physiol (1985). 2009;107(4):1195-1203.

38. Lundberg JO. Nitric oxide and the paranasal sinuses. Anat Rec (Hoboken). 2008;291(11):1479-84.
39. Chung SK, Dhong HJ, Na DG. Mucus circulation between accessory ostium and natural ostium of maxillary sinus. J Laryngol Otol. 1999;113(9):865-67.
40. Yenigun A, Fazliogullari Z, Gun C, Uysal, II, Nayman A, Karabulut AK. The effect of the presence of the accessory maxillary ostium on the maxillary sinus. Eur Arch Otorhinolaryngol. 2016;273(12):4315-19.
41. May M, Sobol S, Korzec K. The Location of the Maxillary Os and Its Importance to the Endoscopic Sinus Surgeon. Laryngoscope. 1990;100(10):1037-42.
42. Schaeffer JP. The Nose, Paranasal Sinuses, Nasolacrimal passageways and olfactory organ in man. Pholadelphia: P. Blakiston's Son; 1920.
43.Kumar H,Choudhry R, Kakar S. Accessory Maxillary Ostia: Topography and Clinical Application.J Anat Soc India. 2001;5(1):3-5.
44. Anukaran M, Anupama M, Karunesh G, Pankaj V, Monika L. Anatomical Variations of Accessory Maxillary Sinus Ostium: An Endoscopic Study. Int J Anat Res 2017;5(1):3485-90.
45. Myerson MC. The natural orifice of the maxillary sinus-anatomic study. Arch Otolaryngol Head Neck Surg. 1932;15:80-91.
46. Azila A, Irfan M, Rohaizan Y, AK S. The prevalence of Anatomical Variations in Ostiomeatal Unit in Patients with chronic Rhinosinusitis. Med J Malaysia. 2011;66(3):191-94.
47. Leila K, A, Sabah M, A, Seyed AM, B. Anatomical Variations of Ostiomeatal Complex in CBCT of Patients Seeking Rhinoplasty. J Dent Shiraz Univ Med Sci. 2015;16(1):42-48.
48. Lee JW, Yoo JY, Paek SJ, et al. Correlations between anatomic variations of maxillary sinus ostium and postoperative complication after sinus lifting. J Korean Assoc Oral Maxillofac Surg 2016;42:278-83.
49. Stammberger H, Wolf G. Headaches and sinus disease: the endoscopic approach. Ann Otol Rhinol Laryngol Suppl. 1988;134:3-23.
50. Halis U, H. , Serdar A, Yildirim N, et al. Anatomic Variations of The Middle Meatus In Patients With Sinusitis. Gazi Medical Journal. 1992;3:145-50.
51. Aramani A, Karadi RN, Kumar S. A study of Anatomical Variations of Ostiomeatal Complex in Chronic Rhinosinusitis Patients- CT Findings. . J of Clinical and Diagnostic Research. 2014;8(10):KC01-KC04.
52. Chandra RK, Pearlman A, Conley DB, Kern RC, Chang D. Significance of osteomeatal complex obstruction. J Otolaryngol Head Neck Surg. 2010;39(2):171-74.
53. Sarafraz M, Nikakhlagh S, Abshirini H, et al. Anatomical Variations of Anterior Ostiomeatal Complex in Patients with Chronic Sinusitis. Jentashapir J Health Res. 2016;7(3):e29926.
54. Stackpole SA, Edelstein DR. Anatomic variants of the paranasal sinuses and their implications for sinusitis. Curr Opin Otolaryngol Head Neck Surg. 1996;4:1-6.
55. Nitin V Deosthale, Sonali P Khadakkar, Bhanupratap Singh, Vivek V Harkare, Priti R Dhoke, Dhote KS. Anatomical variations of Nose and Paranasal sinuses in Chronic Rhinosinusitis. *Journal of Scientific Research* 2014;7(2).