Combined Method of Treatment of Dentists in the Early Stages of Osteochondrosis of the Cervical Spine

Zhandarov K.A[1], Ogarev E.V[2], Chekanov M.S[3], Vasil'ev Yu.L[1], Meylanova R.D[1], Kryuchko P.V[1], Dydykin S.S[1]

1. Sechenov university, Moscow, Russia.
2. N.N. Priorov National Medical Research Center of Traumatology and Orthopedics, Moscow, Russia.
3. National Medical Service CJSC (Nearmedic Clinic), Moscow, Russia.

Abstract

Purpose: to develop an effective combined algorithm for the treatment of cervical osteochondrosis in the early stages in dentists and other patients with a similar occupational disease (seamstresses, hairdressers, etc.). Materials and methods: The study was performed on 28 patients, 9 - male and 19 - female, aged 23 to 44 years. The patients were divided into 2 groups. The first group - those who passed the 1st stage of treatment and the 2nd group - those who passed the first and second stages. Pain syndrome and changes in its dynamics at the stages of treatment were determined using a visual analogue scale VAS - Visual Analogue Scale (VAS). The range of motion in the cervical spine was determined using a 5-point scale. During the II stage of treatment, to assess the effectiveness of treatment at the time of manual therapy (before and after the session), an ultrasound study was performed with the registration of qualitative and quantitative indicators of changes in blood flow in the vertebral arteries (PA). Results: after the first stage, positive dynamics was observed in all patients. All patients noted a decrease, and in 10.7%, complete disappearance of pain syndrome. The volume of movements returned to 7.1%. Restrictions of movements regressed to a greater extent after the second stage of treatment than after the first one. After stage II of treatment, patients showed a general decrease in the intensity of pain syndrome in all patients. Complete disappearance of pain syndrome in 92.9% of cases. Non-permanent pain syndrome was recorded only by 7.1% of patients. An increase in the normal range of motion up to 92.9% was noted. Satisfaction with the treatment carried out was assessed as satisfactory in only two cases, in all the remaining 26 as good. Before and after manual therapy, changes in the blood flow velocity in the VA were recorded using ultrasound diagnostics. Conclusion: Our proposed effective combined algorithm for the treatment of cervical osteochondrosis in the early stages in dentists and other patients with a similar occupational disease (seamstresses, hairdressers, etc.) can be used in clinical practice along with other methods.

Clinical article (J Int Dent Med Res 2021; 14(2): 825-834)

Keywords: Occupational disease of dentists, post-isometric muscle relaxation, PIR, combined treatment of cervical osteochondrosis, cervical spine.

Received date: 14 January 2021 **Accept date:** 13 February 2021

Introduction

The etiopathogenesis of cervical osteochondrosis is based on dysontogenic disorders, traumatic injuries and sprains, and the consequences of birth trauma. Therefore, the clinical manifestation of degenerative diseases of the maxillofacial and neck regions largely depends on its anatomical and physiological characteristics[1]. Pathological changes in the cervical spine most often occur in the atlantoaxial joint and in the most mobile lower cervical spines C5-C7, the cause of which is caused by the combined effects of both connective tissue and bone structures, pathologically altered discs. In the cervical spine, evidence was obtained of the participation of intraforaminal ligaments in the

Corresponding author:
Zhandarov K.A, associate professor,
Sechenov university, Clinical Medicine Institute, operative surgery and topographic anatomy department,
Moscow, Russia
E-mail: kirill-zhandarov@mail.ru

pathogenesis of cervical osteochondrosis and the possibility of influencing them with the help of therapeutic manipulations; a new nosologically term was introduced: the ligamentary-foraminal form of radicular syndrome[2].

In this regard, the determination of the correct tactics for the treatment of cervical osteochondrosis with radicular syndrome is of considerable interest. In the publications of clinicians there is not enough information on the determination of the most effective method of treatment of cervical osteochondrosis in the early stages, and there is no consensus on its etiopathogenesis[3,4,5]. Therefore, the development of a combined method of treating patients with an occupational disease - osteochondrosis in the early stages is of significant interest[6,7].

In the study of the functional state of the musculoskeletal system and the mobility of the nervous processes of medical workers[6], it was shown that the work of a dentist is harmful (hard) work of the 3rd degree: the working posture of a dentist is characterized by periodic, up to 25% of the time, being in an uncomfortable placement of limbs, with a turn of the head, etc.) and a fixed posture with the impossibility of changing the relative position of various parts of the body, standing up to 67% of the change time. Pain in the cervical spine, aggravated by radicular symptoms, is a difficult problem for dentists.

The most problematic category of patients is represented by patients with a chronic inflammatory process in the late stages (III-IV) of cervical osteochondrosis. This is due to the appearance of lateral or combined stenosis, herniated discs, and instability. This group of patients develops specific neurological and angiopathic syndromes, often requiring surgical treatment associated with high risks.

Already in the early stages of cervical osteochondrosis, it is necessary to determine the treatment regimen and consistently carry it out during attacks in order to prevent or postpone the development time of subsequent stages of the dystrophic process. Previously, we investigated the issue of choosing the optimal radiation diagnosis in the early stages of lateral stenosis and developed an algorithm for choosing a method[2].

This method turned out to be multispiral computed tomography with 3D modeling, the accuracy of which is 91.2%[6]. We use this method in a study to determine an effective combined method of treating patients in the early stages of cervical osteochondrosis, which, we hope, will improve the results of their treatment, and, subject to annual treatment and prophylactic measures, will slow down the development of late stages of muscular tissue dystrophy - musculoskeletal system of the neck.

Purpose of the study: To develop a combined method for the treatment of cervical osteochondrosis of dentists in the early stages.

Materials and methods

Research objects and planned number of observations:

The treatment was carried out at the clinical base of the Sechenov University in the period 2015-2019. Our experiment to treat a group of patients took 3 years.

The study involved 28 patients of both sexes: 9 - men and 19 - women, aged 23 to 44 years. Participation in the study, diagnosis and treatment was carried out with the written consent of the patients for the course of treatment in compliance with the ethical standards. The study was approved by the local ethics committee of the Sechenov University and was organized according to the principles of the Declaration of Helsinki by the World Medical Association (1964), as amended in 2013.

Sex differentiation was not carried out. Exclusion criteria were middle and old age, dystrophic changes (more pronounced stages) in the structures of the cervical vertebral segment. The algorithm for the treatment of radicular syndrome that arose as a result of cervical osteochondrosis with signs of lateral stenosis included 2 stages: initial and final. The patients were divided into 2 groups: the first group - patients who passed the 1st stage of treatment and the 2nd group passed the first and second stages.

All patients - dentists who applied for treatment at the vertebrological clinic, were united by the following complaints:

- general weakness for no previous reason,
- fast fatiguability,
- headache,
- passing dizziness,
- pain in the cervical spine,
- discomfort in the spine of the same name,
- "crunch" in the neck,
- arthralgia in the joints without local

inflammatory manifestations,

- radicular pain in the neck and along the projection of the cervical and brachial plexuses.

The patients' condition was assessed before the start of treatment, at the end of the first and second stages of treatment. The pain syndrome and its change in its dynamics after the stages of treatment were determined using the Visual Analogue Scale (VAS)[7] A line 10 cm long was drawn, on which the inscription follows every 2 cm: 0 cm - no pain; 2 cm - mild pain; at around 4 cm - moderate pain; 6 cm - severe pain; 8 cm - very severe pain; at the end point at 10 - unbearable pain.

In the case when the patient experienced pain that cannot be characterized by the proposed characteristics, for example, between moderate (4 points) and severe pain (6 points), the pain was assessed with an odd number between these values (5 points).

The range of motion in the cervical spine was assessed on a 5-point scale, where: norm - 0; hypermobility - (-1); moderate restriction of movement –1; significant limitation (contracture) –2 and 3 points - contracture.

To assess the effectiveness of treatment during the II stage of treatment during the implementation of manual therapy (before and after the session), ultrasound was performed on a Philips Affinity 70 apparatus, using a linear transducer with a frequency of 5-12 MHz. The experimental group included all 28 patients. The qualitative and quantitative characteristics of blood flow in VA were assessed: peak systolic velocity (V ps), end diastolic velocity (Ved), resistance index (IR), and pulsation index (IP). These parameters were measured in PA in patients before the start of the procedure and 5 minutes after the end of the procedure.

We have introduced a scale of clinical impression, where 1 point is deterioration; 0 points - no effects; 1 point - the effect is slightly pronounced; 2 points - moderate effect; 3 points significant effect.

In the process of accounting, a quantitative accounting of trigger zones was made.

Muscle tone was determined by palpation at rest and with isometric muscle tension.

The initial stage (stage I) included the following treatment:

1.drug symptomatic therapy,

2.creation of conditions for reducing the load (creating rest),

3.physiotherapy effects,

4. Patients perform exercise therapy independently.

After a thorough history taking, we used the following drugs as symptomatic drug therapy: NSAIDs, vitamins (B1, B6 and B12) and in cases of pronounced muscle tension – myorelaxants.

At the same time, our treatment algorithm includes the creation of rest and wearing a cervical collar for 2 weeks (up to 2 hours a day), physiotherapy treatment with magnetic laser or UHF (ultra-high frequency) impact on pathological zones, aimed at reducing inflammation in tissues and activation of reparation processes in them.

After removing the collar, the patients performed exercise therapy exercises for 20 minutes. aimed at bringing the muscles into tone, without load and in amplitudes that do not imply pain reactions.

The final stage (stage II) of our patients was carried out using functional methods of treatment: massage, manual therapy, traction therapy (traction), remedial gymnastics exercise therapy, which patients performed according to the scheme of "proprioceptive neuromuscular re-education" (PNF) approved for dentists, every day once a day. These methods of treatment were used after the acute period of the disease subsided and not earlier than 1-2 weeks after the onset of the exacerbation.

Massage and manual therapy were performed on the patient in turn. At the beginning, a relaxing massage was performed, consisting of stroking, rubbing and light kneading of the neck muscles. The massage was performed using peach or fir oils.

When relative relaxation of muscles was achieved by massage, they began manual therapy. Guided by practical experience, we have chosen PIR - post-isometric muscle relaxation as the main method of manual manipulation of the cervical spine of our patients. The essence of this technique consists in muscle relaxation, achieved after passive stretching, following its performance in the isometric mode for 7-10 seconds. Static load (isometric work) and passive muscle stretching are repeated 3-5 times until the onset of the analgesic effect and relaxation of the corresponding muscle. Thus, the muscle is

stretched to the maximum possible value, thereby the muscle comes to tone, and then to a relaxed state. As a result, redox reactions occur in the muscle in all areas, which have a pronounced therapeutic effect. Using the PIR technique, we worked on the neck muscles in the following order.

Figure: 1-15

Also, special gymnastics was used, which included exercises of "proprioceptive neuromuscular re-education" (PNF), recommendations for exercises were explained to patients and given out in their hands[8].

Figure 1. Exercise 1 - impact on the horizontal portion of the trapezius muscle.

Figure 2. Exercise 2 - impact on the vertical portion of the trapezius muscle.

Figure 3. Exercise 3 - impact on the neck rotator muscles.

Figure 4. Exercise 4 - impact on the anterior scalene muscle and the sternocleidomastoid muscle.

Figure 5. Exercise 5 - traction with the patient sitting.

Figure 6. Exercise 6 - traction on the cervical spine with the patient lying on his back.

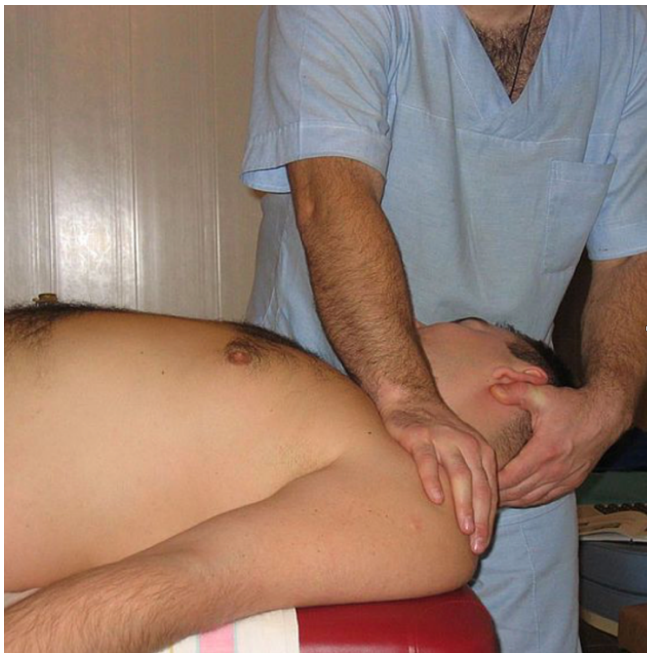

Figure 7. Exercise 7 - trapezius muscle stretching.

Figure 8. Exercise 8 - traction mobilization.

Figure 9. Exercise 9 - Non-Specific Rotational Mobilization.

Figure 10. Exercise 10 - lateral-lateral mobilization.

Figure 11

Figure 12

Figure 11.-12. Exercise 11 - mobilization of the cervicothoracic spine for flexion.

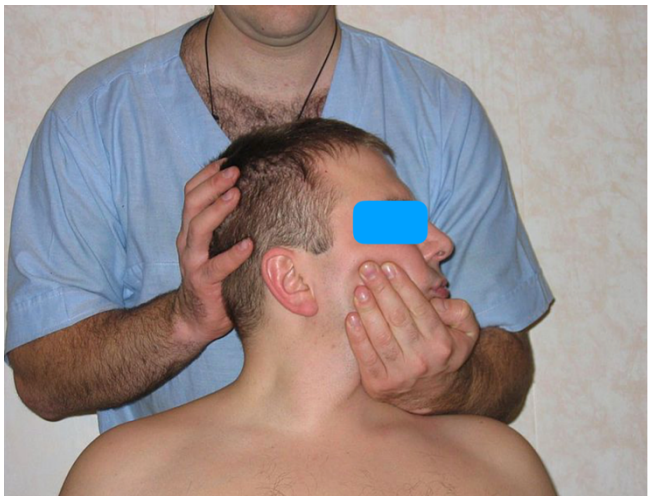

Figure 13. Exercise 12 nonspecific rotary manipulation.

Figure 14. Exercise 13 - manipulation on segment C1-C2 for traction.

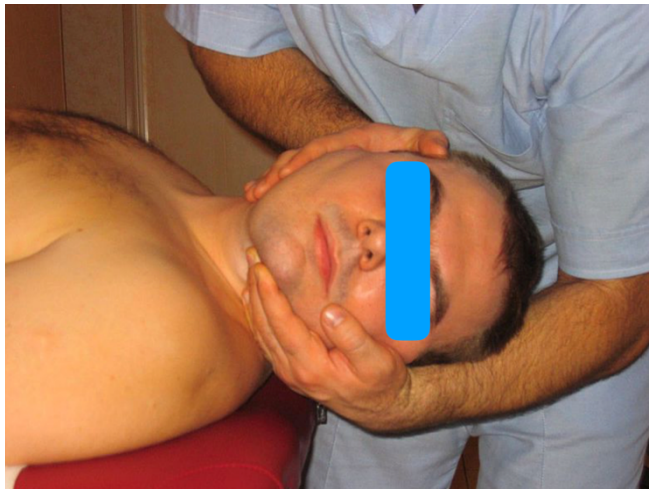

Figure 15. Exercise 14 - specific manipulation of rotation in the mid-cervical spine.

Results

General characteristics of patients before treatment:

In all cases, the patients experienced an increase in pain in the cervical spine in a working position with a static load (Figure 16).

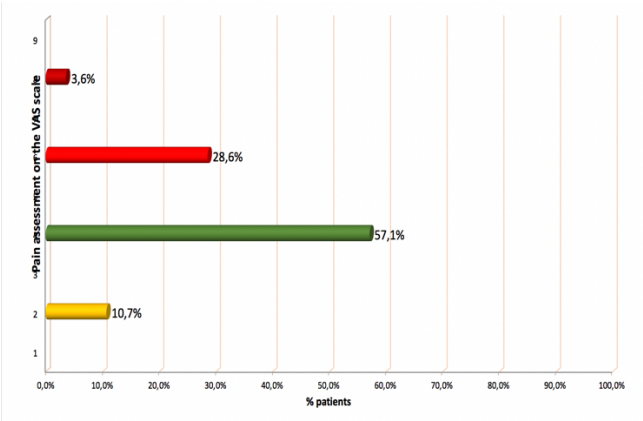

Figure 16. Assessment of the intensity of pain syndrome before treatment.

In 9 cases, there were intense pains, and the most severe pain in 1 patient was manifested by the syndrome of humeral-scapular periarthritis. In 9 patients, the pain increased with movement in the neck. Sixteen patients characterized pain as moderate but noted that the severity of pain and its intensity depend on the workload and movements in the neck. Three of them were worried about minor pains, pain sensations arose during the load of the VMS (spinal motion segments) of the neck. 6 patients had unilateral syndrome of the inferior oblique muscle of the

head, 5 patients had unilateral scalene syndrome. In two cases, carpal tunnel syndrome was identified. In addition, all had the following symptoms to varying degrees of severity: general weakness without previous causes and increased irritability, fatigue, headache, spinal discomfort, a crunch in the neck, arthralgia in the joints without local inflammatory manifestations.

	Movement volume, %	Before treatment	After 1 stage of treatment	After 2 stage of treatment
Hypermobility	-1	14,3%	14,3%	14,3%
Normal	0	75,0%	82,1%	92,9%
Moderate limitation of movement	1	10,7%	3,6%	
Significant limitation of movement	2	-	-	-
Contracture	3	-	-	-

Table 1. Assessment of the range of motion of patients.

The range of motion in patients before treatment: 4 patients had hypermobility, it is worth noting that in all cases they were women, the norm was fixed in 21 patients, and in 3 patients' moderate limitation of movements was noted (Table 1). Variants of significant limitation of range of motion and contracture were not recorded.

After the first stage, positive dynamics was observed in all patients. All patients noted a decrease, and in some cases, complete disappearance of pain syndrome (Figure 17).

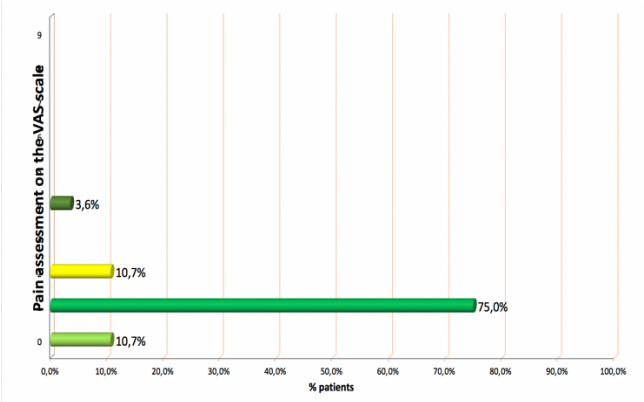

Figure 17. Assessment of the intensity of pain after the 1st stage of treatment.

After stage II of treatment, the complete disappearance of pain syndrome and an increase in the normal range of motion were noted in 92.9% of cases. Non-permanent pain syndrome was recorded only in 7.1% of patients. We did not record any effect on hypermobility in the joints, but patients with this pathology note that after the treatment, the movements became absolutely painless and the number of clicks in the joints of the neck decreased. There were no neurological complaints after stage II.

As a result of the ultrasound examination before and after manual therapy, it was found: in the study group, the average level of V ps was 53.8 cm / sec, Ved - 16.7 cm / sec, IR - 0.69, IP - 1.25, which corresponds normal blood flow in the group of healthy individuals (Fig. 18).

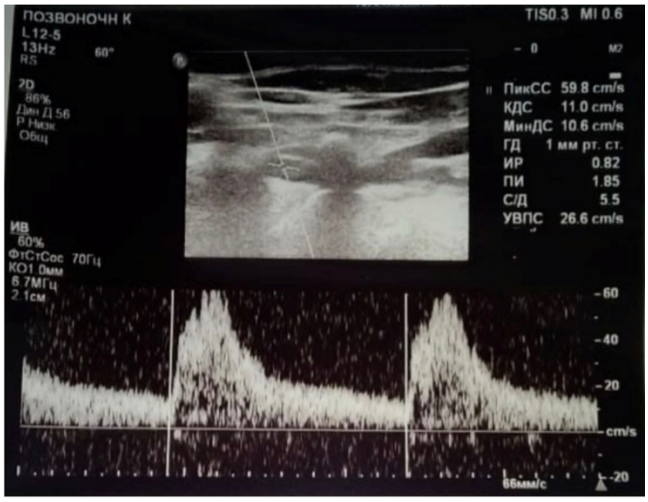

Figure 18. Indicators of blood flow before manual therapy.

After the performed treatment procedure, a tendency towards an increase in the velocity parameters of the blood flow was determined during the repeated study of the blood flow in the PA. So the average Vps was 56.5 cm / s and Ved - 17.1 cm / s. At the same time, changes in blood flow indices were recorded. IR increased to 0.70, IP - 1.31 (Fig. 19).

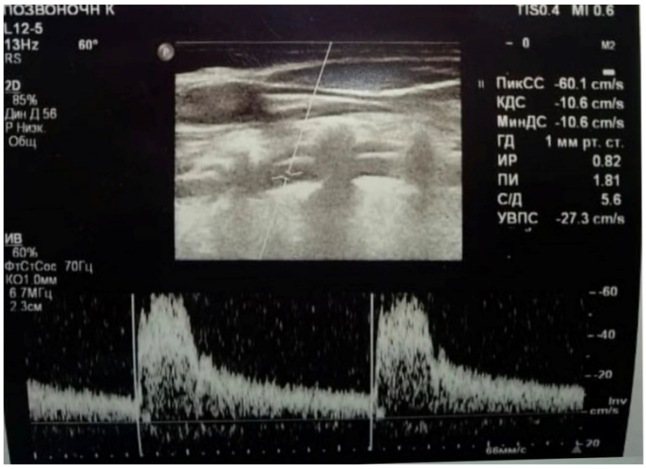

Figure 19. Indicators of blood flow after manual therapy.

Pain syndrome largely regressed after stage I of treatment. Reflex myotonic manifestations regressed to the greatest extent after the second stage of treatment.

Restrictions of movements regressed to a greater extent after the second stage of treatment than after the first one. We noted that after the second stage, the number of trigger zones decreased.

On average, after the first stage of treatment, the level of pain syndrome was 1.1 points, and after the second stage of treatment, the level of pain syndrome dropped to 0.02 points on the VAS scale.

By the end of the first stage of treatment, the pain syndrome completely disappeared in 3 patients and in 26 after the second stage (Fig 20), in all cases normal motor activity was restored.

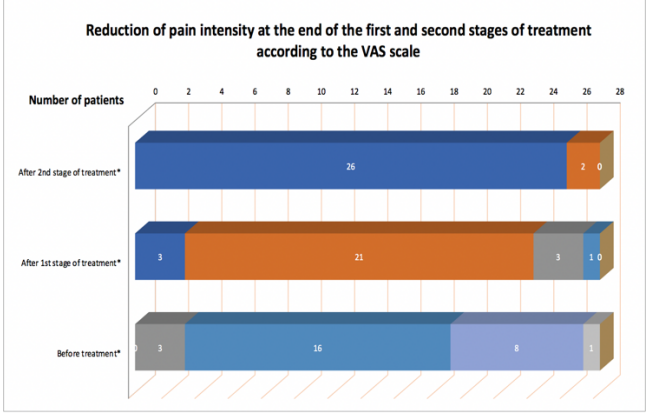

Figure 20. Reduction of pain intensity at the end of the first and second stages of treatment according to the VAS scale.

According to the survey data, satisfaction with the treatment carried out was assessed as satisfactory in only two cases, in all the remaining 26 as good. Despite the fact that at the first stage a reaction to NSAID drugs was recorded, there was no refusal of treatment.

Discussion

We have divided our combined method of treatment of professional cervical osteochondrosis into two methods of treatment, and its basis is manual therapy.

The basic method of treating osteochondrosis of the cervical spine is symptomatic drug therapy and functional immobilization. At the first stage, a monthly course of pharmacotherapy is required to create anesthetic and anti-inflammatory effects, which is confirmed by studies of autonomic regulation in patients with osteochondrosis[9]. We use the treatment regimen both during the combined treatment according to the algorithm we have developed, and during the period of exacerbation of the disease. Our treatment algorithm also includes the creation of rest and wearing a cervical collar for 2 weeks, 2 hours a day and outside the time of manual influences and physiotherapy treatment with magnetic laser or VHF effects on pathological zones. Patients perform exercise therapy independently on the basis approved for dentists according to the scheme of "proprioceptive neuromuscular re-education" (PNF)[10].

During the course of treatment, changes in the characteristics of the pain syndrome were noted. After 1 stage of therapy, there was a moderate regression of pain syndrome. It was recorded that none of the patients of the 1st group with a good therapeutic effect of pharmacotherapy had an exacerbation of osteochondrosis in the first month after the end of the 1st stage of treatment.

During the II stage of treatment, after several sessions of manual therapy, a positive dynamic of treatment is observed in all patients, the level of pain is reduced due to manual effects on the surrounding tissues. Patients noted the normalization of the range of motion and muscle tone, the number of trigger zones decreased and the general improvement in well-being (decreased irritability, headache, sudden changes in mood, normalized sleep).

It was previously noted that in the presence of true, as well as mixed ligaments, it is promising to carry out manual therapy in order to mobilize them, improve blood supply and relieve compression of neurovascular formations[2,11]. In particular, the unexpected effect of manual manipulations resulted in a decrease in hypermobility in 2 patients and normalization of range of motion in 5 patients, despite the fact that the morphological substrate underlying the hypermobility syndrome is a large collagen extensibility[12]. During the procedures for registering blood flow in the VA using ultrasound diagnostics, before and after manual therapy, changes in the blood flow velocity were recorded, proving its effectiveness.

At the same time, it should be remembered that manual therapy sessions only

partially eliminate pathobiomechanical disorders in the spine and pain syndrome, without affecting the main etiological and pathogenetic factors in the development of stenoses in the intervertebral canals of the cervical spine. And the fact that in the presence of degenerative altered ligaments, when lateral stenosis is formed and processes of destruction of the disc tissues with rupture of its membranes, hernias, instability in the PDS - late stages III, IV of cervical osteochondrosis, manual therapy is contraindicated. We can indirectly assume this situation, taking into account the patient's age and symptoms, and objectively assess using methods of radiation diagnostics (CT, MRI). With caution, manual therapy should be carried out with fixing ligamentous; carrying out manual therapy to such patients is fraught with ligament ruptures and hemorrhages.

The type of lateral stenosis is also of great importance in choosing a treatment method. In case of severe stenosis by osteophytes, surgical treatment is indicated, and in the case of dynamic stenosis, conservative treatment[13].

For the choice of a technique, the value of the reserve space index is important: the lower this indicator, the more we are inclined towards surgical treatment. Therefore, in all cases, the diagnosis must be confirmed by MRI and CT with 3D reconstruction. In the early I, II stages of osteochondrosis, according to the MRI of the neck, it is not possible to detect a picture of disc fragmentation, hernia or even protrusion, and, as a rule, only dystrophy of the intervertebral discs is found in the form of fibrous annulus dissociation. At the same time, the patient is worried about the most severe pain and paresthesia's, which served as an impetus for our topographic and anatomical studies of the neck PDS. The presence of intraforaminal ligaments, described as part of the "intervertebral canal of the cervical spine", was found[2,14]. Previously, this was explained only by the fact that the decreasing fixing capacity of the ligamentous apparatus during the displacement of the vertebrae in the supporting complexes causes extensive changes that generate pain impulses[15, 16].

Processes that occur without a pronounced picture of disc lesions, but affecting the intervertebral canals, are characteristic of the first two stages of osteochondrosis. In stage III of the process, pronounced dystrophy of the vertebral and disc tissue is formed, especially at levels CIII-CIV, CIV-CV and CV-CVI. These patients have vertebral instability and the question of surgical treatment is raised[2].

According to the literature, dentists are ranked 3rd in terms of the risks of occupational diseases[6]. The most serious indicator of the severity of the dentist's work is a significant static load aimed at maintaining a forced working posture, frequent turns and tilts of the head and body. Prolonged fatigue from constant stress is manifested by active physiological processes both in the musculoskeletal system and in the nervous system, which provides a long-term stress state of the muscles. Dynamic work is less tiring than static work. Since the stress under static load lasts continuously, without interruption, the anatomical elements involved in the static load process do not rest. It is worth noting that the dentist's work is often characterized by a long-term one-sided load, at the beginning of which muscles are tired, tendons and ligaments are stretched. In the short term, joint ligaments are weakened, and bone dislocation is noted[3,12]. In the long term, degenerative processes develop in the spine and paravertebral structures. Lateral stenosis develops rather quickly, which is accompanied by radicular syndrome, which is a characteristic picture of cervical osteochondrosis of the spine.

Studies on the effect of forced prolonged stress on the health of dentists convincingly prove that the musculoskeletal system subjected to static load for 5 or more hours gradually takes a forced position, which leads to a "helical" curvature of the spine in the thoracic and lumbar regions, and further can lead to S-shaped scoliosis[17]. The available data on the incidence and the effect of static load on the musculoskeletal system of dentists[17,18].

It is important to note that the forced position and prolonged stress can be aggravated by the regular psycho-emotional stress that doctors experience during the course of treatment procedures for patients[19]. In this regard, it is important to maintain not only the psycho-emotional state, which depends on many factors directly or indirectly related to work, but also to ensure that the doctor maintains the correct posture.

Conclusions

Undoubtedly, the fact that the cervical spine is also experiencing serious stress,

eventually provoking degenerative changes in it. New data on ligaments in the cervical spine, the most effective method of radiation diagnostics in the early stages of cervical osteochondrosis made it possible to revise the tactics of treating patients and, to conduct approbation the combined method of treatment of dentists with cervical osteochondrosis stage I-II. The results of its effectiveness have been obtained.

Declaration of Interest

The authors report no conflict of interest.

References

1. Vivi VW Wira, Yenny Pragustine, Laura S Himawan, Nina Ariani, Ira Tanti. Relationship between chronic pain severity and quality of life in TMD patients. J Int Dent Med Res 2018;11(1): 215-219
2. Zhandarov K.A., Oragev E.V., Shcherbyuk A.N. Radiological diagnostic technique selection in early cervical lateral stenosis. Sovremennye Tehnologii v Medicine. 2017; 9(2):118-125.
3. Zhandarov K.A., Nikolayev A.V., Telpukhov V.I., Nelipa M.V. Structural organization and morphometric characteristics of intervertebral channels of the cervical spine. Morfologiia. 2017;151(1):62-66.
4. Joaquim AF, Makhni MC, Riew KD. Post-operative nerve injuries after cervical spine surgery. Int Orthop. 2019;43(4):791-795.
5. Hawker GA, Mian S, Kendzerska T, French M. Grade Scale (CPGS), Short Form-36 Bodily Pain Scale (SF-36 BPS), and Measure of Intermittent and Constant Osteoarthritis Pain (ICOAP). Arthritis Care Res (Hoboken). 2011; 63(11):240–252.
6. Wong JJ, Shearer HM, Mior S, Jacobs C, Côté P, Randhawa K, Yu H, Southerst D, Varatharajan S, Sutton D, van der Velde G, Carroll LJ, Ameis A, Ammendolia C, Brison R, Nordin M, Stupar M, Taylor-Vaisey A. Are manual therapies, passive physical modalities, or acupuncture effective for the management of patients with whiplash-associated disorders or neck pain and associated disorders? An update of the Bone and Joint Decade Task Force on Neck Pain and Its Associated Disorders by the OPTIMa collaboration. Spine J. 2016;16(12):1598-1630.
7. Ohlendorf D, Erbe C, Nowak J, Hauck I, Hermanns I, Ditchen D, Ellegast R, Groneberg DA. Constrained posture in dentistry - a kinematic analysis of dentists. BMC Musculoskelet Disord. 2017;18(1):291.
8. Scott J, Huskisson EC. Graphic representation of pain. Pain. 1976; 2 (2):175–184.
9. Guiu-Tula FX, Cabanas-Valdés R, Sitjà-Rabert M, Urrútia G, Gómara-Toldrà N. The efficacy of the proprioceptive neuromuscular facilitation (pnf) approach in stroke rehabilitation to improve basic activities of daily living and quality of life: a systematic review and meta-analysis protocol. BMJ Open. 2017;7(12):e016739.
10. Joaquim AF, Makhni MC, Riew KD. Post-operative nerve injuries after cervical spine surgery. Int Orthop. 2019;43(4):791-795.
11. Parfenov Y, Vasilevskaya M, Parfenov S, Sapozhnikov K, Kovalenko A, Zaplutanov V. Substantiation of indications for biofeedback therapy and cytoflavin application in treatment of osteochondrosis neurological complications in elderly patients. Georgian Med News. 2018t;(283):89-96
12. Yin M, Wang H, Ma J, Huang Q, Sun Z, Yan W, Ye J, Mo W. Radiological characteristics and surgical outcome of patients with long ossification of the posterior longitudinal ligament resulting in ossified lesions in the upper cervical spine. World Neurosurg. 2019;127:e299-e310.
13. Pailhez G, Bulbena A, Fullana MA, Castaño J. Anxiety disorders and joint hypermobility syndrome: the role of collagen tissue. Gen Hosp Psychiatry. 2009;31(3):299.
14. Hudgins PA, Baugnon KL. Head and neck: skull base imaging. Neurosurgery. 2018;82(3):255-267.
15. Wong SH, Chiu KY, Yan CH. Review Article: Osteophytes. J Orthop Surg (Hong Kong). 2016;24(3):403-410.
16. Alberta FG, Aronow MS, Barrero M, Diaz-Doran V, Sullivan RJ, Adams DJ. Ligamentous Lisfranc joint injuries: a biomechanical comparison of dorsal plate and transarticular screw fixation. Foot Ankle Int. 2005;26(6):462-73.
17. Hawker GA, Mian S, Kendzerska T, French M. Grade Scale (CPGS), Short Form-36 Bodily Pain Scale (SF-36 BPS), and Measure of Intermittent and Constant Osteoarthritis Pain (ICOAP). Arthritis Care Res (Hoboken). 2011; 63(1):240–252.
18. Radanović B, Vučinić P, Janković T, Mahmutović E, Penjašković D. Musculoskeletal symptoms of the neck and shoulder among dental practitioners. J Back Musculoskelet Rehabil. 2017;30(4):675-679.
19. Vasil'ev YL, Rabinovich SA, Dydykin SS, Bogoyavlenskaya TA, Kashtanov AD, Kuznetsov AI. Evaluation of dentists regulatory systems stress during the provision of dental care according to pulse oximetry data. Stomatologiia (Mosk). 2020;99(6):89-93
20. Ambarwati T., Suroto, Wicaksena B., Sopianah Y., Miko H. Posture work to complaint musculoskeletal disorders at the dentist. Journal of International Dental and Medical Research. 2018;11(1):57-61.