

## Clinical and Radiographic Evaluation of Crestal Ridge Splitting Versus Osseodensification Techniques for Dental Implant Placement into the Narrow Alveolar Ridge

Ahmed Mohamed Bilal<sup>1\*</sup>, Mohamed Mohamed bioumy<sup>2</sup>, Akram Abbass Al-Awady<sup>3</sup>,  
Mahmoud Taha El-Destawy<sup>4</sup>, Mostafa Mohamed Hosny<sup>5</sup>

1. Assistant Lecturer, Department of Oral Medicine, Periodontology, Diagnosis and Oral Radiology Faculty of Dentistry, Al-Azhar University, Cairo -Egypt.
2. Professor, Department of Oral Medicine & Periodontology& Diagnosis and Oral Radiology, Faculty of Dental Medicine Al-Azhar University, Cairo -Egypt.
3. Professor, Department of Oral Medicine & Periodontology& Diagnosis and Oral Radiology, Faculty of Dental Medicine Al-Azhar University, Cairo-Egypt.
4. Associate Professor, Department of Oral Medicine & Periodontology& Diagnosis and Oral Radiology, Faculty of Dental Medicine Al-Azhar University, Cairo -Egypt.
5. Associate Professor, Department of Oral Medicine & Periodontology& Diagnosis and Oral Radiology, Faculty of Dental Medicine Al-Azhar University, Cairo -Egypt.

### Abstract

This study compared two modalities, crestal ridge splitting (CRS) and Osseodensification (OD) concerning implant stability, marginal bone level, and bone density.

20 patients were randomly divided into the CRS group (10 patients, 10 implants) and OD Group (10 patients, 10 implants). The CRS was performed using piezoelectric surgery while in the OD group Versah burs were used. Records of Implant stability quotient (ISQ) were obtained immediately after implant insertion and at four and six months. Moreover, marginal bone level and bone density were evaluated via postoperative cone-beam computed tomography (CBCT).

Clinically, the OD group showed increased postoperative ISQ scores at all observation intervals ( $p \leq 0.001$ ) compared with CRS one. Moreover, postoperative CBCT images of OD participants revealed lower marginal bone loss and higher bone density ( $p \leq 0.001$ ).

Following implant placement into the narrow alveolar ridge, the osseodensification modality displayed enhanced implant stability, increased bone density, and decreased marginal bone loss compared to the crestal ridge splitting one.

**Clinical article (J Int Dent Med Res 2022; 15(1): 205-211)**

**Keywords:** Osseodensification, piezoelectric surgery, Ridge Splitting, Implant Stability, CBCT.

**Received date:** 19 September 2021

**Accept date:** 01 November 2021

### Introduction

Inadequate alveolar ridge width is a common obstacle to conventional implant placement. The pattern of bone loss after dental extraction is well established.<sup>1-2</sup> The size of the labio-palatal bone crest decreases by 3.1 to 5.9 mm (approximately 50% of the original bone width) four to twelve months after tooth removal.<sup>3-5</sup>

There is a consensus that a minimum of six to seven mm. of bone width is needed for

implants with a diameter of 3.5 to 4 mm using the conventional surgical procedure.<sup>6</sup> The minimum width of bone ranged between 1 and 1.5 mm. required on both lingual/palatal sides of the implant is necessary for a predictable outcome.<sup>7,8</sup>

If a markedly reduced ridge width (< 5 mm at the apical and coronal sections of the implant) is found, two-steps surgical procedures using direct bone regeneration will become essential.<sup>9</sup>

A mixture of autologous bone and allogeneous material, autogenous block Onlay grafts harvested intraorally or from the hip region<sup>10</sup>, or horizontal distraction osteogenesis can be utilized<sup>11</sup>

Ridge splitting is an efficient way to fix horizontal ridge deformity. It provides the benefit of allowing simultaneous implant placement and reduces the morbidity associated with secondary surgical sites.<sup>12,13</sup>

#### \*Corresponding author:

Ahmed Mohamed Bilal  
Assistant Lecturer  
Department of Oral Medicine, Periodontology, Diagnosis and Oral Radiology  
Faculty of Dentistry, Al-Azhar University, Cairo -Egypt<sup>1</sup>  
E-mail: [ahmedbilal.209@azhar.edu.eg](mailto:ahmedbilal.209@azhar.edu.eg)

The region of the ridge where the cortical bony plates have been lateralized shows a reasonable tendency to normal healing by bone fill like green-stick fracture instead of fibrous tissue due to dual vascularity and dual cellular effect. Studies have shown that no need for bone grafting procedures or membrane when crestal ridge splitting is used, as the healing is close to bone fracture healing.<sup>14</sup>

Shorter treatment time, no need for donor sites, and the prospect of immediate implant placement are among the merits of alveolar ridge splitting over autogenous block graft. The minimum alveolar ridge width should be three mm. or more with at least one mm. trabecular bone between the two cortical plates of bone to allow for successful splitting with immediate implant placement.<sup>15</sup>

Splitting can be accomplished on the residual alveolar ridge, typically using mallet and chisel, ultra-fine fissure burs, surgical discs and lately utilizing piezoelectric surgical devices while osteotomies, chisels, spiral bone spreaders, and motor-driven expanders perform expansion. Piezo electrical surgery has many benefits, including selective bone cutting without influencing soft tissues, increased visibility during the procedure, and sectional cutting, while reducing unnecessary heat that can impair healing.<sup>16</sup>

Recently, Huwais<sup>17</sup> has introduced a new approach of biomechanical bone preparation called Osseodensification. It is created with Versah™ bursts, which are specially designed bursts. The burs are made to conserve and increase the quality of the intercortical bone and can be utilized in counterclockwise or clockwise ways to maximize the bone density and widen the osteotomy site without the extraction of the inter cortical bony matrix to obtain the advantage of viscoelastic bone qualities.<sup>18</sup>

These burs combine the benefits of manual osteotomes with the speed and tactile power of drilling procedures, and they can be used on low and moderate-density bones<sup>19</sup> According to the manufacturer, these uniquely designed burs showed the ability to expand narrow alveolar ridges like split crest techniques.<sup>20</sup>

## Materials and methods

Twenty patients between 22 to 45 years

of age were randomly allocated into two groups. The patients were assigned for simultaneous implant treatment either by osseodensification techniques or piezosurgery. The study was approved by the Institutional Review Board and the Ethical Research Committee of Al-Azhar University, Cairo, Egypt. **Ethical code:319/341**

### Patient selection

All the patients who took part in the study had no systemic conditions, maintained good oral hygiene, and were missing one tooth in the anterior maxillary arch with sufficient alveolar ridge height (8 mm). However, there was insufficient alveolar ridge width (3-5 mm) that interfered with traditional straightforward implant placement.

Smokers and patients with uncontrolled general conditions that could affect the surgical outcome were excluded from the study. All patients were explained about the nature of the surgical procedure conducted, and informed consent was obtained from every participant.

### Treatment protocol

The preoperative phase included case history, clinical evaluation, preoperative photographs, and the CBCT scan to determine the alveolar ridge morphology. Adequate periodontal management and oral hygiene motivation were given to all patients two weeks before the surgery. A single surgical procedure was performed on each patient, including alveolar ridge expansion/splitting with immediate implant placement.

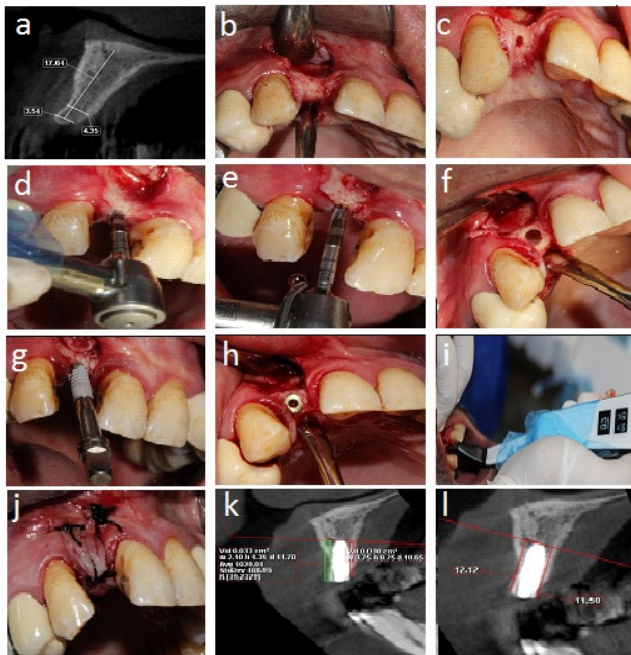
All surgeries were performed Under local anesthesia administration (Articaine hydrochloride 4% with 1/100000 epinephrine, septanest, Septodont). The patients were given premedication one hour before the surgery (amoxicillin 875mg/clavulanic acid 125 mg/Augmentin 1gm tablets) orally.

### Surgical procedures

A full-thickness mucoperiosteal flap was released labially and palatally at the edentulous area using one crestal incision and two vertical labial incisions.

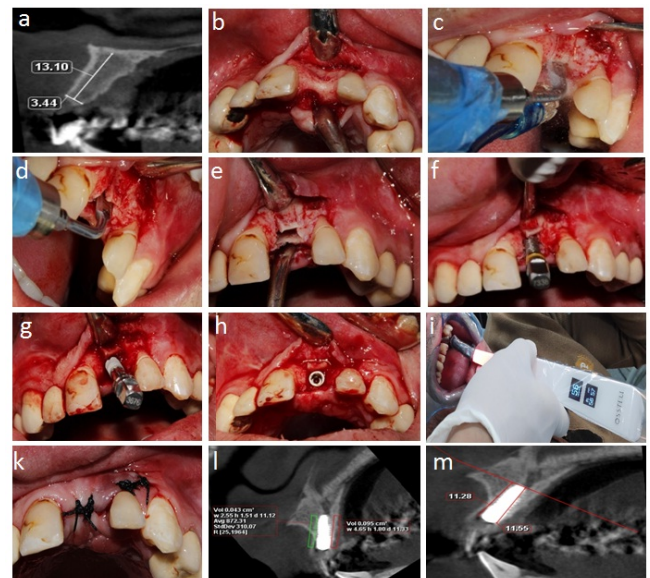
**Counter-clockwise osseodensification group:** Osseodensification technique using the pilot drill, then Versah Bur VT1828 (Versah™, LLC) streaming at 1200 RPM in a non-cutting (CCW) direction in a bouncing motion to enlarge the osteotomy 2.3 mm diameter to 8 mm length was performed. Sequential use of Versah Bur VT2535 running in a non-cutting CCW direction

(Densifying Mode) at 1200 RPM was utilized to expand the osteotomy to a 3.3 mm diameter and 8 mm length. Then, Versah Bur VT2838 (Densifying Mode) was used to expand the osteotomy to a 3.5 mm diameter followed by profuse saline irrigation (Figure 1).



**Figure 1.** Osseodensification technique (a) preoperative CBCT showing narrow ridge, (b) full-thickness flap released, and the bony ridge is exposed, (c) pilot drill of Versah bur, (d) sequential drilling, (e) final drill, (f) the osteotomy site, (g) implant installation, (h) implant with cover screw, (i) Osstell Beacon measurements, (j) flaps sutured together, (k) postoperative CBCT showing bone density, (l) Osstell Beacon measurements.

**Crestal ridge splitting group:** Segmental ridge-split procedure (SRSP) was performed as follows: horizontal crestal split using piezoelectric device tips (CS Series) sequentially starting from (CS1-6) (CS -1 diameter is 0.55 mm and CS-6 diameter is 3.75 mm), followed by two vertical bone releases to avoid fracture of the labial cortical plate of bone. After performing the crestal ridge split, small wedge, or spiral drills were used to expand the implant bed, finger pressure was applied on the two plates of bone during drilling procedures to provide stabilization to the facial plate of the bone (Figure 2).



**Figure 2.** Crestal ridge splitting (a) preoperative CBCT showing narrow ridge, (b) full-thickness flap released, and the bony ridge is exposed, (c) initial piezosurgery cutting tip (CS-1), (d) final piezo surgery cutting tip (CS-6), (e) bony crestal and “releasing” incisions, (f) spiral drill, (g) implant placement, (h) final implant position, (i) Osstell Beacon measurements, (j) flaps sutured together, (k) postoperative CBCT showing bone density, (l) postoperative CBCT showing crestal bone level.

### Implant placement

All the implants utilized in this study were the same size (3.5mm x 12mm) Nucleoss (T6) bone level implant the flaps were closed by simple interrupted sutures using 3/0 suture silk material. The sutures were removed two weeks later following surgery. patients were instructed to administer acetaminophen 1g every 8 hours. This was followed by a postoperative CBCT scan to evaluate the adequacy of the implant placement and for postoperative measurements.

### Clinical and radiographic assessment

Osstell Beacon® (integration diagnostics AB, Gutenberg, Sweden) was used to assess the implant stability immediately after surgery, and after four and six months. The ISQ was measured labially, palatally, distally, and mesially for each implant, and the mean value was calculated for each implant. The radiographic measurements were performed from the implant shoulder to the crest of the alveolar bone.



## Results

The implants' survival rate was 100% after one year of implant placement. Table 1 shows a comparison between the two studied groups according to ISQ. At baseline, 4, and 6 months, there was a statistically significant difference in mean ISQ in both groups. The osseodensification group showed a higher ISQ than the ridge splitting group at baseline, 4, and 6 months.

ISQ	Osseodensification	Ridge splitting	t	p
Baseline	87.70 ± 2.98	70.10 ± 2.13	15.179	<0.001*
4 months	80.0 ± 3.16	63.20 ± 2.10	14.00*	<0.001*
6 months	86.60 ± 3.41	68.80 ± 1.99	14.272*	<0.001*

**Table 1.** Comparison between the two studied groups according to ISQ.

t-Student t-test, pp-value for comparing between the studied groups  
 \*Statistically significant at p ≤ 0.05.

	Osseodensification	Ridge splitting	t	P
Labial Bone density (HU)				
Before	427.6 ± 47.58	435.9 ± 68.60	0.314	0.757
Immediate	613.2 ± 58.41	490.9 ± 74.15	4.097*	0.001*
6 months	670.1 ± 56.75	526.7 ± 74.33	4.849	<0.001*
% Change from Baseline to				
Immediate	44.04 ± 11.90	12.76 ± 2.93	8.073*	<0.001*
6 months	57.58 ± 13.34	21.25 ± 7.03	7.620*	<0.001*

**Table 2.** Comparison between the two studied groups according to labial of bone density (HU).

t-Student t-test, pp-value for comparing between the studied groups  
 \*Statistically significant at p ≤ 0.05

Change in labial marginal bone level (mm)	Osseodensification	Ridge splitting	U	p
immediate	-0.18 ± 0.16	-0.88 ± 0.17	0.000	0.002*
6 months	-0.43 ± 0.14	-1.28 ± 0.19	0.000	0.002*

**Table 3.** Comparison between the two studied groups according to change in labial of marginal bone level (mm).

U-Mann Whitney test, pp-value for comparing between the studied groups

\*Statistically significant at p ≤ 0.05

Table 2 presents a comparison of the two groups based on labial bone density (HU), preoperatively. There was a statistically non-significant difference in mean labial bone density (HU) for both groups. Contrarily, there was a statistically significant difference in mean HU between the groups at 6 months. The osseodensification group showed a higher HU than the ridge splitting group. Regarding %

change from baseline to immediate and to 6 months, the osseodensification group showed a higher % change than the ridge splitting group.

Table 3 shows the comparison between the two groups according to changes in labial marginal bone level (mm). Immediately and after six months of follow-ups, there was a statistically meaningful difference in mean labial marginal bone level (mm) in the two groups. The osseodensification group showed a less change in labial marginal bone level (mm) than the crestal ridge splitting group.

## Discussion

Inadequate ridge width is still a major barrier to successful implant placement. Ridge expansion/splitting is a good way to deal with the narrow alveolar width.<sup>21</sup> For a predictable outcome, a minimum bone width of 1 to 1.5 mm is required on both the labial and lingual/palatal aspects of the implant. Scipioni et.al.<sup>7</sup>

Over 4 to 12 months following dental extraction, the labio-palatal bone dimension at the crest decreases by (3.1 - 5.9mm). Approximately 40 percent of the original bone volume.<sup>22</sup> If a distinctly reduced ridge width is recognized (< 5 mm at the crestal and apical parts of the implant), in this situation two-stage surgical steps utilizing guided bone regeneration become mandatory.<sup>9</sup> A combination of autologous bone and allogeneous material,<sup>23</sup> autologous bone as block Onlay grafts harvested from intraoral sites as the chin or ramus or extra-orally from the ribs,<sup>24</sup> besides, horizontal distraction osteogenesis can be applied to the deficient alveolar ridges<sup>25</sup> before implant placement in case of regenerative procedures, a long healing period of several months is usually needed. Such procedures increase the costs, treatment time, and negatively affect patient morbidity.<sup>10</sup>

The alveolar ridge expansion/splitting techniques were first developed by Simion et.al.<sup>26</sup> Depends on the viscoelasticity of the alveolar bone & involves handling of the narrow alveolar ridge permitting the lateral displacement of the labial plate away from the palatal cortical plate of bone, allowing the implant installation in a deficient alveolar ridge width without bone removal.

Many advantages gained by ridge splitting/expansion procedures described by

Kaus & Sethi<sup>27</sup> as the possibility of simultaneous implant placement, no need for donor sites, and decreased treatment period are among the merits of alveolar ridge splitting technique versus bone block autogenous grafting.

The implant stability measurements could clinically be evaluated either in different ways by insertion torque value or by the utilization of radio frequency assay (RFA). The insertion torque measurements are a reliable method. However, it may evaluate only the primary stability during the implant insertion in contrast to (RFA), which is allowed at any period through the implant life as described by Trisi et.al.<sup>28</sup>

In the present comparative study, the implant stability was evaluated using Osstell® device. Regarding the primary implant stability in both groups showed a statistically significant difference in (ISQ) values between the two examined groups. Ridge splitting group the mean ISQ value at baseline was  $70.10 \pm 2.13$  versus the mean value of osseodensification  $87.70 \pm 2.98$ . ISQ value at four months was  $63.20 \pm 2.10$  versus the mean value of osseodensification  $80.0 \pm 3.16$ .

ISQ value at six months after the prosthetic installation was  $68.80 \pm 1.99$  versus mean value of osseodensification  $86.60 \pm 3.41$  this results following the findings of Lehan et.al.<sup>19</sup> who concluded that implant stability is higher with osseodensification as compared to other techniques since; the OD drilling technique greatly enhances the insertion torque which increases the primary implant stability.

Histometric findings after six weeks in vivo study show that the experimental Versah bur positively influenced osseointegration when utilized in either clockwise or counterclockwise directions. Besides, they concluded that regardless of the implant design; the newer osseodensification technique increases the primary stability of the implant and bone-to-implant contact. Lehan et.al.<sup>19</sup> concluded that the impact contributed to osseodensification of autogenous bone debris at the bony walls.

However, in other research, a comparison between Versah bur and piezosurgical osteotomies reported higher ISQ values, a smaller reduction in ISQ values, and an earlier transition from a decreasing to an increasing implant stability pattern and good comparable success rates in favour of Piezosurgery Vercellotti et.al.<sup>29,30</sup>

The mechanical competence of bone, which is referred to as bone quality in the field of implant dentistry, material properties, structural properties, and comprises bone mass<sup>31,32</sup>

Concerning bone density, the mean values were significantly parallel to stability values ridge splitting group the mean bone density value preoperatively was  $435.9 \pm 68.60$  versus the mean value of osseodensification  $427.6 \pm 47.58$ . The bone density values immediately after surgery were  $490.9 \pm 74.15$  versus the mean, the value of osseodensification  $613.2 \pm 58.41$ . Bone density at 6 months after the prosthetic installation was  $526.7 \pm 74.33$ . Versus mean, the value of osseodensification  $670.1 \pm 56.75$ .

At baseline, there was no statistically significant difference between bone densities in both groups. Immediately and 6 months after prosthesis installation, there was a statistically significant difference between bone densities, which was higher in the OD group than investigated in the ridge splitting group.

According to the above-mentioned values, the osseodensification technique appeared good as compared to the Piezosurgery technique as mentioned by Trisi et.al.<sup>20</sup> Since he explained the OD technique, leads to redistributing bone material on the osteotomy surface through plastic deformation using a slide of flutes through the surface of the bone with less compressive force than the final strength of the bone. Because fresh and hydrated trabecular bone is made of ductile material; it has a great extent for plastic deformation.

Crestal bone level surrounding dental implants has been considered one of the implant successes. The commonly used criteria for implant success should present with less than 1.5mm of crestal bone loss during the 1<sup>st</sup> year. Besides, less than 0.2 every year and a maximum of two mm. over five years as reported by Misch et al.<sup>33</sup>

Ridge splitting group the mean crestal bone level value at baseline was  $0.00 \pm 0.00$  versus the mean value of osseodensification  $0.00 \pm 0.00$ .

The mean crestal bone level value of the Ridge splitting group at six months was  $0.88 \pm 0.17$  versus the mean, value of osseodensification  $0.18 \pm 0.16$ . The mean crestal bone level value of the Ridge splitting group at 6 months after the prosthetic installation was  $1.28 \pm 0.19$ . In comparison to the mean, the value of osseodensification is  $0.43 \pm .14$ .

Besides, these findings were compatible with results obtained by Strietzel et al.<sup>34</sup> Who placed twenty-two implants by crestal Ridge splitting procedure, and during the follow-up of six months after placement, the mean value of crestal bone loss was 0.8 mm. Followed by six months of functional loading, the crestal bone loss on each side of the implants decreased by an average of 1.2 mm.

## Conclusions

The osseodensification technique showed the ability to manage narrow alveolar ridge, implant stability, and bone density around implants without bone fracture or fenestration. This study showed the amount of implant stability obtained with Versah bur was superior to piezosurgery.

## Declaration of Interest

The authors report no conflict of interest.

## References

1. Reich KM, Huber CD, Lippnig WR, Ulm C, Watzek G, Tangl S. Atrophy of the residual alveolar ridge following tooth loss in a historical population. *Oral Dis*. 2011 Jan;17(1):33–44.
2. Araújo MG, Lindhe J. Dimensional ridge alterations following tooth extraction. An experimental study in the dog. *J Clin Periodontol*. 2005 Feb;32(2):212–8.
3. Camargo PM, Lekovic V, Weinlaender M, Klokkevold PR, Kenney EB, Dimitrijevic B, et al. Influence of bioactive glass on changes in alveolar process dimensions after exodontia. *Oral Surg Oral Med Oral Pathol Oral Radiol Endod*. 2000 Nov;90(5):581–6.
4. Iasella JM, Greenwell H, Miller RL, Hill M, Drisko C, Bohra AA, et al. Ridge preservation with freeze-dried bone allograft and a collagen membrane compared to extraction alone for implant site development: a clinical and histologic study in humans. *J Periodontol*. 2003 Jul;74(7):990–9.
5. Schropp L, Wenzel J, Kostopoulos L, Karring T. Bone healing and soft tissue contour changes following single-tooth extraction: a clinical and radiographic 12-month prospective study. *Int J Periodontics Restorative Dent*. 2003 Aug;23(4):313–23.
6. Chiapasco M, Romeo E, Vogel G. Vertical distraction osteogenesis of edentulous ridges for improvement of oral implant positioning: a clinical report of preliminary results. *Int J Oral Maxillofac Implants*. 2001;16(1):43–51.
7. Scipioni A, Bruschi GB, Calesini G. The edentulous ridge expansion technique: a five-year study. *Int J Periodontics Restorative Dent*. 1994 Oct;14(5):451–9.
8. Suh J-J, Shelemay A, Choi S-H, Chai J-K. Alveolar ridge splitting: a new microsaw technique. *Int J Periodontics Restorative Dent*. 2005 Apr;25(2):165–71.
9. Jensen OT, Bell W, Cottam J. Osteoperiosteal flaps and local osteotomies for alveolar reconstruction. *Oral Maxillofac Surg Clin North Am*. 2010 Aug;22(3):331–46, vi.
10. Felice P, Pistilli R, Lizio G, Pellegrino G, Nisii A, Marchetti C. Inlay versus onlay iliac bone grafting in the atrophic posterior mandible: a prospective controlled clinical trial for the comparison of two techniques. *Clin Implant Dent Relat Res*. 2009 Oct;11 Suppl 1:e69–82.
11. Takahashi T, Funaki K, Shintani H, Haruoka T. Use of horizontal alveolar distraction osteogenesis for implant placement in a narrow alveolar ridge: a case report. *Int J Oral Maxillofac Implants*. 2004;19(2):291–4.
12. Koo S, Dibart S, Weber H-P. Ridge-splitting technique with simultaneous implant placement. *Compend Contin Educ Dent*. 2008 Mar;29(2):106–10.
13. Elian N, Jalbout Z, Ehrlich B, Classi A, Cho S-C, Al-Kahtani F, et al. A two-stage full-arch ridge expansion technique: review of the literature and clinical guidelines. *Implant Dent*. 2008 Mar;17(1):16–23.
14. Coatoam GW, Mariotti A. The Segmental Ridge-Split Procedure. *J Periodontol*. 2003 May;74(5):757–70.
15. Khairnar MS, Khairnar D, Bakshi K. Modified ridge splitting and bone expansion osteotomy for placement of the dental implant in the esthetic zone. *Contemporary clinical dentistry*. 2014. Vol. 5 (1):110–4.
16. Blus C, Szmukler-Moncler S. Split-crest and immediate implant placement with ultra-sonic bone surgery: a 3-year life-table analysis with 230 treated sites. *Clin Oral Implants Res*. 2006 Dec;17(6):700–7.
17. National Center for Biotechnology Information (2021). PubChem Patent Summary for US-2006111724-A1, Bone harvesting drill bit for oral surgery.
18. Huwais S, Meyer E. A Novel Osseous Densification Approach in Implant Osteotomy Preparation to Increase Biomechanical Primary Stability, Bone Mineral Density, and Bone-to-Implant Contact. *Int J Oral Maxillofac Implants*. 2017 Jan;32(1):27–36.
19. Lahens B, Neiva R, Tovar N, Alifrag AM, Jimbo R, Bonfante EA, et al. Biomechanical and histologic basis of osseodensification drilling for endosteal implant placement in low-density bone. An experimental study in sheep. *J Mech Behav Biomed Mater*. 2016;63:56–65.
20. Trisi P, Berardini M, Falco A, Podaliri Vulpiani M. New Osseodensification Implant Site Preparation Method to Increase Bone Density in Low-Density Bone: In Vivo Evaluation in Sheep. *Implant Dent*. 2016 Feb;25(1):24–31.
21. Aghaloo TL, Moy PK. Which hard tissue augmentation techniques are the most successful in furnishing bony support for implant placement? *Int J Oral Maxillofac Implants*. 2007;22 Suppl:49–70.
22. Goyal S, Iyer SS. Bone Manipulation Techniques. *Int J Clin Implant Dent*. 2009;(1):22–31.
23. Friberg B, Sennerby L, Linden B, Gröndahl K, Lekholm U. Stability measurements of one-stage Brånemark implants during healing in mandibles. A clinical resonance frequency analysis study. *Int J Oral Maxillofac Surg*. 1999 Aug;28(4):266–72.
24. Chiapasco M, Zaniboni M, Rimondini L. Autogenous onlay bone grafts vs. alveolar distraction osteogenesis for the correction of vertically deficient edentulous ridges: a 2–4-year prospective study on humans. *Clin Oral Implants Res*. 2007 Aug;18(4):432–40.
25. Yamauchi K, Takahashi T, Nogami S, Kataoka Y, Miyamoto I, Funaki K. Horizontal alveolar distraction osteogenesis for dental implant: long-term results. *Clin Oral Implants Res*. 2013 May;24(5):563–8.
26. Simion M, Baldoni M, Zaffe D. Jawbone enlargement using immediate implant placement associated with a split-crest technique and guided tissue regeneration. *Int J Periodontics Restorative Dent*. 1992;12(6):462–73.
27. Sethi A, Kaus T. Maxillary ridge expansion with simultaneous implant placement: 5-year results of an ongoing clinical study. *Int J Oral Maxillofac Implants*. 2000;15(4):491–9.
28. Trisi P, Perfetti G, Baldoni E, Berardi D, Colagiovanni M, Scogna G. Implant micromotion is related to peak insertion torque and bone density. *Clin Oral Implants Res*. 2009 May;20(5):467–71.
29. Stelzle F, Neukam FW, Nkenke E. Load-dependent heat development, thermal effects, duration, and soft-tissue

- preservation in piezosurgical implant site preparation: An experimental ex vivo study. *Int J Oral Maxillofac Implants.* 2012;27(3):513–51322.
30. Vercellotti T, Stacchi C, Russo C, Rebaudi A, Vincenzi G, Pratella U, et al. Ultrasonic implant site preparation using piezosurgery: a multicenter case series study analyzing 3,579 implants with a 1- to 3-year follow-up. *Int J Periodontics Restorative Dent.* 2014;34(1):11–8.
  31. Felsenberg D, Boonen S. The bone quality framework: determinants of bone strength and their interrelationships, and implications for osteoporosis management. *Clin Ther.* 2005 Jan;27(1):1–11.
  32. Bouxsein ML. Bone quality: where do we go from here? *Osteoporos Int a J Establ as result Coop Between Eur Found Osteoporos Natl Osteoporos Found USA.* 2003 Sep;14 Suppl 5:S118-27.
  33. Misch CE, Perel ML, Wang H-L, Sammartino G, Galindo-Moreno P, Trisi P, et al. Implant success, survival, and failure: the International Congress of Oral Implantologists (ICOI) Pisa Consensus Conference. *Implant Dent.* 2008 Mar;17(1):5–15.
  34. Strietzel FP, Nowak M, Küchler I, Friedmann A. Peri-implant alveolar bone loss with respect to bone quality after use of the osteotome technique: Results of a retrospective study. *Clin Oral Implants Res.* 2002 Oct;13(5):508–13.