Fixation Sequence in a Patient with Multiple Mandibular and Midface Fractures: A Case Report

Vera Julia[1]*, Andrianto Soeprapto[1], Wenny Yulvie[2], Dwi Ariawan[1], Lilies Dwi Sulistyani[1]

1. Department of Oral and Maxillofacial Surgery, Faculty of Dentistry, Universitas Indonesia, Jakarta, Indonesia.
2. Department of Oral and Maxillofacial Surgery, Ciptomangunkusumo Hospital, Jakarta, Indonesia.

Abstract

Herein, we describe the management of multiple mandibular and midface fractures using the "bottom-up," "tooth-bearing–non-tooth-bearing," and "outside–inside" fixation sequence in an 18-year-old female. The patient presented with a Le Fort I fracture along with fractures in the left mandibular body, left condyle, right mandibular angle (comminuted fracture), inferior orbital rim (bilateral), and left zygomaticomaxillary complex. Open reduction internal fixation and wire intermaxillary fixation were performed. Miniplates were placed in the inferior border of the mandible and superior to the mental foramen in the left mandibular body using an intraoral approach. The right mandibular angle fracture was fixed using a reconstruction plate in the inferior border of the mandible and a miniplate 2.0 to maintain the position of the comminuted bone fragments. Miniplates were placed on the anterior and posterior parts of the left condyle using a preauricular approach. For the midface fractures, plates 1.5 were placed on the frontozygomatic fracture line and the left inferior orbital rim using a subciliary approach with a lateral extension. "L" plates were fixed on the zygomaticomaxillary and nasomaxillary buttresses. Satisfactory aesthetic and functional outcomes were obtained after using the "bottom-up," "tooth-bearing–non-tooth-bearing," and "outside–inside" fixation sequence in this case.

Case report (J Int Dent Med Res 2022; 15(1): 291-296)

Keywords: Fixation Sequence, Complex Facial Fracture, Open Reduction Internal Fixation, Fractures, Bone

Received date: 15 September 2021 **Accept date:** 12 October 2021

Introduction

The increase in population and advances in technology have led to an increase in the incidence of injuries, particularly facial injuries. Data from the National Trauma Data Bank (2016) reported that 24.91% of all injuries were facial injuries.[1–4] Road traffic accidents (73.8%) were the most common cause of facial injuries, followed by falls, assaults, sports, and industrial accidents. Facial injuries involve either the soft or hard tissues. Facial fractures can be classified into 3 types (upper face, midface, and lower face) based on the region involved, and if it involves all 3 facial regions, it is called a panfacial fracture. The most common fracture site is the mandible (39.89%), followed by the zygomatic, maxillary, nasal, orbital, and naso-orbito-ethmoid (NOE) bones.[1,5–13]

The treatment of facial fractures remains a challenge, and it is difficult for oral and maxillofacial surgeons to reconstruct the face following the loss of anatomical landmarks, particularly in complex cases. Restoration of both function and aesthetics is the main goal of facial fracture management. Failure to achieve proper reduction leads to facial deformity. Various fixation sequences such as the "bottom-up," "top-down," "outside–inside," and "inside–outside" methods are used for the management of facial fractures. The sequencing serves as a guideline for the stepwise management of the fracture and aids in achieving facial symmetry.[10,11,14–16]

In this report, we describe the management of multiple mandibular and midface fractures using the "bottom-up," "tooth-bearing–non-tooth-bearing," and "outside–inside" fixation sequence in an 18-year-old female.

Corresponding author:
Vera Julia
Department of Oral and Maxillofacial Surgery, Faculty of Dentistry, Universitas Indonesia
Salemba Raya 4, Central Jakarta, Jakarta, 10430, Indonesia
E-mail: vera.julia@ui.ac.id

Case Report

An 18-year-old female patient came to the emergency room of Cipto Mangunkusumo

National General Hospital in Jakarta, Indonesia, with facial pain and asymmetry 6 h after a motorcycle accident. She was riding a motorcycle at a speed of 60 km/h and had worn a half-face helmet. She lost her balance after hitting a rock and crashed into a wall with her face hitting the wall first. She did not report any loss of consciousness or retrograde amnesia but experienced dizziness, nausea, and vomiting. The patient had no history of diabetes mellitus, hypertension, heart disease, respiratory disease, or allergies.

Figure 1. Images of the patient after the accident. (A), (B), (C), (D), and (E) showed facial asymmetry, periorbital hematoma, left malar eminence flattening and menton laceration. (F) Mouth opening of 15 mm.

The following features were observed after extraoral examination: facial asymmetry, bilateral periorbital hematoma, left orbital subconjunctival hemorrhage, left malar eminence flattening, a mouth opening of 15 mm, menton lacerations, palpable discontinuity in the left mandibular body and right mandibular angle, and tenderness in the left tragus, bilateral maxilla, and zygomatic bones. The patient's vision was normal. Diplopia, enophthalmos, hypoglobus, telecanthus, and limited eye movements were not observed. Intraoral examination revealed the presence of anterior and posterior open bite on the right side, avulsion of the mandibular left second premolar, a floating maxilla, and palpable discontinuity in the alveolar region of the mandibular second premolar on the left side and mandibular angle on the right side.

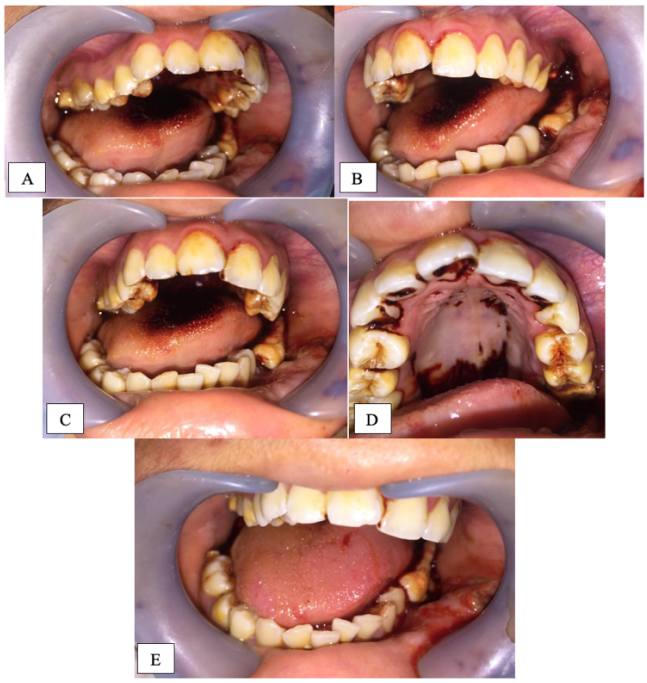

Figure 2. Intraoral findings. (A), (B), and (C) showed anterior and posterior open bite on the right side. (D) Floating maxilla without guerin sign. (E) Avulsion of the mandibular left second premolar.

Figure 3. Three-dimensional CT scan images of the patient.

Radiological examinations of the skull along with orthopantomogram and computed tomography (CT) scans of the face revealed the presence of a left mandibular body fracture, left condyle fracture, right mandibular angle comminuted fracture, Le Fort I fracture, bilateral inferior orbital rim fracture, and left zygomaticomaxillary complex (ZMC) fracture. Cerebral contusion was observed, and there was no specific treatment. Arch bars were placed on the maxilla and mandible using elastic intermaxillary fixation (IMF) under local anesthesia. Seven days later, the patient underwent open reduction internal fixation surgery under general anesthesia with nasal intubation.

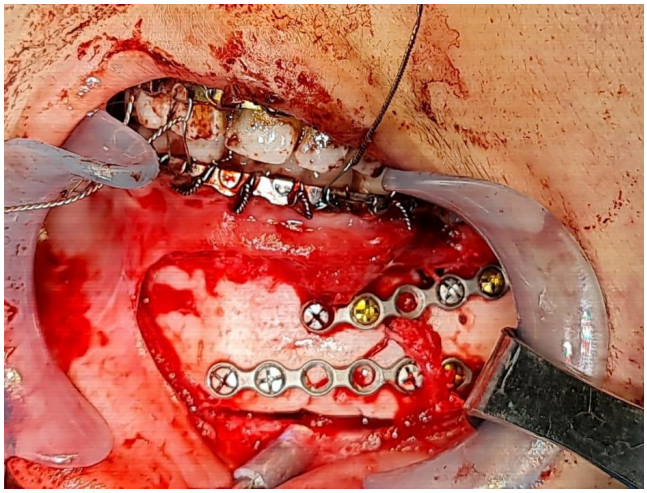

Figure 4. The fixation of the left mandibular body fracture.

Antiseptic and aseptic procedures were performed, and the “bottom-up,” “tooth-bearing–non-tooth-bearing,” and “outside–inside” fixation sequence was applied. First, an intraoral approach was used to access the left mandibular body fracture, followed by a reduction of the fracture fragment to the anatomical position and IMF using a 0.4 wire. Left mandibular body fracture was fixed using 2 miniplates 2.0 placed at the inferior border of the mandible and superior to the mental foramen. The submandibular approach was used to access the comminuted fracture of the mandibular angle on the right side. After reduction to the anatomical position, the right mandibular angle fracture was fixed using a reconstruction plate 2.3 in the region of the inferior border of the mandible and a miniplate 2.0 to maintain the position of the comminuted bone fragments superiorly. A preauricular approach was used to access the left condylar fracture, which was fixed using two miniplates 2.0 placed anterior and posterior to the neck of the condyle.

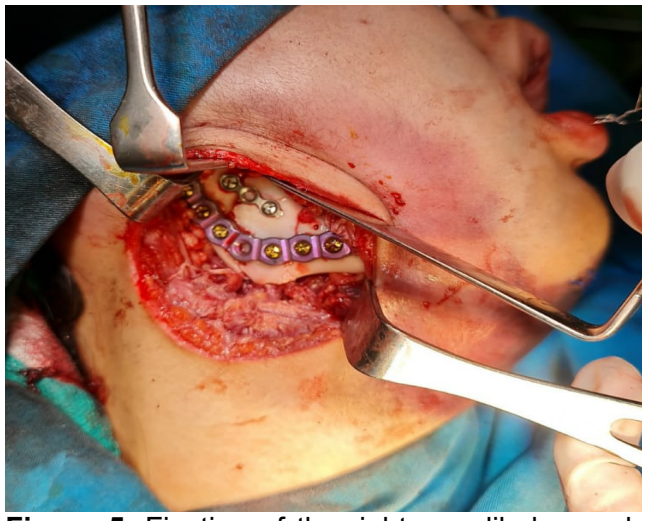

Figure 5. Fixation of the right mandibular angle comminuted fracture.

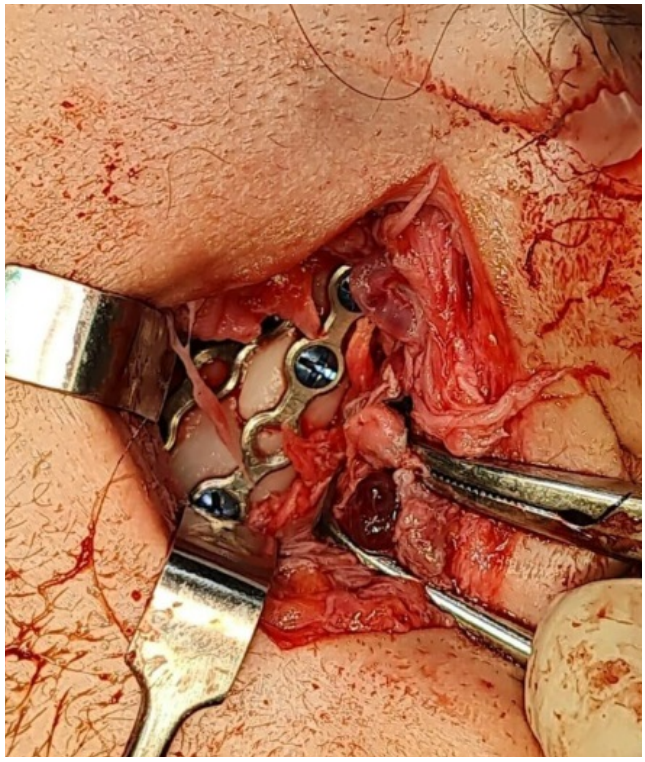

Figure 6. Fixation of the left condylar fracture.

The intraoral and subciliary approach with lateral extension was used to access the midface fractures. Reduction of the fracture fragment of the zygomaticomaxillary complex (ZMC) was performed using a Carrol-Girard T-Bar Screw. The fixation was performed by placing a plate 1.5

on the left frontozygomatic fracture line and another plate 1.5 on the left inferior orbital rim fracture line.

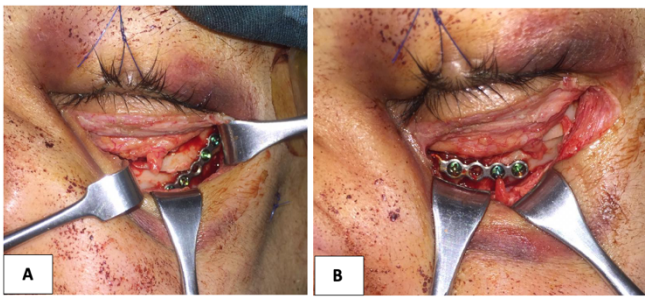

Figure 7. Fixation of the ZMC fracture. (A) Fixation of the left frontozygomatic fracture line. (B) Fixation of the left inferior orbital rim fracture line.

Figure 8. Fixation of the Le Fort 1 fracture.

Figure 9. The postoperative occlusion.

The wire IMF was temporarily removed to reduce the Le Fort I fracture fragment using Rowe disimpaction forceps. A 0.4 mm wire was used to reduce the maxillo-mandibular complex to its anatomical position. An “L” plate 1.5 was fixed onto the zygomaticomaxillary buttress and nasomaxillary buttress, followed by the closure of the surgical wound. Postoperative controls were performed every week, and the IMF wirewas removed after 6 weeks. The patient was satisfied with the results of the operation, both aesthetically and functionally.

Figure 10. Image of the patient 3 weeks after the surgery.

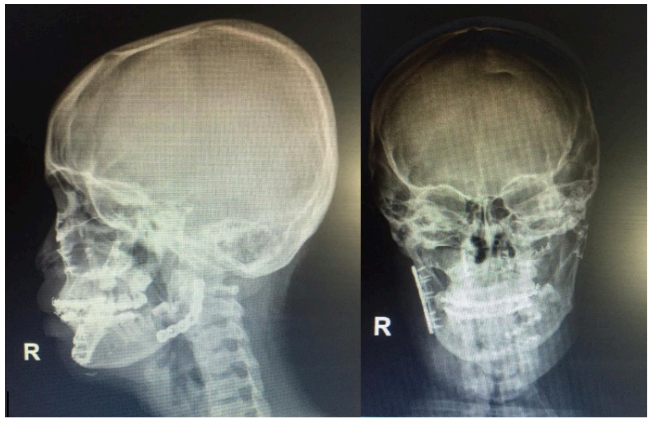

Figure 11. Postoperative radiographic images of the patient.

Discussion

Reduction of the bones to establish the facial skeletal framework by restoring the anatomical integrity of the facial buttress is the main goal of facial fracture management. Currently, these fractures are managed with open reduction and titanium plate fixation to stimulate osteosynthesis. The reduction and fixation of the plate on the transverse buttress restore the width of the face, whereas those on the vertical buttress restore the height of the face. The management of complex facial fractures remains a challenge for oral and maxillofacial surgeons due to the loss of reliable anatomical landmarks.[4,10,11,14,15,17,18]

There is no standard protocol for the management of facial fractures. Various sequences of fixation such as “bottom-up,” “top-down,” “outside–inside,” and “inside–outside” have been used for the management of facial fractures to help in achieving aesthetic and functional outcomes. The combination of the “bottom-up” and “outside–inside” methods is the most widely used. The mandible is a strong and isolated facial bone that can act as a stable base for the reconstruction of the facial skeleton. In addition, the mandible interacts with the maxilla via occlusion and the cranial base through the temporomandibular joint, thereby helping in ensuring the continuity of the lower face with the entire facial skeleton. Hence, the use of mandibular fixation as the first sequence will aid in determining the width, height, and projection of the lower face. After the “bottom-up” sequence, midface fixation involves the use of “outside–inside” sequencing, which starts from the ZMC toward the NOE region. This is because the ZMC is a more definitive anatomical landmark than the NOE and it provides the outer facial framework for the midface width and upper facial projection. In the present case report, fixation from the ZMC to the medial part of the midface provided lateral pillar stability and control over the transverse and anteroposterior dimensions, thereby preventing the development of facial asymmetry.[14,16,19–21]

By contrast, Clauser et al. used “top-down” sequencing as an immediate intervention method in a patient with traumatic dislocation of the right globe with the elongation of the optic nerve and the presence of a deep laceration in the midface region. Both “top-down” and “inside–outside” sequencing have been used in the past because they served as a stable basis for lateral projection and facial width.[15] Ramakrishnan et al. (2020) reported difficulties in repositioning bone fragments using the “top-down” sequence and suggested that excessive pressure could lead to failure of internal fixation. “Top-down” sequencing may be used in the case with accompanying neurosurgical procedures. Some authors suggest that “inside–outside” sequencing with a stable frontal bone can provide a reliable anatomical landmark for NOE fixation. However, the NOE fragments are fragile and difficult to fix even with a stable base.[14,15]

In this study, we used the “bottom-up” sequence to manage the facial fractures. First, the mandible was fixed to obtain a stable base in the lower face and occlusion with the maxilla. For mandibular reconstruction, the left mandibular body was fixed, followed by the right mandibular angle and the left condyle. Additionally, “tooth-bearing–non-tooth-bearing” sequencing was used as described by Marciani et al., who stated that both occlusion and continuity of the alveolar ridge were restored first, followed by the body and angle of the mandible, and finally, the vertical height by fixing the ramus and condyle of the mandible.[22] “Outside–inside” sequencing was used to reconstruct the midface region. The ZMC was fixed to obtain a symmetrical facial width, followed by the Le Fort I fracture fixation. Vujcich and Gebauer (2018) recommended the use of “bottom-up” and “outside–inside” sequencing.[23] In the current study, “outside–inside” sequencing was performed along with ZMC fixation before the fixation of the central components (such as NOE). The fixation of the maxilla was performed at the end. Thus, as reported previously, aesthetic and functional results can be achieved using “bottom-up,” “tooth-bearing–non-tooth-bearing,” and “outside–inside” sequencing fixation.[10,14,22,24]

Conclusions

The management of facial fractures is challenging for oral and maxillofacial surgeons. As shown in this case study, the use of the “bottom-up,” “tooth-bearing–non-tooth-bearing,” and “outside–inside” fixation sequence can aid in achieving a stable base along with both aesthetic facial dimensions and good stomatognathic functions.

Declaration of Interest

The authors declare that is no conflict of interest.

References

1. Samieirad S, Aboutorabzade M, Tohidi E, et al. Maxillofacial Fracture Epidemiology and Treatment Plans in The Northeast of Iran: A Retrospective Study. *Med Oral Patol Oral Cir Bucal* 2017;22(5):e616-24.
2. Chang MC, Stewart RM, Rotondo MF, Nathens AB. National Trauma Bank Data Annual Report. American College of Surgeons 2016. Available at: "https://www.facs.org/~/media/files/quality%2520programs/trauma/ntdb/ntdb%2520annual%25 20report%25202016.ashx". Accessed July 24, 2021.
3. Wu J, Min A, Wang W, Su T. Trends in The Incidence, Prevalence and Years Lived With Disability of Facial Fracture at Global, Regional and National Levels From 1990 to 2017. *PeerJ* 2021;9: e10693.
4. Choi J, Lorenz HP, Spain DA. Review of Facial Trauma Management. *J Trauma Acute Care Surg*. 2020;88(4):e124-30.
5. Wusiman P, Maimaitituerxun B, Saimaiti A, Moming A. Epidemiology and Pattern of Oral and Maxillofacial Trauma. *J Craniofac Surg* 2020;31(5):517-20.
6. Singaram M, Sree Vijayabala, Udhayakumar RK. Prevalence, Pattern, Etiology, and Management of Maxillofacial Trauma in A Developing Country: A Retrospective Study. *J Korean Assoc Oral Maxillofac Surg* 2016;42(4):174-81.
7. Younis M, Bhaskaran M. Prevalence and Patterns of Maxillofacial Fractures - A Retrospective Descriptive Study of 188 Cases. *Int J Contemp Med Res* 2020;7(9):11-4.
8. Lalloo R, Lucchesi LR, Bisignano C, et al. Epidemiology of Facial Fractures: Incidence, Prevalence and Years Lived With Disability Estimates From The Global Burden of Disease 2017 Study. *Inj Prev* 2020;26(Supp 1):i27-35.
9. Al-Hassani A, Ahmad K, El-Menyar A, et al. Prevalence and Patterns of Maxillofacial Trauma: A Retrospective Descriptive Study. *Eur J Trauma Emerg Surg*. 2019.
10. Abouchadi A, Taoufik H, Nacir O, Arrob A. Pan-Facial Fractures : A Retrospective Study and Review of Literature. *Open J Stomatol* 2018;8(4):110-119.
11. Ali K, Lettieri SC. Management of Panfacial Fracture. *Semin Plast Surg* 2017;31(2):108-17.
12. Taiwo AO, Soyele OO, Godwin NU, Ibikunle AA. Facial Fracture Management in Northwest Nigeria. *J Surg Tech Case Rep* 2013;5(2):65-71.
13. Haliti N, Shabani R, Mrasori S, et al. Teeth and Soft Tissue Injuries as Well as Wound Healing Quality Patterns Among Primary School Students of Prishtina Region. *J Int Dent Med Res* 2020;13(2):689-96.
14. Ramakrishnan K, Palanivel I, Narayanan V, Chandran S, Narayanan J. Sequencing of Fixation in Panfacial Fracture : A Systematic Review. *J Maxillofac Oral Surg* 2021;20(2):180-8.
15. Kim J, Choi J-H, Chung YK, Kim SW. Panfacial Bone Fracture and Medial to Lateral Approach. *Arch Craniofac Surg*. 2016;17(4):181-5.
16. Daniels JS, Albakry I, Braimah RO, et al. Experience with Airway Management and Sequencing of Repair of Panfacial Fractures : A Single Tertiary Healthcare Appraisal in Najran, Kingdom of Saudi Arabia - A Retrospective Study. *Ann Maxillofac Surg* 2020;10(2):402-8.
17. Corputty JE, Saputra FE. The Evaluation of Delayed Treatment on Dentoalveolar Trauma by Surgical Reposition and Wire-Composite Splint Technique. *J Int Dent Med Res* 2017;10(2):384-91.
18. Rajali A, Zulkifeli NRN, Elias ASM, Mansur NAH, Hamat NHW, Amin SRA. Sports-Related Dental Injury From The Perspective of Malaysian Athletes. *J Int Dent Med Res* 2020;13(2):674-81.
19. Sharma S, Dhanasekaran V. Surgical Approaches and Management of Panfacial Trauma: A Case Report. *J Clin Diagn Res* 2015;9(8):ZD13-4.
20. Mccormick RS, Putnam G. The Management of Facial Trauma. *Surgery* 2018;36(10):587-94.
21. De Melo WM, Sonoda CK, Shinohara EH, Garcia IR. Using The “Bottom-Up and Outside-In” Sequence For Panfacial Fracture Management. *J Craniofac Surg* 2013;24(5):e479-81.
22. Ebenezer V, Mohan R. Pan Facial Fracture - A Case Report. *Eur J Mol Clin Med* 2020;7(4):1505-8.
23. Vujcich N, Gebauer D. Current and Evolving Trends in The Management of Facial Fractures. *Aust Dent J* 2018;63 Supplement 1:S35-47.
24. Koraitim M. Panfacial Fractures Management. *J Craniofac Surg* 2020;31(4):e329-31.