Computer-aided Design and Computer-aided Manufacturing Fabricated Polyoxymethylene used for Maxillary Removable Partial Denture Framework

Pranmas Teeranuwat[1], Chutimon Jindachua[1], Pimduen Rungsiyakull[1], Pisaisit Chaijareenont[1,2]*

1. Department of Prosthodontics, Faculty of Dentistry, Chiangmai university, Chiangmai, Thailand.
2. Research Center of Pharmaceutical Nanotechnology, Chiang Mai University, Chiang Mai, Thailand.

Abstract

The increasing need for a dental substitution of partially edentulous has resulted in the development of removable partial denture (RPD) material and fabrication technique. Polyoxymethylene (POM) or acetal resin is one of an interesting alternative material for RPDs due to superior esthetics, high strength, elasticity and lightweight. Furthermore, POM is available to design and fabricate using computer-aided design and computer-aided manufacturing (CAD-CAM) systems that are used for RPDs fabrication due to more simple procedure and more accurate fit compare to the conventional. The aim of this case report was to describe the treatment for upper partially dentate patient who had no desirable of metal-color and heavyweight denture.

POM was chosen as a RPD framework material and combined CAD-CAM system in design and fabrication. 3D model was scanned from master cast owing to higher precise technique for capturing the physiologic extension in tissue-borne RPDs. The framework component was similar to conventional RPDs. Nonetheless, differences are the thickness of all components must be 2.0 mm for adequate strength of denture and except for direct retainers that should be thicker (1.5 mm) and engage deeper undercut (0.5 mm) than metal clasp. Air abrasion on POM which is low surface energy material, must be done to increase surface area on account of being main adhesion between framework and polymethylmethacrylate of mechanical retention.

The combination of CAD-CAM technique and POM block in fabrication of maxillary RPD framework resulted in accurate fit of denture; more lightweight and more pleasurable wear as a non-metal denture. After 1 year of use, denture revealed well-condition and proper function.

Using POM for RPD framework in this article showed patient satisfaction on the appearance with no metal display and also lighter weight of denture. The fabrication technique was a convenient method and created precisely fitting of denture framework led to reduction of insertion time.

Case Report (J Int Dent Med Res 2022; 15(1): 306-311)

Keywords: Acetal, CAD/CAM, Polyoxymethylene, Prosthodontics, Removable partial denture.

Received date: 30 November 2021 **Accept date:** 28 December 2022

Introduction

The growing number of elderly persons in the global population and increased life expectancy has resulted in a greater proportion of partially dentate adults.[1-3] The objective of replacing teeth and associated structures is to improve appearance and masticatory efficiency, to prevent undesirable tooth migration and to improve phonetics.[4] Removable partial denture (RPD), one of the favorable options, is chosen by dentists when the length of edentulous ridge contraindicates a fixed partial dentures, as ridge support is needed, or there is a guarded prognosis of their periodontal condition. In addition, the advantage of RPDs is to overcome financial constraints and provide more convenient hygiene access.[1, 5] Several studies have indicated that an unaesthetic appearance is a component of RPDs, leading to prosthetic failure.[3, 6] To overcome esthetic issues, the denture fabricated technique and materials were developed.

The problems of RPDs include: patient dissatisfaction, compromised function, esthetics and oral health.[7] Therefore, for success of RPDs,

Corresponding author:
Pisaisit Chaijareenont, DDS, PhD,
Department of Prosthodontics, Faculty of dentistry, Chiangmai university, Suthep road, Suthep, Muang, Chiangmai, Thailand, 50200.
E-mail: pisaisit.c@cmu.ac.th

it is important to minimizing future problems by accurately planning and custom fabrication for individual patient's need.[5] The conventional RPDs fabrication process uses direct waxing method to design a stone cast. Nowadays, Computer-aided design and computer-aided manufacturing (CAD-CAM) systems are widely used in dentistry to fixed restoration, implant and to design and fabricate a removable prostheses. While the conventional fabrication of RPDs is complex, error-prone and time consuming; CAD-CAM technique using milling technique in denture fabrication was proven to be better in accuracy than conventional technique.[8]

Metal-based dentures have been replaced with high-performance polymers because of the unesthetics metal-color, heavy weight and metal allergies of the patient.[9] Contrastingly, polymers is metal-free material which have better esthetics, higher elasticity and are lightweight. Apart from properties, interest in polymers has grown due to their ease of fabrication by using CAD-CAM technique. There are various types of polymers that suitable for denture fabrication that was used for decade such as polyamide, polyoxymethylene (POM) and polyetheretherketone (PEEK). A case report of using PEEK as a framework of denture indicated good denture adaptation and patient's satisfaction of lightweight of denture.[10] Polyoxymethylene or acetal resin is formed by polymerizing formaldehyde. POM has been widely used in the automotive industry and become competitive with metal.[11] Because of high percentages crystallinity, POM shows high stiffness, high fatigue resistance and good appearance.[11, 12] POM is higher wear resistance, fracture toughness and microhardness in comparison with polymethylmethacrylate (PMMA).[13, 14] Furthermore, POM has been used in medical field as an implant material because of good biocompatibility, chemical and thermal stability.[12, 15] In 1986, it was first used in dentistry as an alternative material for denture base and denture clasp owing to its superior esthetics and strength.[16] In use as a clasp, POM clasps had no deformation while a metal clasps loose retention, although previous studies revealed that POM had lower retention than metal.[17] However, the increasing of thickness and undercut of POM clasp provide sufficient retention in clinical use.[18] Furthermore, POM had low water and color stainning.[19, 20] Thus, the use of POM as a clasp has adequate scientific evidence without any controversy. At present, POM is available in CAD-CAM blanks that are appropriate for digital dentistry era. The property of materials used for removable partial denture framework is compared in table 1.

Properties	Ideal requirement	Type of materials		
		Metal alloy	Polymethylmethacrylate (PMMA)	Acetal resin
Biological	Biocompatible	Allergic to metal	Allergic to monomer	Biocompatible
Mechanical	High Modulus of elasticity	Modulus of elasticity		
		100-220 GPa	3-5 GPa	3-5GPa
	High Flexural strength	Flexural strength		
		~ 2500 MPa	~70 MPa	~120MPa
Physicals	High Thermal conductivity	Thermal conductivity		
		9.4 W/m.K	0.21 W/m.K	0.3-037 W/m.K
	Water absorption	Water Sorption		
		-	15 μg/mm³	4-14 μg/mm³
Others	Good esthetic	Metal color	Nearly natural tooth and tissue color	More color and vary opacity
	Low cost	Higher cost than PMMA	Low cost	High cost
	Light weight	Density		
		8 g/cm³	1.19 g/cm³	1.4-1.5 g/cm³

Table 1. Comparison of property of material used for removable partial denture framework.[4, 19, 23, 32, 33]

Because of strength limitations of POM, which are superior to PMMA but inferior to metal, the use as a framework particularly in tissue-supported RPDs is controversial.[21, 22] Nevertheless, as POM's material properties are considered to have passed ISO standards, it can be used as a denture base material.[19, 23]

This clinical case report describes the treatment of a patient who was partially dentate and had no desire to use metal as a denture material. The treatment used POM as a framework material to combine with CAD-CAM system in designing and fabricating removable partial denture.

Case Report

A 62- year-old Thai male came to see a dentist at Prosthodontics Clinic, Faculty of Dentistry, Chiang Mai University with a complaint of poor previous denture and pain during mastication. Past medical history showed the patient had high blood pressure and gout with sulfa allergies. The patient's expectation was to receive a functional, lightweight and no display of metal prosthesis. During the Intraoral examination (figure 1A-1C), the following

problems were noted: poor acrylic fixed protheses , permanent maxillary left lateral incisor, permanent maxillary left canine, permanent maxillary left first molar and permanent mandibular left first molar were missing, generalized abrasion at buccal side of tooth, dental caries, defective restorations with dental caries exposed pulp, periodontal pockets were founded at some teeth around 4-7 mm, gingival recession at facial aspect of anterior teeth and good condition of full metal crown of permanent mandibular right first and second molar. The relation of anterior teeth was edge-to-edge. The patient showed group function occlusal relationship bilaterally with no parafunction habit. The patient's smile fully exhibited average smile line. A panoramic radiograph revealed generalized acceptable alveolar bone level.

Figure 1. Initial oral examination. (A) Frontal view. (B) Maxillary occlusal view. (C) Mandibular occlusal view with existing fixed partial denture at 36 area.

Diagnosis: A facebow (Hanau Springbow, Water Pik, Fort Collins, USA) was used to help mount a diagnostic cast onto semi-adjustable articulator (Hanau Modular Articulator, Whip Mix, Louisville, USA). An interocclusal record was made with the aid of a Lucia jig and polyvinylsiloxane occlusal registration material (EXABITE II, GC, Tokyo, Japan). This process was important to evaluate the available interarch space and to determine the appropriate surfaces of teeth to place rest seat.

Treatment procedure: After completed emergency and hygienic treatment, teeth preparation was performed for zirconia crown with space available for rest seat and proper contour for RPD as a plan in diagnostic waxing and final impressions were made with polyvinylsiloxane impression material (Extrude, Kerr, Romulus, Germany). Zirconia crown (Katana Zirconia ML, Kuraray Noritake Dental, Aichi, Japan) were made at the position in existing vertical dimension and appropriate contour and rest seat and cemented with resin cement (RelyX U200, 3M ESPE Dental, USA) as shown in figure 2A. Stock tray with irreversible hydrocolloid impression material (Kromopan, Lascod, Florence, Italy) was used for the final impression of upper RPD, an interocclusal record was made with polyvinylsiloxane occlusal registration material (EXABITE II, GC, Tokyo, Japan), subsequently a facebow record was transferred from patient's face. After the master cast was poured and surveyed by using a surveyor, upper RPD was designed and determined rests and clasps position (figure 2B). Master cast and antagonist cast were mounted in semi-adjustable articulator.

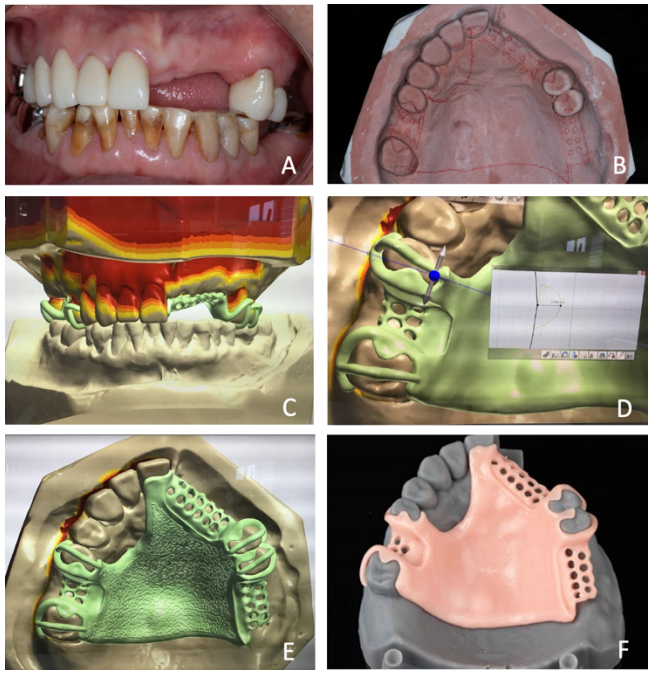

Figure 2. (A) After crowns permanent fixed. (B) Master cast with RPD design. (C) 3D model with digital survey line and framework. (D) Determined thickness of retentive clasp using software (3shape dental system). (E) Polishing surface of maxillary POM framework. (F) Fabricated maxillary POM framework.

3D scanner (3shape D900L, 3shape A/S, Copenhagen, Denmark) was used for scanning master cast to create a 3D model. Digital 3D design software (3shape Dental system, 3shape A/S, Copenhagen, Denmark) was used to re-determine block out, major connector, minor connectors, rests and clasps position followed the treatment plan (figure 2C-2E). The clasp position and thickness can be simply determined in all perspectives using software as shown in

figure 2D. The framework was designed to follow the conventional RPDs. To increase material strength, major connector outline was maximized without interference to oral structures and thickness, which was at least 2.0 mm. According to less retention of POM clasp, retentive clasp was made using 0.5 mm undercut and 1.5 mm thickness (figure 2D).[18]

POM CAD-CAM block (TSM Acetal Dental, Pressing Dental S.r.l, Repubblica di San Marino, Italy) was milled to form a framework by milling machine (figure 2F) (VHF S2, VHF camfacture AG, Ammerbuch, Germany).

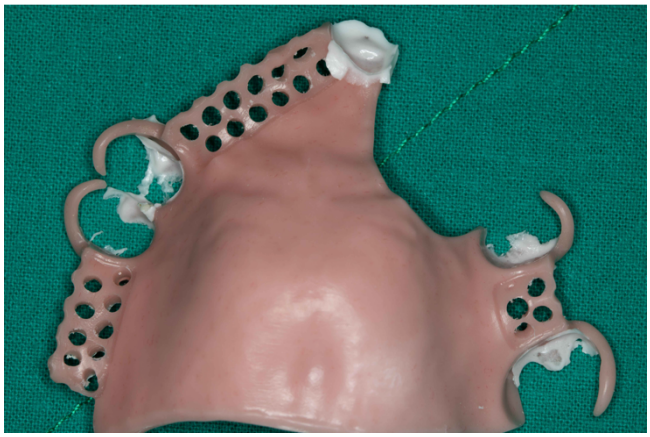

Figure 3. Using silicone-disclosing medium to check denture adaptation.

Figure 4. Insertion of removable partial denture with POM framework. (A) Occlusal view. (B) Frontal view. (C) Right side. (D) Left side.

Inspection of framework adaptation to patient's teeth in patient oral cavity using a silicone-disclosing medium (Fit-Checker, GC, Tokyo, Japan) revealed according to the ease of adjustment, framework indicated good adaptation (figure 3). Occlusion was checked and adjusted, fine adjustment using carbide bur with slow speed handpiece and polishing using non-aggressive polishing paste with cotton brush under slight pressure and slow speed to prevent material from overheating of POM. Afterwards, artificial teeth were placed on framework in master cast that mounted in semi-adjustable articulator. After completed, try-in teeth and patient accepted, the area that contacts PMMA and artificial teeth was air abrasion with aluminum oxide, pink wax was replaced by heat-cured PMMA. Finally, the last step was to polish using carbide bur and silicone polishing bur for acrylic resin. Upper RPD was inserted and inspected for denture adaptation and occlusion (figure 4A-4D). Polishing denture was done following by material's protocol.

After denture delivery, patient was satisfied with the light-weight and his appearance while wearing denture (figure 5). 1-year follow up showed that the denture was well-cleaned and in a good condition. However, patient needs to continue periodically recall.

Figure 5. Extraoral photographs after treatment wearing maxillary removable partial denture with POM framework without metal display.

Discussion

Due to the disability of capturing the physiologic extension in tissue-borne RPD, scanning from a master cast was chosen for more proper intaglio surface in CAD-CAM fabrication system.[24] Accordingly, the appropriate selection of material leads to treatment success; POM was selected to use as a framework because its color, weight and sufficient strength for tooth-borne RPD. Commercial POM is available in 18 VITA shades in tooth color and 3 pink shades, so POM is able to match more patient's teeth and gingiva. Recent studies

indicate that comparison of CAD-CAM milled materials (PEEK, POM and PMMA), POM had highest color stability.[25] 1-year recall showed good color stability. Due to the material's density as shown in table 1, POM is 5.7 times lighter than metal, resulting in greater patient satisfaction. The previous showed the more tissue coverage of denture led to the more gingival inflammation.[26] Therefore, the design of POM for denture base or framework is smaller with lesser tissue coverage compared to PMMA because of higher flexural strength, microhardness and fracture toughness, which provides better patient's oral hygiene and health.[14, 23]

The toxicity from formaldehyde is still a concern of using POM. Although, there is an in vitro study indicating the release of formaldehyde, human mesenchymal cells and mouse fibroblast cell toxicity[27], there is no POM allergic report of any kind in dentistry. Furthermore, there are some problems in the study design such as the report of formaldehyde being released at 200˚C that exceeds the normal oral cavity temperature and POM in the experiment was not dental grade, thus it lacks stability.[28]

Recent studies showed agreement the present case report that the most accurate, adaptation and reproducible in both denture base and RPDs fabrication[8, 29] is the ease of framework adjustment in try-in framework visit. Moreover, CAD-CAM constructed POM denture indicated higher mechanical properties than conventional method.[14] Accordingly, benefits of CAD-CAM technique for POM framework construction are more accurate and have higher mechanical properties than conventional technique.

There are various studies involving a POM clasp, where the POM clasp showed less retention compared to metal clasp but abundantly higher fatigue resistance in various insertion and removal cycles.[17, 18, 30] Using POM clasp of 1.5 mm thickness and 0.5 mm undercut is sufficient retention for RPDs, which is 6.6 N. Therefore, POM clasp has to be thicker than a metal clasp. Contrastingly, on the good side, POM clasp showed no tooth abrasion compared to a to metal clasp.[31] Because of a few decades of POM utilization in dentistry, particularly as a RPDs framework, there are no long-term studies more than 6 months and previous studies are contentious. To evaluate the denture's efficiency in a recall visit, it is essential to check denture adaptation to ensure that there are no deflection of material after absorbing patient's masticatory force and material surface texture and color to ensure that material has a sufficient resistance to oral environment. Currently, this case report has the longest follow-up period. After denture evaluation indicated good adaptation of denture base. POM denture was able to maintain clasps retention, shiny and smooth surface.

Conclusions

POM has a tendency to replace metal in dentistry. The construction of framework using CAD-CAM technique from POM showed good denture adaptation; more lightweight and more pleasurable wear as a non-metal denture. A denture showed well-condition and proper function of denture at 1-year recall.

Acknowledgements

This work was supported by a research grant from Faculty of Dentistry, Chiang Mai University.

Declaration of Interest

The authors report no conflict of interest.

References

1. Benso B, Kovalik AC, Jorge JH, Campanha NH. Failures in the rehabilitation treatment with removable partial dentures. Acta Odontol Scand 2013;71(6):135-55.
2. Douglass CW, Watson AJ. Future needs for fixed and removable partial dentures in the United States. J Prosthet Dent 2002;87(1):9-14.
3. Koyama S, Sasaki K, Yokoyama M, Sasaki T, Hanawa S. Evaluation of factors affecting the continuing use and patient satisfaction with removable partial dentures over 5 years. J Prosthodont Res 2010;54(2):97-101.
4. Campbell SD, Cooper L, Craddock H, et al. Removable partial dentures: The clinical need for innovation. J Prosthet Dent 2017;118(3):273-80.
5. Bohnenkamp DM. Removable partial dentures: clinical concepts. Dent Clin North Am 2014;58(1):69-89.
6. Fueki K, Ohkubo C, Yatabe M, et al. Clinical application of removable partial dentures using thermoplastic resin—Part I: Definition and indication of non-metal clasp dentures. J Prosthodont Res 2014;58(1):3-10.
7. Levin L. Dealing with dental implant failures. J Appl Oral Sci 2008;16:171-5.
8. Arnold C, Hey J, Schweyen R, Setz JM. Accuracy of CAD-CAM-fabricated removable partial dentures. J Prosthet Dent 2018;119(4):586-92.
9. Lekha K, Savitha N, Roseline M, Nadiger RK. Acetal resin as an esthetic clasp material. J Interdiscip Dentistry 2012;2(1):11-4.

10. Piemnithikul N, Angkasith P, Chaijareenont P. Removable partial denture polyetheretherketone framework: A case report. CM Dent J 2021;42(1):185-98.
11. Gilbert M. Brydson's plastics materials: William Andrew; 2016.
12. Fitton J, Davies E, Howlett J, Pearson G. The physical properties of a polyacetal denture resin. Clin Mater 1994;17(3):125-9.
13. Alagwany A, Diab Fatoh MA, Helal MA, Mahmoud II. Wear resistance evaluation of the thermoplastic acetal resin denture base material–An In Vitro study. J Clin Res Dent 2019;2(2):1-5.
14. Kamal M. Evaluation of surface micro-hardness and fracture toughness of conventionally constructed versus CAD/CAM constructed denture base materials-an In-Vitro study. Egypt Dent J 2021;67:757-65.
15. Karamuk E, Mayer J, Düring M, et al. Biocompatible materials ccience and engineering. Paper presented at: Proceedings of the 2nd international Conference, 24th and 25th August 1999, 2001; Bolton Institute, UK
16. Turner JW, Radford DR, Sherriff M. Flexural properties and surface finishing of acetal resin denture clasps. J Prosthodont 1999;8(3):188-95.
17. Arda T, Arikan A. An in vitro comparison of retentive force and deformation of acetal resin and cobalt-chromium clasps. J Prosthet Dent 2005;94(3):267-74.
18. Tannous F, Steiner M, Shahin R, Kern M. Retentive forces and fatigue resistance of thermoplastic resin clasps. Dent Mater 2012;28(3):273-8.
19. Arikan A, Ozkan YK, Arda T, Akalin B. An in vitro investigation of water sorption and solubility of two acetal denture base materials. Eur J Prosthodont Restor Dent 2005;13(3):119-22.
20. Ozkan Y, Arikan A, Akalin B, Arda T. A study to assess the colour stability of acetal resins subjected to thermocycling. Eur J Prosthodont Restor Dent 2005;13(1):10-4.
21. Ismail HA, Abbas FS, El Gindy NA. Clinical evaluation of polyxoymethylene partial dentures designed and fabricated by using CAD/CAM technology. Alex Dent J 2019;44(2):77-83.
22. Kassem M, Saief-Elnasr M, Baraka Y, Helal M. Bite force evaluation of acetal resin denture base in Kennedy class I partially edentulous patients. EC Dent Sci 2020;19:1-8.
23. Arıkan A, Ozkan YK, Arda T, Akalın B. Effect of 180 days of water storage on the transverse strength of acetal resin denture base material. J Prosthodont 2010;19(1):47-51.
24. Tamimi F, Hirayama H. Digital restorative dentistry: Springer; 2019.
25. Kamal MNM. Comparative evaluation of color stability between three different CAD/CAM milled denture base materials: An In vitro study. J Int Dent Med Res 2020;13(3):854-60.
26. Chandler JA, Brudvik JS. Clinical evaluation of patients eight to nine years after placement of removable partial dentures. J Prosthet Dent 1984;51(6):736-43.
27. Zilberman U. Formaldehyde from POM brackets. Am J Orthod Dentofacial Orthop 2005;128(2):147-8.
28. Kusy RP, Whitley JQ. Degradation of plastic polyoxymethylene brackets and the subsequent release of toxic formaldehyde. Am J Orthod Dentofacial Orthop 2005;127(4):420-7.
29. Goodacre BJ, Goodacre CJ, Baba NZ, Kattadiyil MT. Comparison of denture base adaptation between CAD-CAM and conventional fabrication techniques. J Prosthet Dent 2016;116(2):249-56.
30. Meenakshi A, Gupta R, Bharti V, Sriramaprabu G, Prabhakar R. An evaluation of retentive ability and deformation of acetal resin and cobalt-chromium clasps. J Clin Diagn Res 2016;10(1):ZC37-41.
31. Pal H, Hegde D, Nair CK. A comparative study on Co-Cr and Acetal resin clasps. Trends Prosthodont Dent Implantol 2020;5(1):6-10.
32. Dhuru VB. Contemporary dental materials: Oxford university press; 2004.
33. Lüftl S, Visakh P, Chandran S. Polyoxymethylene handbook: structure, properties, applications and their nanocomposites: John Wiley & Sons; 2014.