The Effectiveness of Corticosteroid and Diode Laser Combination Therapy in the Treatment of Severe Oral Lichen Planus: A Case Report

Irna Sufiawati[1]*, Helen Christine[2], Fika Faradillah Drakel[2]

1. Department of Oral Medicine , Faculty of Dentistry, Universitas Padjadjaran, Bandung, Indonesia.
2. Oral Medicine Residency Program, Faculty of Dentistry, Universitas Padjadjaran, Bandung, Indonesia.

Abstract

Laser therapy has been used in the current treatment of choice to speed up the recovery of oral lichen planus (OLP).

This case report aims to demonstrate a combination approach of diode laser and corticosteroid for the treatment of painful reticular, plaque, and erosive-type OLP. A 34 years old male patient presented to Oral Medicine Clinic with a chief complaint of burning sensation in the oral cavity especially while eating spicy food since 3 months ago. Intraoral examination showed the areas of erosion interspersed with Wickham striae on the labial and buccal mucosa bilaterally, gingiva and palate, and white plaques surrounded by erythematous area on the dorsal of the tongue.

Histopathological examination confirmed the diagnosis of severe OLP. He was given a short course of systemic corticosteroid followed by topical high-potency corticosteroid, but the signs and symptoms of OLP showed slight improvement. After giving a combination of topical corticosteroid and diode laser therapy, the lesions showed excellent improvement.

Case report (J Int Dent Med Res 2022; 15(1): 312-314)

Keywords: Corticosteroid, Diode Laser, Oral Lichen Planus.

Received date: 01 November 2021 **Accept date:** 04 January 2022

Introduction

Oral lichen planus is an autoimmune disease mediated by T-cells. It manifests as chronic inflammation in the stratified squamous epithelial cells of the oral mucous membranes. The prevalence is around 1-2% and commonly affects 30-60 years of age population.[1] Although the etiology of OLP still unknown exactly, but some predisposing factors have been associated with it. Susceptibility genetic, dental restorations, poor oral hygiene, viral and bacterial agents (such as helicobacter pylori, human papilloma virus, human herpes virus 6, human immunodeficiency virus, hepatitis C virus, Epstein Barr virus), diseases (such as thyroid diseases, bowel diseases, primary biliary cirrhosis, myasthenia gravis, thymoma, diabetes mellitus, hypertension, psoriasis, lichen sclerosis, urolithiasis, agents used to treat gall stones, Turner's syndrome), phychological stress, malignancy, food and contact allergens (such as cinnamon, tooth paste flavoring) and drugs (such as angiotensin-converting enzyme (ACE) inhibitors, beta blockers, NSAIDs, antimalarials and sulfonylureas).[2,3] Clinical manifestations include reticular, plaque, papular, atrophic, erythematous, bullous and vesicular lesions. Symptoms varied from asymptomatic, oral pain to difficulties of eating and swallowing.[1,4]

OLP is recognized as an oral potentially malignant disorders. Predicting malignant transformation and treating of OLP are challenging.[4] The golden standard treatment of OLP is corticosteroid.[1] However, in recent years, diode laser therapy is studied and being considered as a proper treatment for the disease. The laser used for soft tissues are CO2, YAG and Diode. CO2 laser is a medium, gas-active, using light energy, has shallow penetration effect. YAG laser activated media doped with erbium, which reaches to 6 mm depth of penetration in continuous mode. Diode laser is a semi-conductor laser using gallium, arsenic, aluminium and indium, which transforms electrical energy to light. Diode laser can mostly be absorbed by soft tissues, therefore, can be used for OLP.[5]

Corresponding author:
Irna Sufiawati
Department of Oral Medicine
Faculty of Dentistry, Universitas Padjadjaran
Jl. Sekeloa Selatan No.1, Bandung 40132,
West Java, Indonesia
E-mail: irna.sufiawati@fkg.unpad.ac.id

We report a case of severe reticular, plaque and erosive-type OLP which showed a fast significant improvement after combination of diode laser and corticosteroid therapy.

Case Report

A 34 years old male patient visited Oral Medicine Clinic of Dr. Hasan Sadikin Hospital, Bandung West Java, Indonesia, with a chief complaint of burning sensation in the oral cavity in the last 3 months. He had history of asthma and smoking for 20 years. Patient had history of psychological stress for the last one year. The Depression Anxiety Test Score (DASS) test showed moderate depression, extreme anxiety and mild stress. Intraoral examination showed the areas of erosion interspersed with Wickham striae on the labial, buccal, and palate mucosa, and white plaque on the dorsal of the tongue (Figure 1).

Figure 1. Clinical features at the first visit: a, b, c. Erosive lesions interspersed with reticular lesions (Wickham striae) on gingiva, palate, and buccal mucosa bilaterally; d and e. Reticular lesions on upper and lower labial mucosa; f. White plaque surrounded by erosive lesions on the dorsal of the tongue.

Based on the reticular/keratosis, erythema, and ulceration (REU) scoring system, the severity of OLP was scored 22, and numeric rating scale (NRT) was 8 indicated severe pain. The patient was diagnosed with severe reticular, erosive and plaque-type of OLP. Incisional biopsy was taken from the right buccal mucosa. Histopathological examination confirmed the diagnosis of OLP (Figure 2).

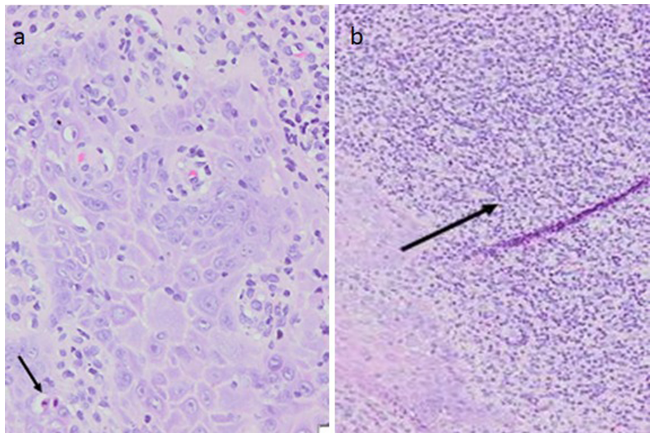

Figure 2. Histopathological appearance of the lesion: a. Arrows show civatte bodies (200x magnification); b. Arrows show band-like lymphocytic infiltration in lamina propria (x20 magnification).

Figure 3. Clinical features at the follow up visits: a, b, c. At a month follow up after corticosteroids treatment only, the lesions on the buccal mucosa and dorsal of the tongue showed only slight improvement; d, e and f. After 2 weeks of diode laser and topical corticosteroid combination therapy, the lesions showed excellent improvement.

The patient was given a short 2-week course of oral prednisone 30 mg daily followed by tapering off 5 mg and combined with dexamethasone 0.01% mouthwash at the third week. The patient was refused for a psychiatric consultation. At a month follow up, the lesions showed only slight improvement. Diode laser treatment was performed and dexamethasone 0.01% mouthwash was also still administered. Two weeks follow-up after the last therapy, the lesions showed excellent improvement. The REU

and NRT score and significantly decreased after the therapy. Figure 3 showed the clinical features before and after diode laser combined therapy with topical corticosteroid.

Discussion

The clinical severity of OLP in this case was determined using REU scoring system and NRT which revealed severe OLP. REU scoring system was done according to clinicopathology which signed by bilateral symmetrical reticular lesions, with erosion and plaque type, band like lymphocytic infiltrate and liquefactive degeneration of basal epithelial cells.[6] The severity of OLP in this case was considered to be associated with the patient's psychological problem. It has been previously reported that stress, anxiety, and depression are risk factors for OLP development. These mental health conditions can modify dysregulation of immune functions, increase vulnerability to the development of oral lichen planus.[7] Psychological stress can stimulate mast cells (MCs) that interact with T-cells which play a major role in the occurrence of OLP.[8]

Corticosteroid is the treatment of choice for OLP due to its anti-inflammatory and immunosuppressant effect, which reduce cytokine productions, TNF-α and interleukins; suppressing leukotriene and prostaglandin synthesis; and reduce neutrophil migrations.[1,5] The patient's extensive size of OLP lesions became the consideration of combining topical and systemic corticosteroid therapy.[9] Topical corticosteroid is the first line of therapy for OLP, while the systemic corticosteroid therapy is mostly considered for diffuse erosive type or acute exacerbation OLP.[10,11] Since the signs and symptoms have no improvement after corticosteroid therapy alone, then we performed combination of corticosteroid and diode laser therapy which revealed to be an effective therapy for OLP.

Diode 976 nm low level laser has been used to OLP lesions to alleviate activator area of immune aggression to stop autoimmune process, reduce pain and lesion sizes. It has homeostatic effect and produce minimal trauma thus reducing inflammation and post therapeutic pain.[5,10] Arora *et al* (2018) reported that diode laser therapy has been successfully used to treat OLP without any complication. [5] It has faster recovery due to its anti-inflammatory effect due to modulation of mast cell functions, decreased production of pro-inflammatory and prostaglandin improvement of cell metabolism induction, increased proliferation, maturation and migration, as well as vasodilatation and analgetic effect.[12]

Conclusions

Diode laser combined with topical corticosteroid therapy has been successfully used in the management of symptomatic OLP without any complication which can help improve the quality of life of the patient. Diode laser treatment is a promising treatment option for OLP.

Declaration of Interest

The authors declared no conflicts of interest.

References

1. Ion DI, Setterfield JF. Oral Lichen Planus. Prim Dent J. 2016 Feb 1;5(1):40-44.
2. Gupta S, Jawanda MK. Oral lichen planus: An update on etiology, pathogenesis, clinical presentation, diagnosis and management. Indian J Dermatol. 2015 May-Jun; 60(3): 222–229.
3. Aleksejuniene J, Rimkevicius A, Puriene A, Rasteniene R. Social and Clinical Risk Determinants of Oral Lichen Planus – a Case Control Study. J Int Dent Med Res. 2020;13(2):601–7.
4. Margono HB, Sufiawati I. The Challenge in Predicting Malignant Transformation of Oral Lichen Planus. In: Maharani DA, editor. Case Reports in Dentistry. New York: Nova Science Publishers, Inc; 2018. p. 1–14.
5. Arora KS, Bansal R, Mohapatra S, Verma A, Sharma S, Pareek S. Prevention of malignant transformation of oral leukoplakia and oral lichen planus using laser: An observational study. Asian Pacific J Cancer Prev. 2018;19(12):3635–41.
6. Park HK, Hurwitz S, Woo S Bin. Oral lichen planus: REU scoring system correlates with pain. Oral Surg Oral Med Oral Pathol Oral Radiol. 2012;114(1):75–82.
7. Zucoloto ML, Shibakura MEW, Pavanin JV, Garcia FT, da Silva Santos PS, Maciel AP, et al. Severity of oral lichen planus and oral lichenoid lesions is associated with anxiety. Clin Oral Investig. 2019;23(12):4441–8.
8. George BT, Ismail PMS, Syed SA, Das SS, Jena D, Moosani GK. Oral lichen planus: A case report and an update on the role of mast cells in its pathogenesis. J Int Oral Heal. 2016;8(2):292–5.
9. Thongprasom K. A Review of the Effectiveness and Side-Effects of Fluocinolone Acetonide 0.1% in the Treatment of Oral Mucosal Diseases. Acta Stomatol Croat. 2017;51(3):240–7.
10. Nosratzehi T. Oral lichen planus: An overview of potential risk factors, biomarkers and treatments. Asian Pacific J Cancer Prev. 2018;19(5):1161–7.
11. Mutafchieva MZ, Draganova-Filipova MN, Zagorchev PI, Tomov GT. Effects of Low Level Laser Therapy on Erosive-atrophic Oral Lichen Planus. Folia Med (Plovdiv). 2018;60(3):417–24.
12. Jajarm HH, Falaki F, Mahdavi O. A comparative pilot study of low intensity laser versus topical corticosteroids in the treatment of erosive-atrophic oral lichen planus. Photomed Laser Surg. 2011;29(6):421–5.