Malignant Transformation of Longstanding Dentigerous Cyst in the Antrum: A Case Report

Chithra Aramanadka[1], Adarsh Kudva[1], Srikanth Gadicherla[1], Monica Charlotte[2]

1. Department of Oral and Maxillofacial Surgery,Manipal college of Dental Sciences, Manipal,Manipal academy of higher education, Manipal, Karnataka, India.
2. Department of Oral and Maxillofacial Pathology, Manipal college of Dental Sciences, Manipal,Manipal academy of higher education, Manipal, Karnataka, India.

Abstract

Dentigerous cysts are always associated with impacted teeth. It is not common in the maxilla compared to the mandible. When it is involved, the maxillary sinus causes sinus-related symptoms. When there is a delay in the treatment, complications of cystic expansion are common.

We describe a case of malignant changes observed in the longstanding dentigerous cyst in the maxillary sinus.

Case report (J Int Dent Med Res 2022; 15(1): 315-318)

Keywords: Dentigerous cyst,malignant changes,Dysplastic.

Received date: 18 December 2021 **Accept date:** 29 January 2022

Introduction

The dentigerous cyst develops because of the accumulation of fluid between the tooth and the follicle. It is common in the ramus angle region of the mandible. Maxillary dentigerous cysts are not as common as mandibular ones. When there is a delay in the treatment, long-term complications like the development of ameloblastoma or epidermoid carcinoma, or mucoepidermoid carcinomas are documented. Dentigerous cysts and odontogenic keratocysts have shown the highest rate of malignant transformation in the oral cavity[1]. We report a case of a long-standing large maxillary dentigerous cyst with malignant changes in the cystic lining.

Case Report

A 39-year-old female patient visited the outpatient department with persistent swelling and pus discharge and continuous mild pain in the right upper back tooth region since 2 years. Initially, she noted minimal pain in the Right Upper Posterior tooth followed by swelling and associated pus discharge. She had been consuming antibiotics and analgesics as advised by private practitioner. When she noted the swelling is increasing in size, she reported to the out patient department. The patient also reported Right nasal blockage for one year with no history of anosmia and epistaxis.

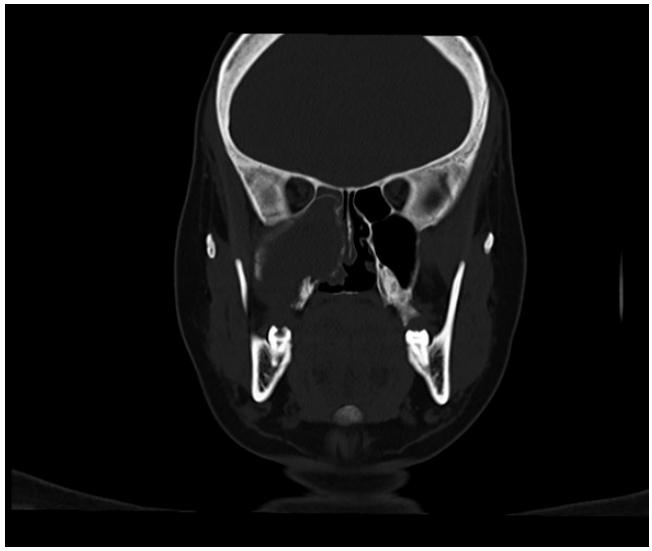

Figure 1. CECT Face and neck showing the extension of the lesion into the ethmoid sinus.

Following the initial visit, a Cone Beam CT scan done for further evaluation showed a cystic lesion in the right maxillary sinus with an impacted third molar. The superior extention was inadequate in the CBCT image. CECT Face and neck described the extension of the lesion in the

Corresponding author:
Associate Professor **Dr.Adarsh Kudva**
BDS.MDS.MOMSRCSEd.FHNSO.FIBCSOMS
Department of Oral and Maxillofacial Surgery
Manipal College of Dental Sciences
Manipal, Karnataka, India
E-mail:dradarshkudva@gmail.com

entire maxillary sinus superiorly to the cribriform plate of the ethmoid(Fig-1). Aspiration of the content showed straw-colored fluid suggestive of a cyst. Hence, enucleation of the cyst with the removal of the impacted tooth was performed through the canine fossa (Caldwell-Luc) approach under general anesthesia(fig-2). The flap was reflected, a bony window was created using pizotome. Tooth extraction was done along with the cystic lining. Endoscope-assisted removal of the cystic lining from the ethmoid sinus was performed. Finally, complete removal of the lining from all surfaces of the maxillary sinus was confirmed using an endoscope. Histopathologic features suggested a dentigerous cyst with extensive squamous metaplasia and moderate severe dysplasia of the lining (fig-3).

Figure 2. Enucleation of the cyst with the removal of the impacted tooth.

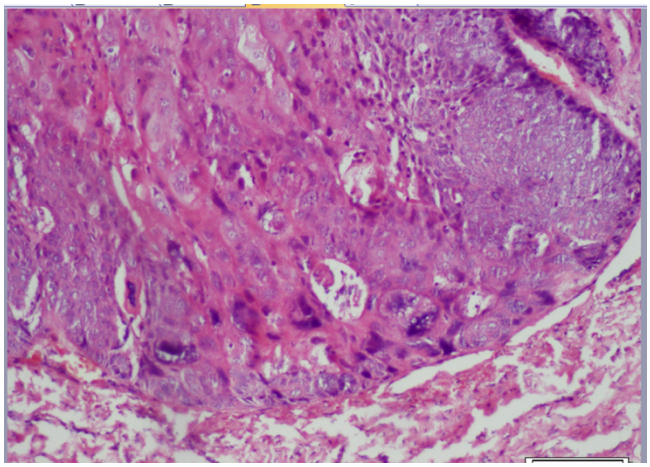

Figure 3. Histopathologic picture with dysplastic changes in the cyst.

As per Multidisciplinary Team decision the patient was kept on close follow-up because of dysplastic changes in the cystic wall. Patient was serially evaluated clinically every three months however at second follow up patient presened with growth in relation to right malar region.

CECT revealed heterogenous enhancing lesion in relation to right maxillary sinus with erosion of bone. (Fig-4) Biopsy was performed and diagnosed with well differentiated squamous cell carcinoma. Patient was treated with right total maxillectomy and right MRND and postoperative adjuvant radiotherapy.

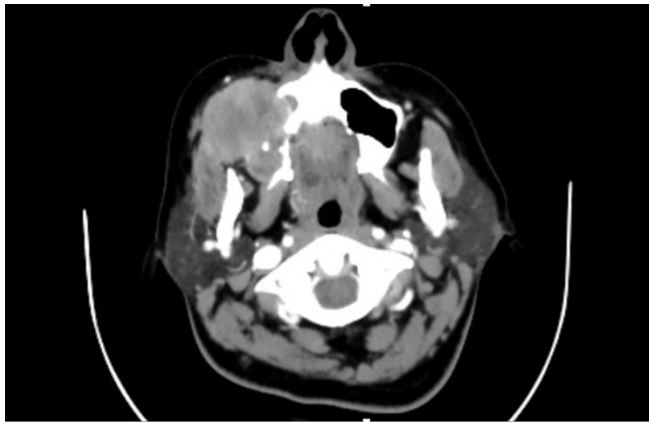

Figure 4. Contrast CT Scan depicting the aggressive changes and extension of the lesion to pterygoid plates.

Discussion

Dentigerous cyst is the cavity that encloses the erupting tooth by expanding follicle at the cementoenamel junction[12]. Dentigerous cysts are less common in the maxillary sinus. In the initial presentation, the expansion of the maxillary sinus due to ectopic teeth can be considered. Ectopic teeth in the maxillary sinus may be due to expansion of the follicle or cyst as there is an accumulation of fluid between the CEJ and the epithelial lining[2].

Only a few cases of dentigerous cyst in the maxillary sinus are reported in the literature. Differential diagnosis includes residual cyst, Odontogenic keratocyst, Unicystic ameloblastoma, Adenomatoid odontogenic tumor, and tumors of maxillary sinus[3].

Odontogenic cyst of the maxillary managed by enucleation along with the removal of the associated teeth. Enucleation can be performed by using endoscopes through the middle meatus antrostomy[4]. However, complete examination and reduction of the entire lining can

be best achieved by the Cald well- Luc procedure and cystorhinostomy. Enucleation of the complete cystic lining can be confirmed using an endoscope in deeper inaccessible areas.

Dentigerous cysts in the maxillary antrum can remain asymptomatic for a long duration. As the cyst expands, the impacted tooth will be displaced from the position. This theory explains the ectopic position of the impacted tooth. When the cyst grows, it may cause facial swelling, sinusitis, facial pain, nasolacrimal duct obstruction, epiphora, and orbital proptosis[2].

There are very few reports available on maxillary cysts undergoing malignant transformation. This case of dysplastic changes in the dentigerous cystic lining of the maxillary sinus can be added to the reported case list. In the jaws, transformation of dentigerous cyst or OKC can lead to PIOC. According to WHO, primary intraosseous carcinoma is defined as central jaw carcinoma that cannot be categorized as any other type of carcinoma[8]. It is divided into solid, and those arising from odontogenic cysts and tumors.

Carcinomatous changes are more common in males and mostly seen in the posterior mandible, as described by Bodner et al.[9].

Chronic inflammation persisting for a long duration is a possibility to undergo a malignant transformation in odontogenic cysts. Another probable cause is oncogene. The lining of the cyst can have orthokeratinised cells, mucous secreting cells or ciliated cells. The inherent ability of the cystic lining to undergo metaplasia can transform into odontogenic keratocyst, ameloblastoma or squamous cell carcinoma or mucoepidermoid carcinoma[11]. The present case is the best example for the first mechanism[5].This is based on the mechanism proposed by Virchow; chronic inflammation stimulates the release of inflammatory mediators like prostaglandins, cytokines, and reactive oxygen species such as peroxide anion, hydrogen peroxide, and hydroxyl radicals. They combine with nitric oxide to form other reactive nitrogen intermediates, which cause potential damage to the cell structure. Chronic inflammation also promotes apoptosis and leads to the collection of stem cells; in turn, mutation further causes genomic instability[6].

Clinical features of malignant transformation in the jaws include pain, swelling, paresthesia, and mobility of teeth. Classic symptoms of carcinoma of maxillary antrum are epistaxis, nasal obstruction or discharge, epiphora, diplopia, proptosis, orbital pain and sometimes paraesthesia.

Delay in the clinical symptoms can be attributed to the structure of the maxillary sinus, which allows expansion of the lesion in the air cavity.This seems to be the reason for patients to be presented at advanced stages.

Early diagnosis and treatment can prevent complications. Orthopantamogram may not reveal the extension of the lesion[13]. Three-dimensional imaging can detect early changes like jagged or irregular margins with indentations and indistinct borders that suggest a possible malignant change. However, malignancy in the cystic wall is unexpected and confirmed following histopathologic examination[7,8]. Close follow-up of the lesion with advanced diagnostic methods such as DNE, CECT, and PET scanning will aid in the diagnosis. The management of Squamous cell carcinoma of maxillary is surgery and chemo radiation[9].Ohngren divided the maxillary sinus into anteroinferior and posterosuperior compartment, where the former has better prognosis.

Reports suggest that PIOC arising from cysts have a better prognosis than other forms in terms of lower metastasis and recurrence rate[10].There are no reports available about the malignancy ex odontogenic cyst in the sinus.

Conclusions

Untreated dentigerous cysts in the maxillary sinus can lead to many complications. Complete enucleation with the removal of impacted teeth remains a mainstay of treatment. Frequent follow-up must be executed if the histopathologic examination confirms dysplastic changes. Surgery and adjuvant chemo radiation is the mainstay of treatment for malignancy of maxillary sinus.

Declaration of Interest

The authors report no conflict of interest.

References

1. Masthan K.M.K, Rajkumari S, Deepasree M, Babu N A, Sankar S L, Neoplasms associated with odontogenic cysts J Dent Oral Hyg. 2011; 3(10): 123-130, 18.

2. Buyukkurt MC, Omezli MM, Miloglu O. Dentigerous cyst associated with an ectopic tooth in the maxillary sinus: a report of 3 cases and review of the literature. Oral Surg Oral Med Oral Pathol Oral Radiol Endod 2010;109:67e71.
3. Dentigerous cyst associated with an ectopic tooth in the maxillary sinus: a report of 3 cases and review of the literature;M. C. Buyukkurt,a M. M. Omezli,b and O. Miloglu,c Erzurum, Oral Surg Oral Med Oral Pathol Oral Radiol Endod 2010;109:67-71).
4. Hasbini AS, Hadi U, Ghafari J. Endoscopic removal of an ectopic third molar obstructing osteomeatal complex. Ear Nose Throat J 2001;80:667e70.
5. Borrás-Ferreres J, Sánchez-Torres A, Gay-Escoda C. Malignant changes developing from odontogenic cysts: A systematic review. J Clin Exp Dent. 2016;8(5):e622-8
6. Primary Intraosseous Squamous Cell Carcinoma Arising in Odontogenic Cysts: An Insight in Pathogenesis Jain M, Mittal S, Kumar D,J Oral Maxillofac Surg 2013;71:e7-e14,
7. Pearcey RG: Squamous cell carcinoma arising in dental cysts. Clin Radiol 1985;36: 387e388.
8. Marchal A, Gérard É, Curien R, Bourgeois G. Primary intraosseous carcinoma arising in dentigerous cyst: Case report. Int J Surg Case Rep. 2020;76:530-533.
9. Bodner L, Manor E, Shear M, van der Waal I: Primary intraosseous squamous cell carcinoma arising in an odontogenic cyst: A clinicopathologic analysis of 116 reported cases. J Oral Pathol Med. 2011; 40:733,
10. Matsumoto S, Shibuya H, Tatera S, Yamazaki E, Suzuki S. Comparison of CT findings in non-Hodgkin lymphoma and squamous cell carcinoma of the maxillary sinus. Acta Radiol 1992; 33:523527.
11. Kamil Serkan Agacayak, Ibrahim Kose, Nedim Gunes, Emrullah Bahsi, Ferhan Yaman, Serhat Atilgan , Dentigerous cyst with an impacted canine: case report; JIDMR. 2011; 4 (1),Pages 21-24.
12. I Sasmita, L Epsilawati, F Pramanik, Prevalence of the Dentigerous Cyst in Indonesian people using Panoramic Radiograph, JIDMR. 2017; 10 (1) Pages 108-110.
13. Warad. N.M, Sulabha A. N, Sameer Choudhari, Suchitra.G , An unusual presentation of dentigerous cyst involving the maxillary canine in a young boy , JIDMR. 2012; 5 (2) 114-117.