Oral Ulceration Bone Sequestration Treatment Consideration-Review of Treatment Methods and two Case Presentation

Aleksy Nowak[1,2], Łukasz Słowik[1], Maciej Okła[1], Jacek Pawłowski[1], Marian T. Nowaczyk[1], Krzysztof Osmola[1], Marzena Wyganowska-Świątkowska[3]

1. Department of Maxillofacial Surgery, Poznan University of Medical Sciences, Poznan, Poland.
2. Doctoral School of Poznan University of Medical Sciences.
3. Department of Oral Surgery and Periodontology, Poznan University of Medical Sciences.

Abstract

Oral Ulceration Bone Sequestration (OUBS) is a type of osteonecrosis, however its specifics is still incompletely characterized. The literature shows only single case reports while the questionnaire research indicates a quite common occurrence of the disease.

The OUBS is defined as a osteonecrosis of the jaw which is not caused by the use of medicines, radiotherapy or any other risk factor.

The thesis presents two cases of OUBS that show the effective treatment methods.

The review of the methods was made on the basis of the available literature in order to facilitate making clinical decisions.

In cases concerning symptomatic patients it is recommended to implement more radical treatment. Conservative therapy can be administered successively to asymptomatic patients.

Special attention should be paid to the differential diagnosis of ulceration as well as to preparing the sample for the histopathology examination.

Case report (J Int Dent Med Res 2022; 15(4): 1731-1735)

Keywords: OUBS, necrosis of the jaw, maxillofacial surgery, sequestration, osteonecrosis.

Received date: 15 July 2022 **Accept date:** 30 August 2022

Introduction

Twenty years have passed since the first reports of Marx concerning osteonecrosis of the jaw bones as a result of bisphosphonates[1], and over a hundred years since osteoradionecrosis has been described by Regaud[2]. The origins of the disease may be also related to inflammation[3] or have unidentified characteristics, defined as: exposing the bone and sequestrum separation without a recognized cause[4]. Initially the drug-induced necrosis was described as Bisphosphonate - related osteonecrosis (BRONJ)[5,6,7,8,9,10,11], however in 2014 the name was changed into Medical-related osteonecrosis (MRONJ)[12]. This was due to founding the evidences that there are some different types of drugs causing osteonecrosis, for example steroids, RANKL inhibitors, antiangiogenic medicines[5,7,8,12,13,14,15].

The current definition of MRONJ is exposing jaw or mandible bones for more than eight weeks in a patient taking antiangiogenic medicines, without radiotherapy of the discussed area and clear symptoms of metastatic cancer[12]. Even though the definition of drug-induced necrosis is known, there is still no unambiguous concept for the Oral Ulceration and Bone Sequestration (OUBS). Previously this disease was described as lingual mucosal ulceration with mandibular sequestration[16], lingual ulceration and necrosis of the jaw[17], Idiopathic Exposed Bone Lesions of the Jaw[18], oral ulceration with mandibular necrosis[19].

According to Thermos G. OUBS is site-specific oral ulcer that covers exposed, non vital bone in patients lacking any etiological factor know to induce osteonecrosis[20].

OUBS develops more often in the mandible than in the maxilla and concerns primarily men.

Ulcers are mainly located in the area of *mylohyoid ridge*, what may have a connection to

***Corresponding author:**
Aleksy Nowak MD,
Department of Maxillofacial Surgery,
Poznan University of Medical Sciences,
Poznan, 49 Przybyszewskiego St.,
Poland 61-131 Post Code
E-mail: aleksy.nowak@student.ump.edu.pl

the poor vascularity of this region. They were also described on the surface of benign bone lesions such as exostosis or palatal torus[21]. In a large clinical study the incidence of the disease was set at 0,02 %, however the authors indicate poor knowledge of it as well as poor reporting[4].

Low recognisability of OUBS should not be surprising in terms of little awareness of MRONJ among medical professions[22].

Necrotic lesions shown on both OPG and bitewing X-rays are rarely diagnosed[4,17,18,19].

Only after CBCT examination some information can be provided and some lesions can be seen[19].

The main symptoms that patients complain about are: pain, hypersensitivity and swelling, however some patients show no disease symptoms[4,17,18,19,20].

Due to low number of documented cases there is no clear method of treatment. Some authors remove the lesions surgically under general or local anesthesia[4,17].

Another method popular especially with asymptomatic patients consists in treating with the help of anti-bacterial cleanses which allow the sequestrum to separate and the lesions to heal[4,18].

The main goals of the thesis are: to present two cases of the disease being considered and the review of literature about treatment method from 2020 where 46 reported cases can be found[4,20].

Case Reports

FIRST CASE PRESENTATION

33-year old man, disabled and mentally stunted, not incapacitated, did a dental consultation due to a change in the oral cavity and pain. Medical interview contained the information about intellectual disability from childhood without any identified cause, no other chronic diseases, no allergies or medications taking permanently. A big weight loss was noted – the patient lost 20 kilograms in 6 months. Currently he is 175 cm tall and weighs 40 kg.

The dentist ordered the OPG X-Ray. It showed an extensive sclerotic lesion surrounded by a halo on its perimeter, located on the left angle of the madnible.

Next, the patient was referred to a maxillofacial surgeon who recognized some osteonecrosis symptoms and referred the man to the highly specialized hospital.

The treatment was based on the administration of antibiotics according to the scheme: the patient was receiving amoxicillin with clavulanic acid (875mg+125mg) twice a day for seven days and moreover better oral hygiene was recommended.

After the diagnosis at the hospital the patient was qualified for surgery under general anesthesia since there was a concern that the patient would not cooperate well and the risk of a fracture of the mandible was possible.

During the surgery the necrotic bone fragment was removed. It got separated from the bone without complications. The loss in the bone was rinsed with sodium chloride (NaCl) solution, Spongostan with iodophor was put on and the wound was stitched.

What is more the patient underwent a comprehensive oral care. The OPG X-Ray did not show the mandibular discontinuity. The next day the patient was discharged home with no complains. For seven days after the surgery he was receiving amoxicillin with clavulanic acid (875mg+125mg) twice a day [23]. The histopathological examination of the sample with dimensions of 5,0 x 3,0 x 2,0 cm showed the bone necrosis with chronic granulomatous inflammation. (Figure 1)

The postoperative follow-up examination revealed a regular process of wound healing.

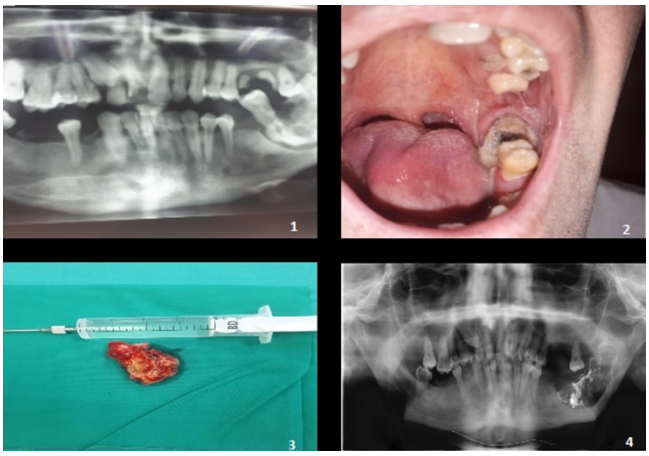

Figure 1. (1)The OPG X-Ray – a visible sequestrum surrounded by an osteolytic halo, (2)The image of the lesion during the intraoral examination (3)The removed bone sequestrum, (4)The OPG X-Ray – the post-surgical image of the loss in the mandible with the presence of iodophor.

SECOND CASE PRESENTATION

36-year old man was referred to the maxillofacial surgery department due to the suspicion of a neoplastic process in the oral cavity. It was caused by a non-healing ulcer located in the alveolar ridge of maxilla for two weeks. The man reported slight pain discomfort. Despite of many medicines for heart failure being taken, none of them could be the reason of the patient's symptoms. His heart failure was under control, he did not report any exacerbations of the disease and the ejection fraction was at 35%. Similarly, complete blood counts did not show anemia what let the doctors exclude these two diseases as the reasons for ischemic necrosis.

The examination showed the exposure of the jaw bone at the second molar. The OPG X-Ray did not reveal any anomalies. The patient was recommended to care more about oral hygiene - chlorhexidine oral rinse 0,02%. During the hospitalization the patient underwent laboratory blood tests and full radiological diagnostics. CT imaging revealed the presence of a bone sequestrum at the second molar and total airless of the right maxillary sinus filled with chronic inflammation of mucousa. (Figure 2)

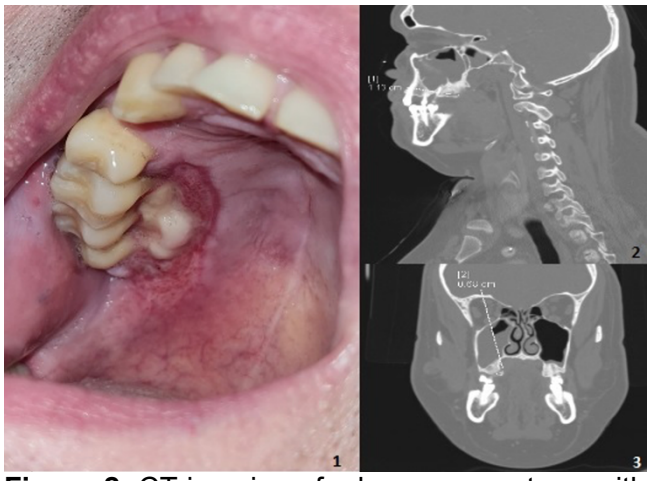

Figure 2. CT imaging of a bone sequestrum with chronic inflammation of mucousa.

During the stay at the ward an idiopathic separation of the lamina of a dead bone occurred and all the pain symptoms subsided. The patient has his sinus cavity revised and the doctors collected the sample for histopathological examination from the edges of the healing ulcer. The course of the surgery was uneventful.

Bone necrosis was diagnosed in the histopathological examination. The patient did not report any complaints at the follow-up visits and the wounds healed properly.

Discussion

Three aspects can be distinguished in the treatment of osteonecrosis of the jaws: systemic treatment, surgery and adjuvant treatment (e.g. tocopherol, platelet concentrates, hyperbaria) [24]. The first attempt at AAOMS therapy should be antibiotic therapy supplemented with local debridement of the lesion and the use of mouthwashes to improve oral hygiene. Advanced surgical treatment of the removal of dead bone is used in the 3rd stage of the disease [12]. Unfortunately, conservative treatment is of low effectiveness [25]. The growing problem of osteonecrosis of the jaws causes a search for newer and newer methods of treatment, including methods using blood-derived factors and physical factors. Local removal of necrotic lesions supported by blood-derived factors are used with good results, for example platelet-rich plasma or fibrin [7, 26, 27,28,29,30], growth factor concentrate (CGF) [31] and healing with bone marrow stem cells [11]. Attempts have been made to apply additional physical factors such as ozone or piezo-assisted cleaning[32], resection using fluorescein as a marker[9], with the use of a laser [33] or the reconstruction of the defect with the use of vascularized flaps[9,12]. These methods, as auxiliary in the above-mentioned research has a positive effect on the effects of tissue healing. However, the MRONJ treatment is controversial[34].

The summaries of adjuvant methods were made by Di Fede et al., In their study they emphasize small groups of patients, frequent lack of randomization, as well as variable inclusion criteria for individual studies. Nevertheless, they regard these methods as the future in the MRONJ treatment[33].

While the methods of MRONJ treatment are widely researched, the methods of treating OUBS are not the subject of intense discussion. One study, although in a small region, assessed the probability of a practicing dentist meeting an OUBS as 2.5% within a year[35]. This seems to be a fairly large percentage with a small number of cases reported in the literature. This highlights the problem of low reporting of this disease.

In the publications, the authors provide two methods of treatment: removal of the lesion [4, 18, 19, 20, 21] or antibiotic therapy, and increased oral

hygiene while waiting for the release of the sequestrum itself[4,21], offering rinses with chlorhexidine for this purpose, and antibiotic therapy using amoxicillin, metronidazole and / or clindamycin[18,19]. The authors agreeably report that pain is quickly relieved after the necrotic tissue is separated[4,19,20].

The two cases we've presented show some interesting and distinct features of OUBS.

In the first case, we have a characteristic localization, possibly asymptomatic course for a long period of time and good healing after sequestrectomy surgery. In the second case the change was not visible in the OPG X-Ray, but in the CT imaging, which is also characteristic of OUBS. It was located in the maxilla, which is definitely a rarer location. The sequestering separation resulted in immediate pain relief and the healing process was uneventful. Both cases also concerned young men, as reported most often by the epidemiology of this disease entity. Although OUBS appears to be a common disease [4], the lack of a clear definition and the small number of published cases result in little awareness among physicians. Nowhere have we found any mention of the use of adjunctive methods for OUBS treamtent as are used in the treatment of MRONJ or ORNJ.

However, it is also important to take into account other pathologies, including the neoplastic etiology of the lesion, and to take a specimen for histopathological examination, as is the case with non-healing lesions.[4,18,19,20,21].

Conclusions

OUBS is still a vaguely defined disease. The lack of defined criteria for diagnosis, as well as the small number of published cases, cause low awareness among doctors. In addition, OUBS seems to occur quite frequently. Studies show similar data, but they are scarce. All this means that there is still little data on treatment. Methods applicable in the treatment of other osteonecrosis are not widely described, although their use by others cannot be ruled out in cases not described in the literature. The current methods are similar to those of MRONJ - conservative treatment focusing primarily on providing an environment for spontaneous healing and surgical treatment. As mentioned, the excretion of necrotic tissue causes a quick regression of symptoms, therefore surgical treatment should be considered more quickly in symptomatic patients [4]. Differential diagnosis and collection of material for histopathological examination is very important, perhaps even before starting treatment.

There is a great need to report OUBS or similar cases to create a clear definition and raise awareness of the disease. This approach may provide an opportunity to develop treatment regimens.

* Patients agreed to have photos published in articles for research purposes. The photos do not identify the patient.

*All authors report no conflict of interest.

Declaration of Interest

The authors report no conflict of interest.

References

1. Marx RE, Pamidronate (Aredia) and zoledronate (Zometa) induced avascular necrosis of the jaws: a growing epidemic. J Oral Maxillofac Surg. 2003 Sep;61(9):1115-7
2. Aravinth H, Don KR, Saravana Dinesh SP. Osteoradionecrosis of mandible - a review. DrugInvention Today 2019;11(1):108-17,
3. Kryst L, Chirurgia Szczękowo-Twarzowa, 5th Edition, Warszawa, PZWL, 2019:144-150
4. Lidhar T, Ethunandan A, Ethunandan M. Spontaneous oral ulceration with bone sequestration: its relevance in current clinical practice. Br J Oral Maxillofac Surg. 2020 Nov;58(9):75-79
5. Rogers SN, Palmer NO, Lowe D, et al. United Kingdom nationwide study of avascular necrosis of the jaws including bisphosphonate-related necrosis. Br J Oral Maxillofac Surg. 2015 Feb;53(2):176-82
6. Kishimoto H, Noguchi K, Takaoka K. Novel insight into the management of bisphosphonate-related osteonecrosis of the jaw (BRONJ). Jpn Dent Sci Rev. 2019 Nov;55(1):95-102
7. Lorenzo-Pouso AI, Bagán J, Bagán L, et al. Medication-Related Osteonecrosis of the Jaw: A Critical Narrative Review. J Clin Med. 2021 Sep 24;10(19):4367
8. Mânea HC, Urechescu HC, Balica NC. et al. Bisphosphonates-induced osteonecrosis of the jaw - epidemiological, clinical and histopathological aspects. Rom J Morphol Embryol. 2018;59(3):825-831
9. Goker F, Grecchi E, Grecchi F, et al. Treatment of medication-related osteonecrosis of the jaw (MRONJ). A systematic review. Eur Rev Med Pharmacol Sci. 2021 Mar;25(6):2662-2673
10. Han AL. The awareness and practice of dentists regarding medication-related osteonecrosis of the jaw and its prevention: a cross-sectional survey. BMC Oral Health. 2021 Mar 24;21(1):155
11. Giudice A, Antonelli A, Chiarella E, e al. The Case of Medication-Related Osteonecrosis of the Jaw Addressed from a Pathogenic Point of View. Innovative Therapeutic Strategies: Focus on the Most Recent Discoveries on Oral Mesenchymal Stem Cell-Derived Exosomes. Pharmaceuticals (Basel). 2020 Nov 25;13(12):423
12. Ruggiero SL, Dodson TB, Fantasia J, et al. American Association of Oral and Maxillofacial Surgeons. American Association of Oral and Maxillofacial Surgeons position paper on medication-related osteonecrosis of the jaw-2014 update. J Oral Maxillofac Surg. 2014 Oct;72(10):1938-56 Erratum in: J Oral Maxillofac Surg. 2015 Jul;73(7):1440 Erratum in: J Oral

Maxillofac Surg. 2015 Sep;73(9):1879
13. Stevens LAS, Spangler L, Yochum L, et al. Assessment of a Claims-Based ICD-9 and ICD-10 Medication-Related Osteonecrosis of the Jaw Algorithm in the United States. Clin Epidemiol. 2021 Oct 28;13:1019-1026
14. Soutome S, Otsuru M, Hayashida S, et al. Relationship between tooth extraction and development of medication-related osteonecrosis of the jaw in cancer patients. Sci Rep. 2021 Aug 26;11(1):17226
15. Drudge-Coates L, Van den Wyngaert T, Schiødt M, et al. Preventing, identifying, and managing medication-related osteonecrosis of the jaw: a practical guide for nurses and other allied healthcare professionals. Support Care Cancer. 2020 Sep;28(9):4019-4029
16. Jackson I, Malden N. Lingual mucosal ulceration with mandibular sequestration. Dent Update. 2007 Nov;34(9):573-4, 576-7
17. Gunduz, K., Ozden B, Kurt, M. et al. Lingual mandibular bone sequesstration. A case report. Journal of Dental Faculty of Ataturk University 2010 (Suppp 3), 1-4
18. Lončar Brzak B, Vučićević Boras V, Kotarac Knežević A, et al. Idiopathic Exposed Bone Lesions of the Jaw. Dent J (Basel). 2019;7(2):55
19. Villa A, Gohel A. Oral ulceration with mandibular necrosis. J Am Dent Assoc. 2014 Jul;145(7):752-6
20. Thermos G, Kalogirou EM, Tosios KI, et al. Oral ulceration with bone sequestration: Retrospective study of eight cases and literature review. Oral Dis. 2019 Mar;25(2):515-522
21. Palla B, Burian E, Klecker JR, et al. Systematic review of oral ulceration with bone sequestration. J Craniomaxillofac Surg. 2016;44(3):257-264
22. Miranda-Silva W, Montezuma MA, Benites BM, et al. Current knowledge regarding medication-related osteonecrosis of the jaw among different health professionals. Support Care Cancer. 2020 Nov;28(11):5397-5404
23. Kaczmarzyk T, Babiuch K, Bołtacz-Rzepkowska E et al. Rekomendacje Grupy Roboczej Polskiego Towarzystwa Stomatologicznego i Narodowego Programu Ochrony Antybiotyków w zakresie stosowania antybiotyków w stomatologii National Medicines Institute, Warszawa 2019
24. Escobedo MF, Junquera S, Gonzalez C, et al. Efficacy of complementary treatment with autologous platelet concentrates and/or mesenchymal stem cells in chemical osteonecrosis of the jaw. Systematic review of the literature. J Stomatol Oral Maxillofac Surg. 2022 Feb;123(1):51-58
25. Zelinka J, Blahak J, Perina V, et al. The use of platelet-rich fibrin in the surgical treatment of medication-related osteonecrosis of the jaw: 40 patients prospective study. Biomed Pap Med Fac Univ Palacky Olomouc Czech Repub. 2021 Sep;165(3):322-327
26. Giudice A, Barone S, Giudice C, et al. Can platelet-rich fibrin improve healing after surgical treatment of medication-related osteonecrosis of the jaw? A pilot study. Oral Surg Oral Med Oral Pathol Oral Radiol. 2018 Nov;126(5):390-403
27. Maluf G, Caldas RJ, Silva Santos PS. Use of Leukocyte- and Platelet-Rich Fibrin in the Treatment of Medication-Related Osteonecrosis of the Jaws. J Oral Maxillofac Surg. 2018 Jan;76(1):88-96
28. Law B, Soh HY, Nabil S, et al. Autologous Platelet-Rich Fibrin (PRF) as an Adjunct in the Management of Osteoradionecrosis and Medication-Related Osteonecrosis of Jaws. Case Series in A Single Centre. *Applied Sciences*. 2021; 11(8):3365
29. Kim JW, Kim SJ, Kim MR. Leucocyte-rich and platelet-rich fibrin for the treatment of bisphosphonate-related osteonecrosis of the jaw: a prospective feasibility study. Br J Oral Maxillofac Surg. 2014 Nov;52(9):854-9
30. Sánchez-Gallego Albertos C, Del Castillo Pardo de Vera JL, Viejo Llorente A, et al. Medication related osteonecrosis of the jaws (MRONJ): Factors related to recurrence after treatment with surgery and platelet rich plasma (PRP) placement. Med Oral Patol Oral Cir Bucal. 2021;26(6):684-690.
31. Yüce MO, Adalı E, Işık G. The effect of concentrated growth factor (CGF) in the surgical treatment of medication-related osteonecrosis of the jaw (MRONJ) in osteoporosis patients: a randomized controlled study. Clin Oral Investig. 2021 Jul;25(7):4529-4541.
32. Goker F, Donati G, Grecchi F, et al. Treatment of BRONJ with ozone/oxygen therapy and debridement with piezoelectric surgery. Eur Rev Med Pharmacol Sci. 2020 Sep;24(17):9094-9103.
33. Di Fede O, Canepa F, Panzarella V, et al. The Treatment of Medication-Related Osteonecrosis of the Jaw (MRONJ): A Systematic Review with a Pooled Analysis of Only Surgery versus Combined Protocols. *International Journal of Environmental Research and Public Health*. 2021; 18(16):8432.
34. Sacco R, Umar G, Guerra RC, et al. Evaluation of segmental mandibular resection without microvascular reconstruction in patients affected by medication-related osteonecrosis of the jaw: a systematic review. Br J Oral Maxillofac Surg. 2021 Jul;59(6):648-660.
35. Incidence of Osteonecrosis of the Jaw Not Associated with Anti-Resorptive Medications by Vandana Singh University of Alberta available at https://era.library.ualberta.ca/items/35db8112-975f-43e0-ace1-920b742bd460 Accessed April 19th 2022 .