Aesthetic Management of Maxillary Left and Right Peg-Shaped Lateral Incisors with Direct Composite Resin during Orthodontic Treatment: A Case Report

Irmaleny[1]*, Anindya Novia Putri[1]

1. Conservative and Endodontics Department, Faculty of Dentistry, Universitas Padjadjaran, Bandung, Indonesia.

Abstract

Peg-shaped tooth is a dental crown anomaly that resembles a blunt conus with reduction of the incisal mesiodistal width compared with cervical region. Interdisciplinary treatment between orthodontics and conservative dentistry can provide excellent treatment result. Aesthetic restoration with direct composite resin is an ideal and conservative treatment option in diastema closure and dental anomalies. In addition, the restoration of peg-shaped teeth can maintain required space during orthodontic treatment. Case Report: A 24-year-old male patient came to Conservative Dentistry clinic RSGM Unpad based on a referral from Orthodontics Department for restoration of both conus shaped maxillary lateral incisors. The patient was undergoing fixed orthodontic treatment and the restoration was expected to maintain proper mesiodistal width in both maxillary lateral incisors. Based on clinical examination, the diagnosis made in this case was normal pulp, normal periapical tissue (AAE, 2013) with dental anomaly peg-shaped teeth 12 and 22. The treatment carried out was direct veneer restoration with composite resin which was preceded by crown lengthening in regions 13, 12, 11, 23.

Aesthetic management of the maxillary right and left peg-shaped incisors gave an aesthetic and satisfactory result, also could maintain the mesiodistal space during orthodontic treatment.

Case report (J Int Dent Med Res 2022; 15(4): 1736-1739)

Keywords: Peg-shaped, aesthetic restoration, direct composite, diastema closure

Received date: 23 July 2022 **Accept date:** 31 August 2022

Introduction

Peg-shaped dental anomaly is defined as an abnormality in the volume and shape of tooth, in the form of malformation in the crown of the tooth that resembles a blunt conus with reduction of the incisal mesiodistal width compared with the cervical region.[1] There are various treatment options available to restore the aesthetic structure and function of the teeth, either directly or indirectly.[2]

Unlike indirect restorations, direct veneer restorations are highly conservative and minimally invasive. Along with the development of adhesive and restorative dentistry, direct veneer restoration is a treatment option that is often performed. This restoration is done by placing a composite resin without performing invasive preparations, therefore the selection of adhesive material is very important and must be applied correctly. If the procedure is carried out correctly, the results of the treatment of direct composite veneers can be very satisfactory aside from good optical and physical properties.[3]

Composite veneer restoration is performed to improve the dental aesthetic. In addition to aesthetic restorations, composite veneer restorations can also last a long time, and restoration defects are easily repaired.[2] In orthodontic treatment with peg-shaped anomalous teeth, composite veneer restorations are needed to maintain the space formed by the anomalous teeth.

There are various treatment options for peg-shaped dental anomalies, such as direct veneers, indirect veneers, or dental crowns, each of which has its own advantages and disadvantages. Direct composite veneer treatment has several advantages such as preserving the existing healthy tooth structure, can be placed directly on the teeth, and is more conservative. In addition, direct composite veneers are easy to apply, can cover diastemas, can be repaired easily, can be repaired in the future, are durable, and are relatively inexpensive compared to indirect restorations.[2]

Corresponding author:
Irmaleny,
Conservative and Endodontics Department, Faculty of Dentistry, Universitas Padjadjaran, Bandung, Indonesia.
E-mail: irmaleny@fkg.unpad.ac.id

Case Report

A 24-year-old male patient came to the Dental Conservation Clinic of RSGM Unpad based on a referral from the Orthodontics Department of FKG Unpad for a peg-shaped composite restoration on teeth 12 and 22 to maintain the existing space for the lateral incisor. The patient also felt aesthetically disturbed when he smiled because of the different shape of the teeth and there seemed to be gaps between his teeth. There was no pain in both teeth and the patient did not have a history of systemic disease. The patient has been undergoing fixed orthodontic treatment for 3 years and will continue to do so. Patient wants to improve his appearance, Figure 1.

Figure 1. Initial Clinical Photo. Initial clinical photo shows the presence of diastema in the peg-shaped teeth on region 12 and 22.

Physical examination showed normal vital signs with blood pressure 120/80 mmHg, respiration 21 breaths per minute, and pulse 75 beats per minute. Extra-oral examination showed that the face was symmetrical, the lips were not deformed, the TMJ was normal, the lymph nodes were not palpable and painless.

On intra-oral examination, teeth 12 and 22 were peg-shaped with a 2-3 mm mesial and distal diastema, vital, no caries and tooth mobility. Percussion, pressure, and palpation tests showed a negative response and the surrounding tissue had no abnormalities. The diagnosis made in this case was normal pulp, normal periapical (AAE, 2017) with conical tooth anomaly on teeth 12 and 22. The treatment plan in this case was direct veneer restoration on teeth 12 and 22 to maintain space and improve the patient's appearance which was preceded by a crown lengthening procedure.

First Appointment

On the appointment, examination and analysis of the asymmetrical gingival height was performed, and a crown lengthening procedure was planned. The orthodontic bracket on the maxillary anterior teeth was removed first to accurately measure the depth of the gingival sulcus and to determine the colour shade of the teeth. The gingival sulcus depth was measured using a William periodontal probe and probing results on the labial sides of teeth 13, 12, 11, and 23, were: 3-2-4, 3-4-3, 2-2-4, and 5 -3-5, respectively. Then, the proportions of teeth were measured on teeth 12 and 22 using Chu's Aesthetic Gauges, and tooth shade colour was determined, Figure 2.

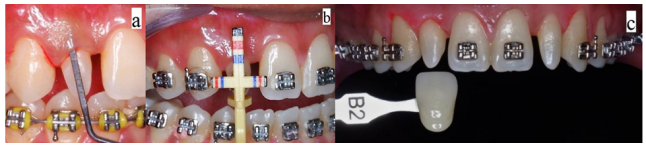

Figure 2. (a) Gingival sulcus measurement using William probe. (b) Tooth proportion measurement. (c) Colour shade selection procedure.

Subsequently, impressions of the maxillary and mandibular arches were done to obtain a working model, thus tooth waxed up of 12 and 22 were made to establish a palatal matrix. Smile analysis was performed on the maxillary anterior teeth digitally, and the crown lengthening design and final shape of teeth 12 and 22 were determined. Based on the analysis, the heights of teeth 12, 12, 11, and 23 were not symmetrical between the left and right regions, so a 1-3 mm gingivectomy was performed to obtain a symmetrical gingival line, Figure 3.

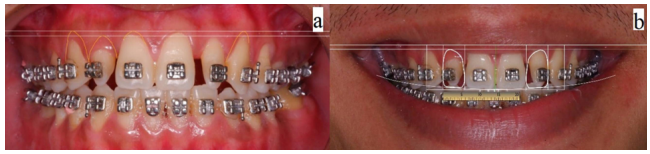

Figure 3. (a) Gingival line symmetry analysis. (b) Smile analysis design on maxillary left and right lateral incisors.

Second Appointment

On the second appointment, intraligamentary anaesthesia in the working area was carried out first using Lidocaine HCl 1:100,000. The crown lengthening procedure was carried out by gingivectomy in regions 13, 12, 11, and 23 using Bonart Electrosurgery E1 ART until the gingival height was symmetrical on the left and right sides, Figure 4.

Figure 4. (a) Crown lengthening procedure using a cauter on tooth 12. (b) Crown lengthening result.

After the crown lengthening procedure, the patient was instructed to go home and take the analgesic mefenamic acid if there was pain after the procedure. The patient was asked for a one-week follow-up to see the gingival healing and for direct veneer restorations on teeth 12 and 22.

Third Appointment

The patient came one week after the gingivectomy procedure for a follow-up. Gingival healing was satisfactory, there were no complaints, and a symmetrical gingival line was obtained so that a direct veneer procedure could be performed, Figure 5.

Figure 5. One week follow up post crown lengthening with gingivectomy.

The direct veneer treatment was initiated by removing the entire orthodontic bracket in the maxillary anterior region to obtain good visualisation of the maxillary anterior teeth. The rubber dam was placed using a split dam technique until all anterior teeth were visible (P1-P1). Minimally invasive preparations were performed using a coarse polishing disc (Sof-lex disc, 3M ESPE St. Paul, MN, USA) to roughen the tooth surface. The etching procedure was then carried out with 35% phosphoric acid for 20 seconds, rinsed thoroughly and dried. After the tooth were etched, the bonding material (Palfique Bond, Tokuyama) was applied by rubbing on the tooth surface using a microbrush and polymerized using an LED curing unit for 15 seconds (Elipar 3M ESPE St Paul, MN, USA).

The veneer procedure was performed using 3 shades of Palfique LX5 Tokuyama composite, BL shade for the palatal shell, A1B shade for the dentin structure, WE shade for the enamel structure. The first step is to form the palatal part (palatal shell) with the guidance of the palatal matrix. The formation of the labial part is done incrementally from palatal to labial, then the shape is adjusted using a soflex disc coarse (3M ESPE). Polishing was carried out using Eve Diacomp Twist Polishing to obtain a smooth and shiny surface, Figure 6.

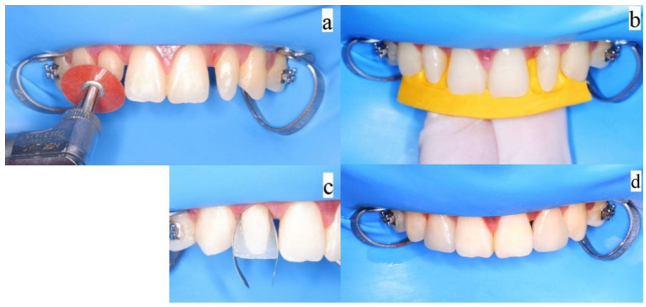

Figure 6. (a) Minimally invasive preparation procedure by roughing the tooth surface with coarse. (b) Palatal matrix placement. (c) Palatal shell that has been created. (d) Direct composite veneer restoration result on tooth 12 and 22.

Discussion

The development of the human dentition is regulated by tissue interactions and genetic networks that involves interactive and self-organizing mechanisms which are crucial for the serial organization of teeth and their morphological profile and renewal.[4] Conical tooth anomaly can cause aesthetic and functional disturbances related to the shape and size of the teeth, which are narrower, resulting in a diastema.[5] Anterior diastema can affect on appearance of a person's smile. Many patients improve that with orthodontic treatment or restorative bonding. Increasing patient demand for optimal aesthetics has resulted in the extensive utilization of composite resin bonding because it involves less invasive procedures.[6]

In this case, the patient was undergoing ongoing orthodontic treatment so that a direct veneer restoration was required to maintain the mesio-distal distance of the maxillary left and right lateral incisors. The purpose of veneer restoration is to maintain the mesiodistal space of the lateral incisors so that the rest of the anterior teeth are not displaced or shifted position.

Direct composite restorations are an ideal treatment option for peg-shaped maxillary lateral incisors because they are highly conservative and aim to close the diastema and restore normal tooth contour.[7] This restoration is easily applied, fast, and very flexible because the operator can make additions, reductions, and adjustments easily.

A crown lengthening procedure by performing a gingivectomy to obtain a symmetrical gingival height is performed before direct composite veneer were done. Prior to the direct composite veneer, the crown lengthening procedure was performed by performing a gingivectomy to obtain a symmetrical gingival height. This procedure aims to correct the gingival asymmetries and reposition the dentogingival complex as a follow-up to the periodontal esthetic procedure if necessary.[8] In order not to interfere with the existing biological width, it is necessary to measure the depth of the gingival sulcus. Chu aesthetic gauges is a tool used to measure the amount of gingival sulcus that must be removed in the crown lengthening procedure so that it is easier to obtain the ideal tooth proportion. The reading of the instrument is based on the colour-coded gauge (blue, red, and black). The use of this tool greatly facilitates the operator in performing aesthetic rehabilitation of anterior teeth.[8]

The procedure for placing direct veneer restorations that are carried out correctly will provide satisfactory treatment results.[9] In this case, the restoration successfully achieves the ideal width and height of the lateral incisor. Patients are satisfied with the treatment results and become more confident when smiling, Figure 7.

Figure 7. Patient profile picture before (left) and after (right) treatment.

The patient was asked to do a follow up in one week and every 6 months thereafter to see if chipping or discoloration occurred in the marginal area. If this occurs, then a re-polishing procedure or composite addition can be carried out in the required area. In addition, it is important to continue to maintain the overall health of the patient's periodontal tissue, considering that the patient is still undergoing orthodontic treatment so that the patient has a tendency to accumulate plaque in order for composite restorations to last for a long time.[10]

Conclusions

Aesthetic restoration such as direct veneers on the maxillary right and left peg-shaped lateral incisors gave an aesthetic, satisfactory result, and was able to maintain the mesio-distal space during orthodontic treatment.

Acknowledgements

This article get no funding support from any resource grant.

Declaration of Interest

The authors report no conflict of interest.

References

1. Aydin, Numan, et al. Aesthetic restoration of peg lateral incisors with direct composite resin. Gülhane Faculty of Medicine 2019 / doi: 10.26657 / gulhane.00048. Gulhane Med J 2019;61: 25-27
2. Greenwall L. Treatment options for peg-shaped laterals using direct composite bonding. Int Dent SA [Internet]. 2006;12(1):26–33. Available from: http://www.moderndentistrymedia.com/jan_feb2010/greenwall.pdf
3. Bagis B, Aydoğan E, Bagis YH. Direct restorative treatment of missing maxillary laterals with composite laminate veneer: a case report. Open Dent J. 2008;2:93-95. doi:10.2174/1874210600802010093
4. Kifayatullah J, Ali S, Shahid F, Farooq I, Nowrin SA, Ansari MAA, Alam MK. The Prevalence of Peg Shaped and Missing Permanent Maxillary Lateral Incisors In Non-Syndromic Orthodontic Patients. J Int Dent Med Res [Internet]. 2019;12(4):1416–20. Available from: http://www.jidmr.com
5. Korkut B, Yanıkoğlu F, Günday M. Direct composite laminate veneers: three case reports. J Dent Res Dent Clin Dent Prospects. 2013;7(2):105–111. doi: 10.5681/joddd.2013.019.
6. Bahşi E, Callea M, İnce B, Montanari M, Dallı M, Batteli F, Akdoğan M, Gabriella C, Toptanci IR, Gabriella P, Yavuz İ. A Composite Laminate Veneer Technique for Diastema Closure: A Report of Ten Cases. Int Dent Res. 2012;2(3):67.
7. Korkut B. Smile makeover with direct composite veneers: A two-year follow-up report. J Dent Res Dent Clin Dent Prospects. 2018;12(2):146-151. doi:10.15171/joddd.2018.023
8. Nautiyal, Aruna. Aesthetic Crown Lengthening Using Chu Aesthetic Gauges And Evaluation of Biologic Width Healing. Journal of Clinical and Diagnostic Research. 2016 Jan, Vol-10(1): ZC51-ZC55DOI: 10.7860/JCDR/2016/14115.7110
9. Paolone G. Direct composite restorations in anterior teeth Managing symmetry in central incisors. Int J Esthet Dent. 2014;9(1):12–25.
10. Carlos J, Barrantes R, Araujo E, Dds J. Clinical Evaluation of Direct Composite Resin Restorations in Fractured Anterior Teeth Evaluación Clínica de Restauraciones Directas con Resina Compuesta en. Odovtos - Int J Dent Sci. 2015;(16):47–61.