Management of Talon Cusp with Bioceram : A Case Report

Adel Alotaibi[1,2]*, Hussah Alshaikh[1]

1. College of dentistry, king Saud bin Abdulaziz university for health sciences.
2. King Abdullah International Medical Research Center.

Abstract

Talon cusp is an additional cusp that usually found on palatal surface of an anterior tooth. Its presence could lead to multiple complications. occlusal interference is one of these complications that if left untreated, it might lead to serious consequences such as mobility and traumatic injuries to the opposing tooth.

In recent years, vital pulp therapies have been optimal in management of moderate to severe talon cusps with occlusal interferences. These therapies were mainly dependent on the use of MTA. However due to its difficult handling and the discoloration that it caused; it has been slowly replaced by Bioceram. In addition to not having these flaws, Bioceram has the advantage of completing the treatment in one visit which is more convenient.

In this case report we discuss the use of Bioceram on sever talon cusp that affected the upper incisor resulting in its occlusal interference with the opposing incisor. We used Biocerm as direct pulp medicament after the reduction of the talon cusp.

Case report (J Int Dent Med Res 2022; 15(4): 1740-1742)

Keywords: Talon cusp, vital pulp therapy, bioceram.

Received date: 24 July 2022 **Accept date:** 31 August 2022

Introduction

Talon cusp is a rare dental anomaly that appears as an additional cusp structure from palatal/lingual or facial surfaces of the anterior teeth for at least half of the inciso-cervical distance[1]. This can be seen in both dentitions affecting anterior teeth with higher frequency towards the maxilla. Central incisors are generally affected in primary dentition, whereas maxillary lateral incisor is more involved in permanent dentition[2]. A previous study was conducted in Saudi Arabia confirmed that Talon cusp is more common in males than females and maxillary lateral incisors[3]. Talon cusps are classified based on the degree of their formation and extension into three types: Type 1 (talon), type 2 (semi talon), and type 3 (trace talon)[4].

The existence of talon cusps can cause various clinical problems, including caries, periapical lesions, tongue and other soft tissue irritation during function, esthetic problems, occlusal interference, tooth displacement, temporomandibular joint pain, and periodontal problems due to the excessive occlusal forces[5].

Several treatment methods have been used to manage talon cusps depending on the presence or absence of pulpal extension. Other factors play a role in making the right treatment choice such as occlusal interference, cooperation of the patient and root development stage. Management of Talon cusp could include case monitoring, gradual or total reduction of the cusp or vital pulp therapy followed by final restoration[6].

Mineral trioxide aggregate (MTA) has been widely used in the endodontic field but it has several disadvantages that includes; tooth discoloration, long setting time, manipulation difficulty, and high cost. Contrarily a calcium-silicate-based material is an emerging and well-established material in endodontic applications[7,8]. Previous studies have found that calcium-silicate-based bioceramics (Bioceram) have better biocompatibility and sealing ability than MTA[7–9]. In addition, it has less discoloration possibility, which can be suitable to use in the esthetic teeth zone[10].

The presence of pulp tissue in a talon cusp will potentially cause a challenge in treatment of such affected teeth. This article describes the clinical management of a patient

Corresponding author:
Adel Alotaibi
College of dentistry, King Saud bin Abdulaziz University for Health Sciences.
E-mail: otaibiad.ksau@gmail.com, otaibiad@ksau-hs.edu.sa

presenting a talon cusp in the permanent maxillary right central incisor using pre-mixed bioceramic putty material.

Case Report

An 11 years old boy was presented to our clinic with a complaint of “abnormal front tooth affecting his bite”. His medical and family history was all with in normal. His dental history revealed no similar anomaly was noticed before.

Upon oral examination, patient was in mixed dentition, had multiple carious lesions and restorations. He had a Talon cusp affection the maxillary central right incisor #11 that extends from the cingulum to nearly the incisal edge (Fig. 1). The Talon cusp was interfering with normal occlusion as It was occluding prematurely with the mandibular central right incisor #31(Fig.2).

Figure 1. Intraoral occlusal view of #8.

Figure 2. Intraoral Right lateral view #8 with the talon cusp interfering #25.

Dental radiographs revealed no abnormality in bone or periapical area. It also revealed that the Talon cusp contained a pulpal tissue.

Treatment options which included gradual enameloplasty, direct pulp capping or partial (Cveck) pulpotomy were discussed to the parents. The benefits and risks of each option were explained. They opted for direct pulp capping as they wanted preserve tooth structure and they lived in a rural area where gradual enameloplasty will not be convenient.

The treatment was done as the following:

Local anesthesia (Lidocaine hydrochloride 2% and adrenaline 1;80000) buccal infiltration of #11 and rubber dam isolation.

Reduction of the Talon cusp using high-speed handpiece with air, water and wheel diamond bur.

Pin-point pulp exposure occurred while doing the reduction (Fig.3).

Placemat of bioceramic putty (FKG TotalIFill ®) as a direct pulp capping material.

Application of etchant (37% phosphoric acid ALPHA ETCH37 ®).

Application of bonding agent (Total etch dental adhesive Tertic®N-Bond).

Placement of composite as final restorative material (Fig.4)

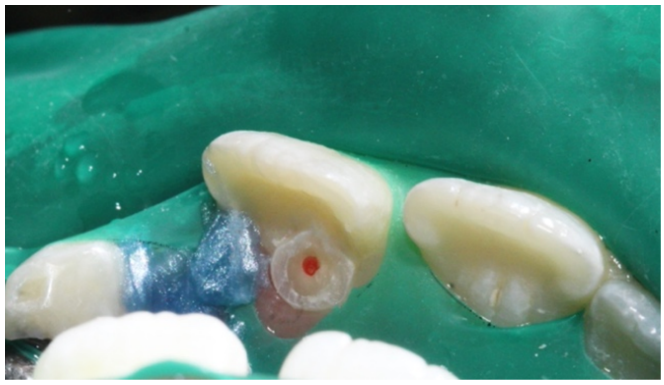

Figure 3. Occlusal view of pin-point pulp exposure.

Discussion

The management of talon cusp has been mostly the reduction of the cusp over several visits resulting either total or partial removal of the cusp [11]. This approach is appropriate for mild to moderate cases but has the disadvantage of needing multiple visits to be performed. It may also cause sensitivity as well as carrying the risk for pulp exposure [11,12].

The classical management of moderate to severe talon cusp cases were mostly root canal treatment (RCT). RCT has its own disadvantages

especially when performed for children. multiple visits and cooperation could be an obstacle for management of such cases.

Figure 4. Occlusal view of final composite after direct pulp capping with Bioceram.

Vital pulp therapies have gained more confidence in the last decade due to the development of biocompatible materials such as MTA and Bioceram[13]. Although direct pulp capping has less success rate than partial pulpotomy (Cveck pulpotomy) In cases of carious exposure, it's still has a good success rate for cases of traumatic exposure[14]. It is recommended by the American Academy of Pediatric Dentistry (AAPD) for such cases in young permanent teeth[14].

In this case the parents and child were interested in removal of the talon cusp interference in one visit, hence the choice of doing vital pulp therapy with Bioceram and the placement of composite as final restoration.

The use of Bioceram has multiple advantages over the use of MTA in vital pulp therapies. One of these is not causing a discoloration when compared to MTA[15]. This is critical in anterior teeth where aesthetic is a critical factor. The other advantage is fast setting time which allow for the placement of the final restoration in one visit [15]. Additionally , Bioceram has a similar success rate to MTA in recent systematic review [16].Although MTA has been researched extensively in the vital pulp therapies, Bioceram is slowly replacing MTA due to the previous reasons[6,17].

Conclusions

We describe the use of Bioceram in the management of severe talon cusp in this case report. This intervention was successful due current evolution of endodontic biocompatible material.

Declaration of Interest

The authors report no conflict of interest.

References

1. Ozer SY. Talon Cusp: A Literature Review and 3 Case Reports. Journal of International Dental and Medical Research. 2009 Aug 1;2(2):45-9.
2. Dash JK, Sahoo PK, Das SN. Talon cusp associated with other dental anomalies: A case report. Int J Paediatr Dent. 2004;14(4):295-300.
3. Yassin SM. Prevalence and distribution of selected dental anomalies among saudi children in Abha, Saudi Arabia. J Clin Exp Dent. 2016;8(5):e485-e490.
4. Hattab FN, Yassin OM, Al-Nimri KS. Talon cusp in permanent dentition associated with other dental anomalies: Review of literature and reports of seven cases. J Dent Child. 1996;63(5):368-376.
5. Güngör HC, Altay N, Kaymaz FF. Pulpal tissue in bilateral talon cusps of primary central incisors: Report of a case. Oral Surg Oral Med Oral Pathol Oral Radiol Endod. 2000;89(2):231-235.
6. Tsujino K, Shintani S. Intentional Partial Pulpotomy for Treatment of Immature Permanent Maxillary Incisor with Talon Cusp. Bull Tokyo Dent Coll. 2017;58(4):247-253.
7. Elshamy FMM, Singh G, Elraih H, Gupta I, Idris FAI. Antibacterial effect of new bioceramic pulp capping material on the main cariogenic bacteria. J Contemp Dent Pract. 2016;17(5):349-353.
8. Tuna EB, Dinçol ME, Gençay K, Aktören O. Fracture resistance of immature teeth filled with BioAggregate, mineral trioxide aggregate and calcium hydroxide. Dent Traumatol. 2011;27(3):174-178.
9. Yan P, Yuan Z, Jiang H, Peng B, Bian Z. Effect of bioaggregate on differentiation of human periodontal ligament fibroblasts. Int Endod J. 2010;43(12):1116-1121.
10. Kohli MR, Yamaguchi M, Setzer FC, Karabucak B. Spectrophotometric analysis of coronal tooth discoloration induced by various bioceramic cements and other endodontic materials. J Endod. 2015;41(11):1862-1866.
11. Potgieter N, Davidson C, Middleton I. Minimally invasive management of a labial talon cusp: Clinical review and case report. South African Dent J. 2019;74(9):491-495.
12. Yaziciołlu O, Ulukapi H. Management of a facial talon cusp on a maxillary permanent central incisor: A case report and review of the literature. J Esthet Restor Dent. 2014;26(6):374-381.
13. Gupta R, Thakur N, Thakur S, Gupta B, Gupta M. Talon cusp: A case report with management guidelines for practicing dentists. Dent Hypotheses. 2013;4(2):67-69.
14. Kratunova E, Silva D. Pulp therapy for primary and immature permanent teeth: An overview. Gen Dent. 2018;66(6):30-38.
15. Alsubait S, Al-Haidar S, Al-Sharyan N. A Comparison of the Discoloration Potential for EndoSequence Bioceramic Root Repair Material Fast Set Putty and ProRoot MTA in Human Teeth: An In Vitro Study. J Esthet Restor Dent. 2017;29(1):59-67.
16. Shaik I, Dasari B, Kolichala R, et al. Comparison of the Success Rate of Mineral Trioxide Aggregate, Endosequence Bioceramic Root Repair Material, and Calcium Hydroxide for Apexification of Immature Permanent Teeth: Systematic Review and Meta-Analysis. J Pharm Bioallied Sci. 2021;13(Suppl 1):S43-S47.
17. Logani A, Shah N, Kumar V, Chawla A. Mineral trioxide aggregate pulpotomy: An ideal treatment option for management of talon cusp. Contemp Clin Dent. 2012;3(4):491.