Maxillofacial Prosthesis: Hollow Customized Ocular Prosthesis Rehabilitation in Patient with Large Orbital Defect - Case report

Ivony Fitria[1], Gunawan[2], Lisda Damayanti[3], Valentine Rosadi Sinaga[3], Calvin Atherton[3]

1. Departement of Prosthodontics Faculty of Dentistry, Andalas University, Padang – Indonesia.
2. Departement of Oral and Maxillofacial Surgery and Radiology Faculty of Dentistry, Andalas University, Padang – Indonesia.
3. Departement of Prosthodontics Faculty of Dentistry, Padjadjaran University, Bandung – Indonesia.

Abstract

The ocular prosthesis is a type of maxillofacial prosthesis that restores the function of eye structure due to eye loss. Ocular prostheses are frequently available in stock fabricated form, however, customized prostheses are recommended for more aesthetic results.

This case report aims to describe the treatment of an ocular prosthesis and the methods and steps to make a custom ocular prosthesis for a patient with orbital defect.

A patient with an enucleation defect and a history of wearing a stock ocular prosthesis wanted to have a custom ocular prosthesis. The old prosthesis was uncomfortable, and felt insecure about her appearance. Case Management: The lightbody impression was taken in the patient's eye, creating wax-up and acrylic prosthesis. The placement of the iris and pupil was assessed to perform the normal appearance in the patient. A hollow-type acrylic was formed to avoid excessive weight on the prosthesis. The patient was delighted with the results of the treatment.

Custom ocular prosthesis fabrication requires longer stages and duration compared to a stock prosthesis but will provide more satisfactory results in terms of function and aesthetics.

Case report (J Int Dent Med Res 2023; 16(4): 1734-1737)

Keywords: Ocular prosthesis; custom; orbital defect; maxillofacial prosthesis.

Received date: 01 September 2023 **Accept date:** 28 October 2023

Introduction

Eye loss is a maxillofacial deformity that significantly affects aesthetics because the eye is one of the facial components easily seen in a person's appearance.[1,2] This deformity is commonly caused by eye removal due to a surgical procedure. The etiological factors are classified into two, i.e., congenital, such as malformations and developmental disorders, and acquired such as pathological factors such as disease, necrosis, oncosurgery, or trauma.[3,4]

Patients who undergo eye removal surgery need an ocular prosthesis. An ocular prosthesis is a type of maxillofacial prosthesis which aims to reconstruct the structure of the missing part of the eye. This ocular prosthesis is available as stock ocular prostheses or custom-made.[5,6,7] A study reviewed the use of the ocular prosthesis in Asia, South America, Europe and Africa. According to the study, 87.94% cases using the customized ocular prosthesis, 11% cases using the costumized fabrication, and 0.95% using the stock ocular prosthesis.[7]

The stock ocular prosthesis is available in prefabricated form, so it doesn't require much time for fitting appointment and easy to find. However, stock ocular prostheses commonly do not provide the size, color, and contour that match the condition of the patient's eye socket, so the patient is force to use the sizes and shapes that are available.[2,3] This makes the stock ocular prostheses do not adapt properly with mucosal tissue.[2]

This article aims to describe about the procedure and manufacturing of customized ocular prosthesis in patient with large orbital defect after using stock ocular prostheses with hollow design.

Case Report

A 52-year-old woman came to the Dental Hospital Faculty to have customized ocular

***Corresponding author:**
Gunawan,
Faculty of Dentistry, Andalas University, Jl. Perintis Kemerdekaan no 77, Jati Baru,
Kota Padang- 25129, Indonesia.
E-mail: gunawan.sp.rkg@gmail.com

prosthesis because the ocular prosthesis she used before were no longer comfortable to wear and felt loose. The patient had a history of removal of the left eyeball post enucleation due to a congenital disease. The right eye's function had decreased, but she could still see with blurry vision. Previously, the patient had used a stock eye in the left eye installed in a private hospital. The patient had used stock eye because of limited information about ocular prosthesis manufacturing services. However, it was loose and difficult to move according to the eye movement she wanted. The patient felt insecure about her condition.

The objective examination found sufficient socket volume in the left eye, adequate depth, and drooping of the upper eyelid (Figure 1). The patient planned to have a new acrylic ocular prosthesis adapted to the existing eye socket. It was decided to be observed the right eyeball because the patient could still see image blurry.

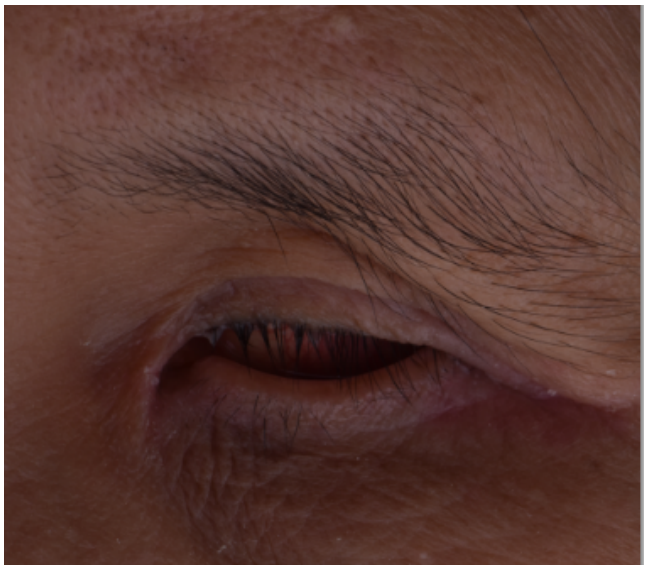

Figure 1. Left eyes of the patient.

The clinical step that the patient has to go trough is the ocular impression, wax pattern fabrication and verification, iris centering and positioning selection, additioning sclera, processing, insertion, and follow up.[5] Firstly, vaseline was applied to the surface around the eyelids and eyelashes to avoid adherence to the impression material. The patient was seated in the dental unit and the eye socket was impressed with lightbody impression material. While taking the impression, the patient was instructed to make left, right, up, and down movements. Before the impression material sets, a pin was driven into the impression material to keep it on the position when it was removed from the socket (Figure 2A). Then, a mold was made from alginate impression material, which will later be used to make a temporary wax pattern for the eyeball (Figure 2B). This wax pattern was applied into the patient's eye socket to assess the need of adjustments for the facial size of the prosthesis.

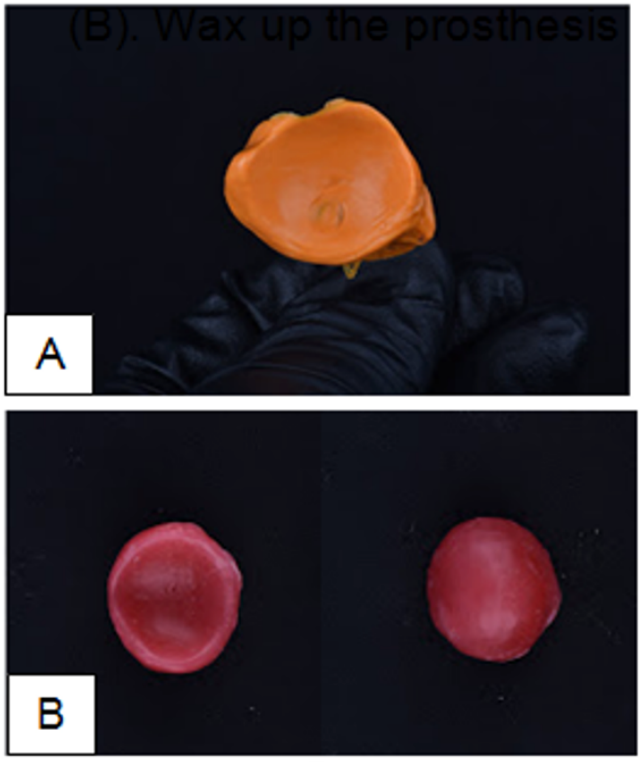

Figure 2. (A.) The impression result with lightbody impression material, (B). Wax up

After obtaining the wax up with the shape and size that fits the patient's eye socket, the prosthesis made of wax was processed into acrylic (Figure 3A). The acrylic form was applied into the patient's eye socket to set the center position. The position and size of the iris were marked with a marker to assess the patient's normal appearance.

The pupil, iris area, and details of the sclera were painted manually with acrylic paint and matched to the shape and color of a normal eye. The acrylic prostheses were manufactured with a hollow design so that the eyeballs were light enough. The backside of the acrylic was split into two parts; the inner part was reduced for a hollow design to reduce the acrylic eyeball weight. The facial area of the prosthesis was

reduced, then two acrylic parts were put together and repacked with clear acrylic to obtain a shiny coating covering the entire facial surface (Figure 3B).

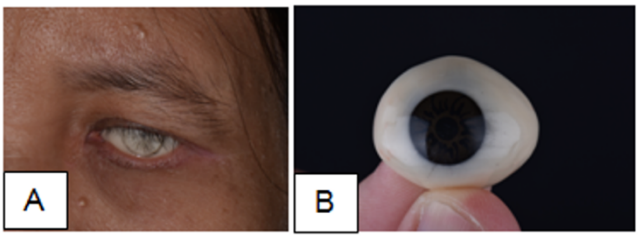

Figure 3. (A) Marking acrylic for pupil and iris placement, (B) Final Ocular prosthesis.

The prosthesis placement in the patient's eye socket was assessed (Figure 4). The operator instructed the patient to relax and move his ocular prosthesis to identify any discomfort. After confirming the patient's comfort, the patient was sent home and instructed to keep the prosthesis hygiene and clean. The patient requested to attend a control visit a week later.

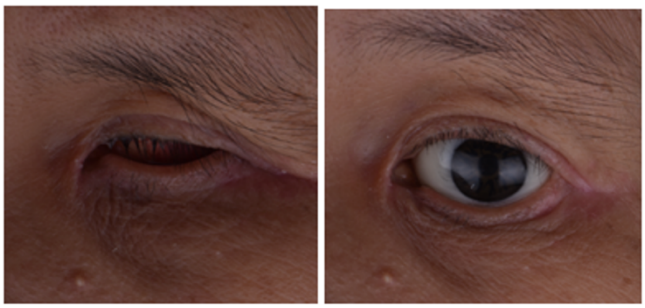

Figure 4. Ocular prosthesis post insertion.

The control procedure was carried out a week later, and the patient was satisfied and had no complaints regarding the new ocular prosthesis. The patient's family was pleased with the treatment results, which makes the patient feel confident again with their appearance.

Discussion

The use of the eye prosthesis is to restore the anatomical defects after eye loss. It doesn't restore the vision, however it could enhance the psychological, psycosocial dan the aesthetic of the patient, so they don't have to be embarrassed by their condition.[7] The need for aesthetics and the restoration of eye muscle function after surgery is the goal of making ocular prostheses to fill sockets in empty eye sockets as to improve the patient's quality of life.[8,9] Making ocular prostheses can increase the patient's self-confidence and provide a sense of social acceptance.[10]

On the other hand, the customized ocular prosthesis has more advantages such as the good adaptation to the mucosal tissue, can be adjusted to the shape and the color of iris according to the patient's eyes so that it can provide aesthetic enhancement.[5,7] The good adaptation between the prosthesis and the mucosa will be able to control the tear secretion, and minimize the inflammation of the eye socket.[6] The shape and size adapt to the patient's eye socket and minimize the risk of irritation or injury to the conjunctiva.[11] Several study found that restoring the eye socket with an ocular prosthesis can increase the electrical activity of the orbicularis oris muscle and restore muscle shape and function of the muscles around the eye.[10,12] The hollow is an option if the patient has a large eye to reduce weight.[13] With various techniques and methods that can be adapted to the cases encountered, the operator's ability and the availability of materials and tools.[8]

The biggest challenge in fabricating an ocular prosthesis is to produce a prosthesis that gives the patient a natural appearance. Natural color, size, contour, and orientation are important factors that must be considered to achieve maximum treatment results.[9,14] The patient was instructed to move the eyeball in all directions during the impression, wax try-in, and acrylic patterns to get the optimal size, contour, and eyelid support. The center is marked to assess for centralization and symmetry between the eyes to set the pupil and iris.[5,15] The characteristic of patient's sclera should be reproduced to get the result that resemble the anatomy of the contralateral eye. For the final step of the ocular manufacturing process, the outer surface should be applied with clear acrylic to coat the characteristic of iris, pupil and sclera of the prosthesis.[5]

Along with technological advances, many studies have been conducted to develop new materials and methods to manufacture maxillofacial prostheses to restore orofacial defects. In the manufacture of ocular prostheses, more modern techniques can be used, such as 3D printing and digital imaging. This technique can reduce the visit time and can improve the replication process.[4] However, the modernization

of several technique requires costs and complete facilities.[4]

Aesthetically, an ocular prosthesis is helpful to prevent complications such as ulcers, infection, and tissue retraction and avoid the collapse of the eyelids and eyebrows muscles.[10,12] However, multidisciplinary fields involving ophthalmologists, surgeons, and maxillofacial prosthodontics are needed to produce optimal treatment results.[8,16]

Conclusion

In patients with eye loss, an ocular prosthesis may be recommended so that the patient can maintain their natural appearance. Customized ocular prosthesis is the main option for treatment to restore the aesthetics and maintain the function of the muscles around the eyes. In this way, the patient's quality of life is expected to be better.

Declaration of Interest

The authors report no conflict of interest.

References

1. Sathe S, Pisulkar S, Nimonkar SV, Belkhode V, Borle A. Positioning of iris in an ocular prosthesis: A systematic review. J Indian Prosthodontic Society. 2020;20(4):345–52.
2. Nizami MMUI, Rahman AM, Jamayet N Bin, Ab-Ghani Z, Husein H. Prosthetic rehabilitation of an oocular defect- A case report. International J Life Science Pharma Research. 2021;11(6):1–25.
3. Pine KR, Sloan BH, Jacobs RJ. Clinical Ocular Prosthetics. New Zealand: Springer International Publishing; 2015. 1–22.
4. De Caxias FP, Dos Santos DM, Bannwart LC, De Moraes Melo Neto CL, Goiato MC. Classification, History, and Future Prospects of Maxillofacial Prosthesis. International J Dentistry. 2019;2019:1–7.
5. Gali S, V M, Naimpally A, B L, Meleppura K, Bandhary C. Troubleshooting ocular prosthesis: A case series. Asian J Pharm and Bioall Sci. 2017;7(10):1–5.
6. Chinnery H, Thompson SBN, Noroozi S, Dyer B. Scoping review of the development of artificial eyes throughout the years. Edorium J Disabil Rehabil. 2017;3:1–10.
7. Launardo V, Nurrahma R, Syamsuddin RW, Mude AH, Sari BI. Prosthetic rehabilitation of patient with ocular defects using conventional technique: A systematic review. Sys Rev Pharm. 2020;11(9):20–5.
8. Farook TH, Rahman AM, Nizami MMUI, Amin M, Jamayet N Bin, Alam MK. Case report: Custom made ocular prosthesis for acquired eye defect A definitive option of rehabilitation. Bangladesh J Medical Science. 2019;18(4):823–6.
9. Lanzara R, Thakur A, Viswambaran M, Khattak A. Fabrication of ocular prosthesis with a digital customization technique- A case report. J Family Med Prim Care. 2019;8:1239–42.
10. Goiato MC, Dos Santos DM, de Sousa Ervolino IC, Brunetto JL, de Magalhaes Bertoz AP, de Moraes Melo Neto CL. Prostetic Rehabilitation of an Eye Globe: Case Report. Med Arch. 2019;73(6):433–5.
11. Effendi R, Dahlan A. Rehabilitation of Post Evisceration patient with ocular prosthetic: A clinical report. World J Advanced Research Reviews. 2022;15(2):29–36.
12. Rokohl AC, Kopecky A, Trester M, Wawer Matos PA, Pine KR, Heindl LM. Post-enucleation socket syndrome - A novel pathophysiological definition. Graefe's Arch Clin Exp Ophthalmol. 2022;260(8):2427–31.
13. Pisulkar SK, Mistry R, Godbole S, Borle A, Sathe S. Customized Hollow Occular Prosthesis. J Evolution Med Dent Sci. 2019;8(48):3646–8.
14. Arif F, Ariyani A, Tamin HZ. Modified functional ocular impression of post-enucleation socket: A case report. Indonesan J Prosthodontics. 2021;2(2):61–5.
15. Belkhode VM, Nimonkar S V., Chaudhary SC, Hakkepatil A, Nimonkar P, Prajapat J. An innovative method for iris positioning in a prosthetic eye. J Contemp Dent Pract. 2020;21(7):815–8.
16. Pompa G, Brauner E, Jamshir S, De Angelis F, Giardino R, Di Carlo S. Quality of life in patients rehabilitated with palatal obturator without reconstruction versus fixed implant-prosthesis after reconstruction of maxillectomy defects. J Int Dent Med Res. 2017;10(1):1–8.