

## Mandibular Cortex Correlates to Alveolar Bone Density in Indonesian Women Aged 40 to 75 Years

Lilies Dwi Sulistyani<sup>1\*</sup>, Menik Priaminiart<sup>2</sup>, Elza Ibrahim Auerkari<sup>3</sup>,  
Lindawati Soetanto Kusdhany<sup>4</sup>, Benny Sjariefsjah Latief<sup>1</sup>

1. Department of Oral and Maxillofacial Surgery, Faculty of Dentistry, Universitas Indonesia, Jakarta 10430, Indonesia.
2. Department of Dental and Maxillofacial Radiology, Faculty of Dentistry, Universitas Indonesia, Jakarta 10430, Indonesia.
3. Department of Oral Biology, Faculty of Dentistry, Universitas Indonesia, Jakarta 10430, Indonesia.
4. Department of Prosthodontics, Faculty of Dentistry, Universitas Indonesia, Jakarta 10430, Indonesia.

### Abstract

The aim of this research is to study the correlation between the mandibular cortex of panoramic radiograph and grey scale value of alveolar bone on the periapical digital radiograph among Indonesian women aged 40 years to 75 years. A cross-sectional study was conducted by performing panoramic radiograph to assess mandible cortex index, as well as digital dental radiograph to obtain grey scale value of the alveolar bone. The intra oral periapical digital radiographs were made in the region of mandible premolar, and by utilizing density measurement tool in Digora for window software all digital images were analyzed to obtain the mean grey scale value of each region of interest (ROI). It is showed in 102 subjects with C1, C2 and C3 mandible cortex index revealed mean alveolar bone grey scale value of 141.23 ( $\pm 20.93$ ), 100.94 ( $\pm 13.67$ ), and 96.01 ( $\pm 16.83$ ) respectively. Pearson's correlation between alveolar bone density and mandible cortex index was 0.711 with  $<0.001$  significance.

Alveolar bone grey scale value obtained from digital dental radiograph has significant correlation with mandibular cortex index. The digital dental radiograph has the potential usefulness for identifying osteoporosis as on panoramic radiograph

*Clinical article (J Int Dent Med Res 2016; 9: (3), pp. 215-220)*

**Keywords:** Alveolar bone grey scale value, digital dental radiograph, mandible cortex index, panoramic radiograph.

**Received date:** 26 June 2016

**Accept date:** 25 July 2016

### Introduction

Osteoporosis is one of the systemic degenerative diseases, characterized by low bone mass and decreased of bone micro architecture which will lead to increased bone fragility and fracture susceptibility. Osteoporosis is a chronic, longstanding, complex and multifactor cause disease which often occur without any symptoms, and result in a bone fracture either spontaneously or due to mild trauma.<sup>1</sup> Osteoporosis affect the entire skeleton

including the jaw bone. Researches have shown that besides jawbone, osteoporosis also affects oral and craniofacial structures. However the influence of osteoporosis to affect oral and maxillofacial structure such as periodontal tissues, teeth, and height of residual ridge is still remains unclear, and many is still on going research.<sup>2</sup>

Nowadays the life expectancy of most population in Indonesia become higher, thus will lead to higher number of the elderly. One of researches in Indonesian population regarding prevalence of osteoporosis, conduct by Tirtarahardja et al has demonstrate the decreasing BMD values and increasing osteoporosis prevalence in Indonesians corresponding to increasing of age. As it has been stated previously that osteoporosis is systemic disease that can affect the whole body including jawbone. In this regard, this is in accordance with statement that the occurrence of

#### \*Corresponding author:

Lilies Dwi Sulistyani  
Lecturer, Department of Oral and Maxillofacial Surgery  
Faculty of Dentistry, Universitas Indonesia  
Building A Level 2  
Jalan Salemba Raya No. 4, Jakarta Pusat, Jakarta 10430,  
Indonesia  
E-mail: [liliesdwi\\_s@yahoo.co.id](mailto:liliesdwi_s@yahoo.co.id)

osteoporosis in femur, spine can also be followed by osteoporosis of jawbone.<sup>3,4</sup> It has been proved that low Bone Mineral Density (BMD) in mandible has correlated with whole skeletal bone mass and it is highly correlated with higher risk for fracture.<sup>5,6</sup> Dual Energy X-ray absorptiometry (DEXA) is considered as the most reliable means of measuring bone mineral density commonly. However, the use of DEXA is considered as ineffective and inefficient because of the costs is quite expensive and not practical.<sup>6,7</sup> In the field of dentistry, in accordance with the increase of number of elderly population, the need of dental treatment such as tooth extraction, dentures and dental implants treatment becomes increased consequently. Panoramic and dental digital radiographs are the most useful and popular diagnostic tools to be used as one of important part for those treatment.

The research which evaluates the use of panoramic radiograph for estimating changes in cortical bone mineral of the mandible based on bone mineral density derived from Dual Energy X-ray absorptiometry (DEXA) has been conducted by Klemetti E et al.<sup>8</sup> Other research conduct by Alapati S et al shown that panoramic radiograph can be used as the tool to assess skeletal changes in the mandible, as the indication of skeletal osteopenia and osteoporosis. This study established the index of the mandibular cortex which derived from panoramic radiographs that could distinguish women with normal mandibular bone or suffer from osteopenia or osteoporosis.<sup>9</sup> This invention correspond to research conduct by Taguchi A et al with the result that panoramic can be used to identify low bone mineral density which cannot be detected in post-menopausal women. In this research radiographic image of eroded edge in the inferior mandibular cortex on panoramic can be used to identify low BMD in postmenopausal women.<sup>10</sup>

Periapical digital radiography provide images with superior resolution, sharpness, requires less radiation and also giving information about bone density. This tool is important in the diagnosis and treatment planning in many dental procedure, such as the treatment of implants, periodontal diseases and systemic diseases with oral and maxillofacial manifestation such as osteoporosis.<sup>11</sup>

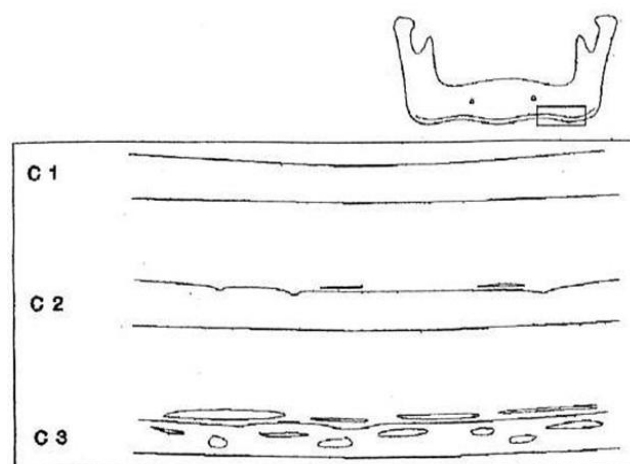
Base on fact that osteoporosis is a systemic skeletal disorder that will involve the entire

skeleton of the body and the usefulness dental radiographs to reveal the condition of maxillary or mandibular bone, it is of beneficial the possibility to explore potential usefulness for dental radiographs as a screening tool for osteoporosis. The research about trabecular pattern on dental radiographs has already been conducted that reveal the potential ability to predicts osteoporosis with sensitivity and specificity similar to age.<sup>12,13</sup>

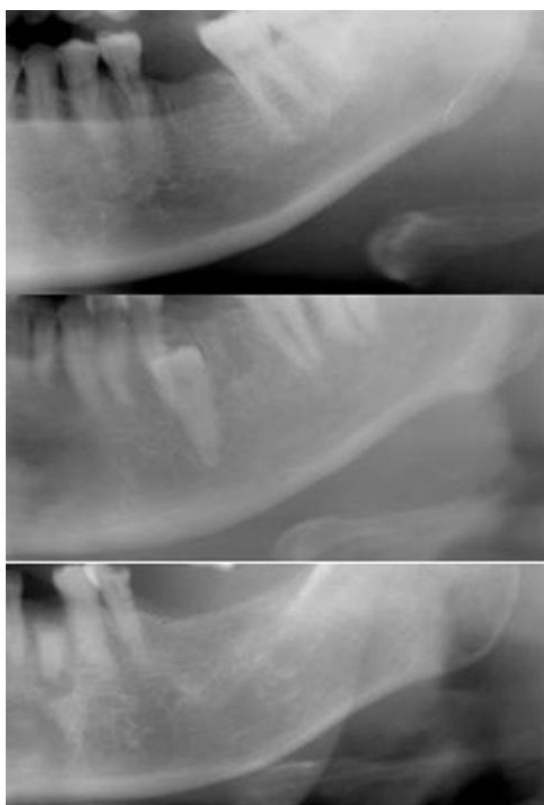
The objective of this research is to study the correlation between the mandibular cortex and grey scale value of alveolar bone based on the panoramic and periapical digital radiograph among Indonesian women aged 40 to 75 years.

### Materials and methods

This study was carried out with the subject of 102 women aged 40 years to 75 years old. The participants were the patients who came to the Dental Hospital Faculty of Dentistry Universitas Indonesia who wish to have treatment of tooth extractions. This study has already approved by the ethics committee of the Faculty of Dentistry, Universitas Indonesia and all participants have agreed to participate in this study by signing the inform consent provided.



**Figure 1.** Clasification of Mandibular Cortex Mandibular Index method by Klemetti et al. C1 has average and sharp endosteal edge on both side. C2 has the semilunar defects on the endosteal edge (lacunar resorption) or it looks like a rest form of the endosteal cortical (layer up to 3 layers) on one and both sides of the mandible C3 is the cortical layers that make up the rest of the endosteal cortex and porous was apparent.<sup>8</sup>

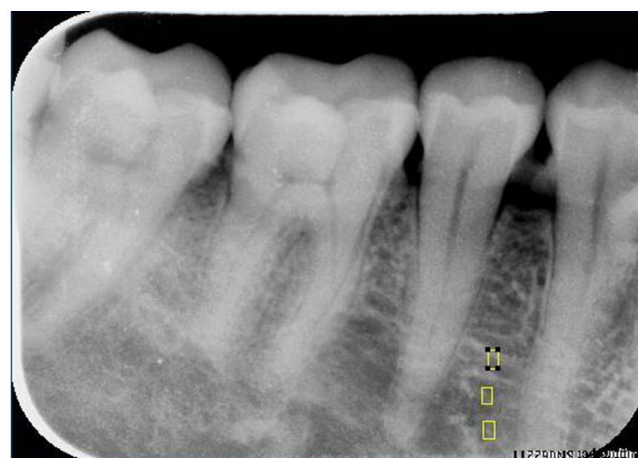

**Figure 2.** Assessment of Mandibular Cortex using Mandibular Index method by Klemetti et al.

All participant was examined using panoramic radiographs and digital periapical radiographs prior to the tooth extraction. Panoramic radiograph made with the X-Ray apparatus of Digora Cranex tome CEPH (Finland). The panoramic radiograph is examined by a radiologist blinded. Examinations of the inferior mandibular cortex were made on both sides on panoramic radiographs in distal to the mental foramen using the method established by Klemetti et al. The results were divided into three groups: C1, C2 and C3 with the following criteria. C1 has average and sharp endosteal edge on both sides, C2 has the semilunar defects on the endosteal edge (lacunar resorption) or it looks like a rest form of the endosteal cortical (layer up to 3 layers) on one and both sides of the mandible, while C3 is the cortical layers that make up the rest of the endosteal cortex and porous was apparent. (Figure 1 and Figure 2).

Intra oral periapical digital radiography examinations were conducted using Photostimulable Phosphor Plate (PSP) from Digora® system, in the region of right or left mandibular premolar. The exposure condition was at 60 kVp, 7 mA, and with the same

exposure time 0.18 second using X-Ray apparatus Bel-Ray (Belmont, Japan). The long cone was used to be adjusted with paralleling cone indicator from Hanshin®, to perform a parallel chnique. The PSP directly processed using the reader to obtain digital image. The digital radiographic images were store using software Digora for Window®. Using the computer with an 8 bit system, each small square area (a pixel) has a grey value between 0 and 255. 0 corresponds to totally black, and 255 to totally white. This numeric value is called the grey-scale value. Digital periapical radiograph were evaluated using software Digora for Window®, the value of alveolar bone density were determined using bone density measurement marked area tool in the region of interest (ROI) as appeared in Figure 3. The standardized area of ROI were determined as the several rectangular areas of 2mm<sup>2</sup>, and were selected between the apical part of the premolars on the right or left side of the lower jaw. The grey-scale values were obtained as the mean value for each ROI.



**Figure 3.** Density measurement of alveolar bone gray scale value in the region of interest. The rectangular shape shows region of interest to be measured and compared to mandibular cortex index in panoramic radiograph.

### Results

The subject were 102 women aged 40 years to 75 years with a mean age of 55.16 years. The panoramic radiograph of all subject were divided into 3 groups using mandibular index method by Klemetti et al, with result in 40 subject (39,2%) were categorized in the mandibular

cortex index C1, 29 subject (28.4%) categorized C2 and 33 subject (32.4%) C3. This result can be seen in table 1.

| Mandibular Cortex Index | N   | %     |
|-------------------------|-----|-------|
| (C1)                    | 40  | 39,2  |
| (C2)                    | 29  | 28,4  |
| (C3)                    | 33  | 32,4  |
| Total                   | 102 | 100,0 |

**Table 1.** Description of categorized subject using Mandibular Cortex Index.

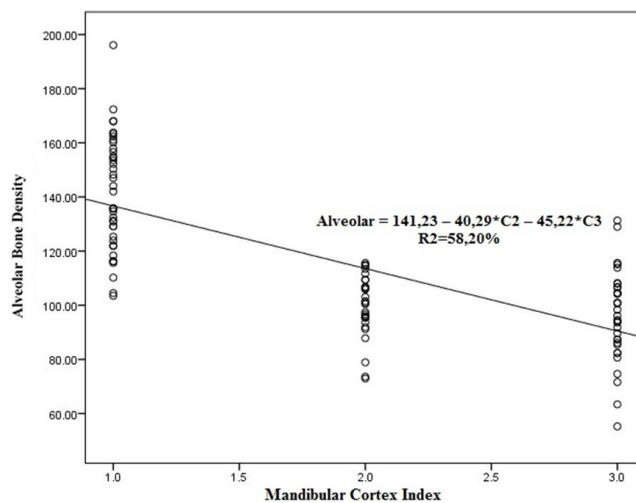
In addition to measurement of cortex of the mandible, alveolar density was also measured by means of alveolar bone grey scale value and correlated to see the relationship between the condition of the mandibular cortical density and alveolar density. The results of the measurements can be seen in table 2.

| Alveolar bone grey scale value | Categorized subject using Mandibular Cortical Index |                |                | r (p)           |
|--------------------------------|---|----------------|----------------|-----------------|
|                                | C1  | C2             | C3             |                 |
| Range                          | 103,51 - 196,08                                     | 72,94 - 140,18 | 55,24 - 131,29 | 0,711 (p<0,001) |
| Median                         | 138,92  | 100,97         | 96,16          |                 |
| Mean ± SD                      | 141,23 ± 20,93                                      | 100,94 ± 13,67 | 96,01 ± 16,83  |                 |

\*normal distribution

**Table 2.** Correlation between alveolar bone grey scale value with Mandibular Cortical Index.

Alveolar density obtained from measurement of alveolar bone grey scale value showed higher mean in the C1 mandibular cortex index than the C2 and C3 respectively. It also revealed that the decrease in mandibular cortical density was corresponding to the decrease of the mean of alveolar density. Pearson correlation showed a linear correlation between the densities of the alveolar to the mandibular cortex which is a strong linear correlation. Linear regression was performed furthermore to see both forms of linearity. Results of linear regression showed C2 alveolar bone density differ 40.29, and C3 differ 45.22 lower than C1. Mandibular cortical index can be explained by the alveolar bone density with value of 58.20%. The results of the linear regression can be seen in figure 4.



**Figure 4.** Linear Correlation between Alveolar Bone Density and Mandibular Cortex.

### Discussion

Osteoporosis is a common metabolic disease in the world that affects more than 325 million individuals. Osteoporosis is a serious public health concern, which entails significant social and economic burdens. Because the number of elderly people is the fastest growing in the world, the high rates of fractures associated with substantial morbidity is notable, and costs of patients management are increasing rapidly.<sup>14</sup>

It is suggested that BMD should be measured if an additional risk factor is present such as low weight or age 65 and over.<sup>15</sup> As the decrease in density and increase in porosity of human bones begins at about the third decade of life, the lower age limit in this study was set as the fourth decade. After menopause, deficiency in estrogen induces increases bone turnover, leading to skeletal bone loss. As the bone quality, cortical thickness increase slightly until age of 50 years and decreased significantly thereafter, parallel to change in menopausal status.<sup>7,9</sup>

Several studies about the usefulness of panoramic had been conducted with the result that performing simple visual estimation on panoramic radiograph maybe useful in identifying post menopausal woman with low BMD.<sup>6,10</sup> Study of panoramic radiograph may provide an economical and reliable diagnostic tool to rule out osteoporosis in undiagnosed patients where DEXA screening may not be available. In other studies it can be concluded that the dentist can make a referral results in the assessment of Mandibular Cortical Index using panoramic

radiographs were included in the category eroded or porous cortex to perform bone densitometry examination.<sup>16-18</sup>

In recent years the digital dental radiographs are still not widely elaborated of its usefulness in assessing alveolar bone condition mainly associated with osteoporosis. Based on some studies dentists can use ordinary dental radiographs as a rough tool to identify women at high risk for future fractures in mid-life, often many years before the first fracture occurs.<sup>19</sup> Several studies have been carried out, with the results showed a positive correlation between BMD heels with pixel intensity values in digital periapical radiograph.<sup>13</sup> Other study also demonstrated a significant correlation between BMD in the forearm with a gray level value in digitized intra-oral periapical radiograph.<sup>18</sup>

In this study, it is found that alveolar bone grey scale value in intra oral digital periapical radiograph as shown in table 2 is in consistent with the result of other studies which reveals the cut-off of the pixel intensity value also reflects bone density. The individuals with value below 100 was considered to be pathologic and in need further test. The value greater than or equal to 100 was normal.<sup>13</sup> Other study in Indonesia about bone quality also showed concordant result. The study used the score of 3 as normal bone density, and result in the minimum and maximum limits of alveolar bone grey scale value between 106.21 and 131.96.<sup>20</sup>

The result of this study revealed changes in the mandibular alveolar bone density in periapical radiograph has a correlation with mandibular cortex index in panoramic. The decrease of the overall alveolar bone density in intra oral digital periapical radiograph may be useful to identify osteoporosis in need of further evaluation.

The limitation of this study is the limited number of the subject included in this study, further studies with higher number of subjects will improve significance of the correlation.

## Conclusions

The results of this study indicate that there is a statistically significant correlation between the mandibular cortical index with alveolar bone density. It can also be seen from the linear regression which can concluded that mandibular cortical index can be explained by the

alveolar bone density with the value of 58.20%. Therefore it can be stated that digital dental radiograph has potential usefulness for detecting osteoporosis as on panoramic radiographs. This research is still necessary to be continued using higher quality diagnostic tools such as DEXA BMD heel, so that cut off can be performed on gray scale value based on the results of diagnosis using those device in order to obtain the specificity and sensitivity value.

All procedures followed were in accordance with the ethical standards of the responsible committee on human experimentation (institutional and national) and with the Helsinki Declaration of 1975, as revised in 2008<sup>5</sup>. Informed Consent was obtained from all patients for being included in the study.

## Acknowledgements

The publication of this manuscript is supported by the Directorate of Research and Community Engagement of the Universitas Indonesia.

## Declaration of Interest

The authors report no conflict of interest.

## References

1. Czerwiński E, Badurski JE, Marciniowska-Suchowierska E, Osieleń J. Current understanding of osteoporosis according to the position of the World Health Organization (WHO) and International Osteoporosis Foundation. *Ortopedia, Tarumatologia, Rehabilitacja*. 2007; 9:337-3561.
2. Rosella D, Papi P, Giardino R, Cicalini E, Piccoli L, Pompa G. Medication-related osteonecrosis of the jaw: Clinical and practical guidelines. *J Int Soc Prev Community Dent*. 2016;6:97-104.
3. Tirtarahardja G, Setyohadi B, Zhou WQ. Bone Mineral Density Reference Values for Indonesian Men and Women. *ASBMR Meeting 2006*. [internet]. Available from: [https://www.iofbonehealth.org/sites/default/files/media/PDFs/Regional%20Audits/2013-Asia\\_Pacific\\_Audit-Indonesia\\_0\\_0.pdf](https://www.iofbonehealth.org/sites/default/files/media/PDFs/Regional%20Audits/2013-Asia_Pacific_Audit-Indonesia_0_0.pdf)
4. Taguchi A. Triage screening for osteoporosis in dental clinics using panoramic radiographs. *Oral Dis*. 2010;16:316-27.
5. Martínez-Maestre MÁ, Corcuera Flores JR, Machuca G, González-Cejudo C, Torrejón R, Castelo-Branco C. Panoramic radiomorphometry and vertebral fractures in Spanish postmenopausal women. *Maturitas*. 2013;76:364-9.
6. Ezoddini Ardakani F, Owlia MB, Hesami S, Hosseini P. Digital panoramic radiography as a useful tool for detection of bone loss: a comparative study. *Acta Med Iran*. 2013;51:94-100.
7. Singh SV, Aggarwal H, Gupta V, Kumar P, Tripathi A. Measurements in Mandibular Pantomographic X-rays and Relation to Skeletal Mineral Densitometric Values. *J Clin Densitom*. 2016;19:255-61.

8. Klemetti E, Kolmakov S, Kröger H. Pantomography in assessment of the osteoporosis risk group. *Scand J Dent Res.* 1994;102:68-72.
9. Alapati S, Reddy RS, Tatapudi R, Kotha R, Bodu NK, Chennouju S. Identifying risk groups for osteoporosis by digital panoramic radiography. *Contemp Clin Dent.* 2015 ;6:S253-7.
10. Taguchi A, Ohtsuka M, Nakamoto T, Naito K, Tsuda M, Kudo Y, Motoyama E, Suei Y, Tanimoto K. Identification of post-menopausal women at risk of osteoporosis by trained general dental practitioners using panoramic radiographs. *Dentomaxillofac Radiol.* 2007;36:149-54.
11. Priaminiarti M, Utomo B, Susworo R, Iskandar HB. Converting conventional radiographic examination data of trabecular bone pattern values into density measurement values using intraoral digital images. *Oral Radiol.* 2009;25:129-4.
12. Verheij JG, Geraets WG, van der Stelt PF, Horner K, Lindh C, Nicopoulou-Karayianni K, Jacobs R, Marjanovic EJ, Adams JE, Devlin H. Prediction of osteoporosis with dental radiographs and age. *Dentomaxillofac Radiol.* 2009;38:431-7.
13. Hedström L, Baigi A, Bergh H. The relation between bone mineral density in the heel and pixel intensity in the mandibular jaw bone among elderly women. *Dentomaxillofac Radiol.* 2010;39: 409–13.
14. Ferreira Leite A, de Souza Figueiredo PT, Ramos Barra F, Santos de Melo N, de Paula AP. Relationships between mandibular cortical indexes, bone mineral density, and osteoporotic fractures in Brazilian men over 60 years old. *Oral Surg Oral Med Oral Pathol Oral Radiol Endod.* 2011;112:648-56.
15. Geraets WG, Verheij JG, van der Stelt PF, Horner K, Lindh C, Nicopoulou-Karayianni K, Jacobs R, Harrison EJ, Adams JE, Devlin H. Prediction of bone mineral density with dental radiographs. *Bone.* 2007;40:1217-21.
16. Taguchi A, Tsuda M, Ohtsuka M, Kodama I, Sanada M, Nakamoto T, et al. Use of dental panoramic radiographs in identifying younger postmenopausal women with osteoporosis. *Osteoporos Int.* 2006;17:387-94.
17. Jonasson G, Sundh V, Hakeberg M, Hassani-Nejad A, Lissner L, Ahlqwist M. Mandibular bone changes in 24 years and skeletal fracture prediction. *Clin Oral Investig.* 2013;17:565-72.
18. Jonasson G, Jonasson L, Kiliaridis S. Skeletal bone mineral density in relation to thickness, bone mass, and structure of the mandibular alveolar process in dentate men and women. *Eur J Oral Sci.* 2007;115:117-23.
19. Jonasson G, Sundh V, Ahlqwist M, Hakeberg M, Björkelund C, Lissner L. A prospective study of mandibular trabecular bone to predict fracture incidence in women: a low-cost screening tool in the dental clinic. *Bone.* 2011;49:873-9.
20. Priaminiarti M. Prediction of Radiometric Parameter of Jawbone Through Radiographic Examination : Efforts to Improve the Quality of Dental Implant Diagnostic [dissertation]. Jakarta: Universitas Indonesia;2008.