

## Histopathological Findings of Oral and Maxillofacial Biopsies from a Sample of Yemeni Patients

Mohammed Ali Al-Wesabi<sup>1\*</sup>, Salsbeel Mohammed Al –Matari<sup>2</sup>, Khaled Ahmed Al- Jawfi<sup>3</sup>

1. Department of Preventive and Biomedical Sciences, Faculty of Dentistry, University of Science and Technology, Sana'a, Yemen.
2. Faculty of Dentistry, University of Science and Technology, Sana'a, Yemen.
3. Faculty of Dentistry, University of Science and Technology, Sana'a, Yemen.

### Abstract

Epidemiologic studies of Oral and Maxillofacial lesions (OMLs) are rare compared with that related to caries and periodontal diseases, they are fundamental to promote early diagnosis and provide appropriate preventive oral health programs. This study was to investigate the prevalence and types of histologically confirmed OMLs in Sana'a, the capital of Yemen.

Documented records of all patients with OMLs were retrieved from the main histopathology laboratories that provides biopsy analysis in Sana'a city during the period from 2013 to 2018. This multicenter retrospective study was conducted on 1376 oral and maxillofacial biopsied lesions.

Regarding malignant lesions; the most prevalent lesions among males and females was Oral Squamous Cell Carcinoma (OSCC); (226; 38.8.0% and 214; 30.9%; respectively). Most of the OSCC cases (43.8%) were older than 40 years old, at this age group the second most prevalent lesions were Non-Hodgkin's lymphoma and Basal cell carcinoma (1.4% and 1.2%; respectively). The results of the regression analysis shows that the site of the lesion (OR; 0.6, CI; 0.51-0.81; P= 0.00) and age of the patient (OR; 4.17, CI; 5.22-5.41; P=0.00) were the independent factors of malignancy of oral lesions.

The present study showed high prevalence of malignant and premalignant oral mucosal lesions. The data from this study highlight the need for dental public health intervention programs for early detection of oral cancer among Yemeni population by dental practitioners. As well as the importance of education of the general population in regards to risk factors of OMLs.

**Clinical article (J Int Dent Med Res 2021; 14(1): 235-241)**

**Keywords:** Biopsy, Oral mucosa, Squamous cell carcinoma of head and neck, Histopathology, Yemen.

**Received date:** 11 October 2020

**Accept date:** 09 December 2020

### Introduction

Oral and maxillofacial region show predilection of diverse types of alterations and lesions. Although most of oral and maxillofacial lesions (OMLs) are benign and require no specific treatment, some may present with significant pathology, of specific importance are malignant and oral potentially malignant disorders (OPMDs) which may demonstrate oral epithelial dysplasia with expanding degrees of severity, tissue atrophy and/or hyperplasia.<sup>1</sup> Considering the high rate of malignant transformation of OPMDs, attention ought to be

paid to early diagnosis.<sup>2</sup> Histopathologic investigation of biopsied lesions is the best method to reach the definitive diagnosis of OMLs.<sup>3</sup> Moreover, studies dependent on histopathologic conclusion are more reliable.<sup>4</sup>

The description of various oral and maxillofacial pathologies has prompted to significant differences in the nomenclature and classification of these lesions.<sup>5</sup> Epidemiologic studies of histologically confirmed OMLs are rare compared with the studies of other oral diseases such as caries and periodontal diseases.<sup>6, 7</sup> Surveying the distribution of OMLs in a specific population is essential to understand its prevalence and characteristics, they are also fundamental to promote early diagnosis and provide appropriate health programs, as suggested by the World Health Organization (WHO).<sup>8</sup>

In Yemen, epidemiological data directed on oral lesions are limited, and the vast majority

#### \*Corresponding author:

Mohammed Ali Al-Wesabi  
Department of Oral Medicine and Periodontology, Faculty of  
Dentistry, University of Science and Technology, Sana'a, Yemen.  
E-Mail: malwossabi@gmail.com

of these data were about the relationship between Qat chewing and white lesions. Therefore, this study was to investigate the prevalence and types of histologically confirmed OMLs in Sana'a, Yemen, and to assess their association with age and gender.

### Materials and methods

Documented records of all patients with OMLs were retrieved from the main histopathology laboratories that provides biopsy analysis in Sana'a city during the period 2013 to 2018. This multicenter retrospective study was conducted on 1376 oral and maxillofacial biopsied lesions. All reports that were inconclusive and required immunohistochemistry for definitive diagnosis as well as those that were unsigned or without a final accommodation were excluded.

The clinical and pathological data were extracted from the histopathology reports, which included age, gender, and nature of specimen, site of lesion and histopathological diagnosis. Data were coded and entered to computer as reported in the biopsy reports with some standardization using current terminologies. Lesions were grouped into either benign neoplastic lesions or malignant neoplastic lesions and further categorized based on the histopathological diagnosis into 7 broad diagnostic groups as follow: Benign neoplastic lesions, Malignant neoplastic lesions, Developmental lesions, Inflammatory lesions, Reactive lesions, Cystic lesions, Premalignant lesions, Autoimmune lesions and Miscellaneous. The association of the clinical and histopathological findings with the gender and age categories were analyzed by Chi-square test, Binary logistic regression analysis was performed to find the determinants of malignancy of lesions. Significance level was set at <0.05, the data were analyzed using SPSS software version 21 for windows (SPSS Inc., Chicago, IL, USA).

### Results

The total number of the analyzed biopsy reports were 1376; out of them 684 (49.7%) male and 692 (50.3%) female. Mean age of the study sample was 43.6 years and their age was ranged from one to 100 years old. Regarding malignant lesions; the most prevalent lesions among male

and female cases was OSCC (226, 38.8.0% and 214, 30.9%; respectively), followed by Non-Hodgkin's lymphoma, which were 8 cases (1.2%) for male and 7 cases (1.0%) for females. Adenoid cystic carcinoma and basal cell carcinoma were higher among female compared to male counterparts with prevalence of (1.2%) and (0.4%) and frequency of 8 cases for both lesions among female compared to 3 cases for both lesions too among males. Most of the cases (43.8%) diagnosed as a OSCC were older than 40 years old, at this age group the second most prevalent lesions were Non-Hodgkin's lymphoma and Basal cell carcinoma (1.4% and 1.2%; respectively). Table 1 shows the distribution and types of malignant neoplastic lesions among the study sample according to their age group and gender.

Diagnosis	Sex of patient				Age group			
	Male (n=684)		Female (n=692)		40 years or less(n=532)		> 40 years old(n=844)	
	F	%	F	%	F	%	F	%
Adenocarcinoma	0	0.0	6	0.9	0	0.0	6	0.7
Adenoid cystic carcinoma	3	0.4	8	1.2	6	1.1	5	0.6
Basal cell adenocarcinoma	2	0.3	0	0.0	2	0.4	0	0.0
Basal cell carcinoma	3	0.4	8	1.2	1	0.2	10	1.2
Hodgkin's lymphoma	1	0.1	0	0.0	0	0.0	1	0.1
Liposarcoma	2	0.3	0	0.0	0	0.0	2	0.2
Juvenile hemangioma	2	0.3	0	0.0	2	0.4	0	0.0
Juvenile ossifying fibroma	2	0.3	0	0.0	2	0.4	0	0.0
Kaposi sarcoma	0	0.0	1	0.1	1	0.2	0	0.0
Mucoepidermoid carcinoma	0	0.0	1	0.1	1	0.2	0	0.0
Non-Hodgkin's lymphoma	8	1.2	7	1.0	3	0.6	12	1.4
Osteosarcoma	0	0.0	1	0.1	0	0.0	1	0.1
Rhabdomyosarcoma	0	0.0	1	0.1	1	0.2	0	0.0
SCC	226	33.0	214	30.9	70	13.2	370	43.8
Undifferentiated pleomorphic sarcoma	5	0.7	6	0.9	8	1.5	3	0.4

**Table 1.** Malignant neoplastic lesions of the study samples according to age and gender.

Benign neoplastic lesions according to the age group and gender of the patient are showed in table 2, in which fibroma (7.65%), pyogenic fibroma (5.7%), capillary hemangioma (3.7%), squamous papilloma (3.4%) and lipoma (2.9%), were the most common lesions among males. As OSCC were the most prevalent malignant lesions; further analysis were performed regarding tumor grade, tumor sub type, and recurrence status of the lesions. "Well differentiated" tumors (203; 54.9%), "invasive SCC" subtype (132; 35.7%), and "none" recurrence (283; 76.5%) were the most of their categories among patients aged more than 40 years old, although there were non-significant association, (Table 3).

	Sex of patient				Age group			
	Male (n=684)		Female (n=692)		40 years or less(n=532)		> 40 years old(n=844)	
	F	%	F	%	F	%	F	%
Ameloblastic fibroma	1	0.1	1	0.1	1	0.2	1	0.1
Ameloblastoma	4	0.6	2	0.3	2	0.4	4	0.5
Angiolipoma	2	0.3	4	0.6	3	0.6	3	0.4
Benign dermal melanocytic nevus	0	0.0	3	0.4	3	0.6	0	0.0
Capillary hemangioma	25	3.7	22	3.2	31	5.8	16	1.9
Cartilaginous choristoma	0	0.0	2	0.3	0	0.0	2	0.2
Caseating granuloma c/w tuberculosis	1	0.1	6	0.9	6	1.1	1	0.1
Cavernous hemangioma	2	0.3	14	2.0	12	2.3	4	0.5
Cemento ossifying fibroma	0	0.0	1	0.1	1	0.2	0	0.0
Fibrolipoma	3	0.4	3	0.4	0	0.0	6	0.7
Fibroma	52	7.6	46	6.6	49	9.2	49	5.8
Giant cell granuloma	9	1.3	9	1.3	10	1.9	8	0.9
Keratoacanthoma	3	0.4	1	0.1	0	0.0	4	0.5
Lipoma	20	2.9	26	3.8	18	3.4	28	3.3
Lymphangioma	7	1.0	4	0.6	3	0.6	8	0.9
Melanocytic nevi	1	0.1	1	0.1	0	0.0	2	0.2
Mesenchymal hamartoma	2	0.3	0	0.0	2	0.4	0	0.0
Neurofibroma	0	0.0	3	0.4	2	0.4	1	0.1
Ossifying fibroma	3	0.4	7	1.0	3	0.6	7	0.8
Osteochondroma	1	0.1	0	0.0	1	0.2	0	0.0
Periapical granuloma/abscess	0	0.0	1	0.1	1	0.2	0	0.0
Plasma cell granuloma	12	1.8	9	1.3	14	2.6	7	0.8
Pleomorphic adenoma	1	0.1	5	0.7	4	0.8	2	0.2
Pyogenic granuloma	39	5.7	34	4.9	46	8.6	27	3.2
Schwannoma	3	0.4	2	0.3	5	0.9	0	0.0
Squamous papilloma	23	3.4	21	3.0	22	4.1	22	2.6
Traumatic neuroma	0	0.0	1	0.1	0	0.0	1	0.1

**Table 2.** Benign neoplastic lesions of the study samples according to age and gender.

		Age of the patient				P-value
		40 years or less		More than 40 years old		
		F	%	F	%	
Tumor grade	Poor differentiated	1	1.4	17	4.6	.099
	Moderate differentiated	24	34.3	114	30.8	
	Well differentiated	38	54.3	203	54.9	
	Undifferentiated	2	2.9	1	0.3	
	NM	5	7.1	35	9.5	
Tumor subtype	SCC	16	22.9	87	23.5	.637
	Non keratinizing SCC	2	2.9	2	0.5	
	Keratinizing SCC	5	7.1	33	8.9	
	Invasive SCC	24	34.3	132	35.7	
	Invasive keratinizing SCC	14	20.0	79	21.4	
	Metastatic SCC	4	5.7	15	4.1	
	Verrucous SCC	5	7.1	22	5.9	
Recurrence	No history of recurrence has been mentioned	59	84.3	283	76.5	.202
	Recurrent from the same site	1	1.4	2	0.5	
	Recurrent from other oral site	10	14.3	85	23.0	

**Table 3.** Association between SCC; grade, subtype, and recurrence status with the age of the patients.

Distribution of the lesions as categorized into relevant groups as presented in table 4; malignant neoplastic lesions were the most common lesions among male (31.3%) and female (33.7%) was the followed by benign neoplastic lesions. Whereas the least prevalence was of the developmental and miscellaneous

lesions, (Table 4).

		Sex of patient			
		Male		Female	
		F	%	F	%
Oral and maxillofacial classification	Benign neoplastic lesions	214	31.3	233	33.7
	Malignant neoplastic lesions	254	37.1	253	36.6
	Developmental lesions	1	0.1	6	0.9
	Inflammatory lesions	107	15.6	92	13.3
	Reactive lesions	10	1.5	19	2.7
	Cystic lesions	40	5.8	42	6.1
	Premalignant lesions	49	7.2	41	5.9
	Autoimmune lesions	8	1.2	5	0.7
	Miscellaneous lesion	1	0.1	1	0.1

**Table 4.** Classification of the studied biopsies and their distribution according to gender.

The results of the regression analysis shows that the site of the lesion (OR; 0.6, CI; 0.51-0.81; P= 0.00) and age of the patient (OR; 4.17, CI; 5.22-5.41; P=0.00) were the independent factors of malignancy of oral lesions, (Table 5).

Variable	Category	Classification		Adjusted Odds ratio (Confidence intervals)	P- value
		Benign (n=869)	Malignant (n=507)		
Gender	Male	430	254	.919 (0.729- 1.159)	.475
	%	49.5	50.1		
	Female	439	253		
	%	50.5	49.9		
Site	Tongue	296	233	.646 (0.510- .817)	0.000
	%	34.1	46.0		
	Other sites	573	274		
	%	65.9	54.0		
Age	40 yrs. or less	435	97	4.178 (3.222- 5.418)	0.000
	%	50.1	19.1		
	More than 40 years old	434	410		
	%	49.9	80.9		

**Table 5.** Binary logistic regression analysis of the factors associated with the malignancy of the lesions.

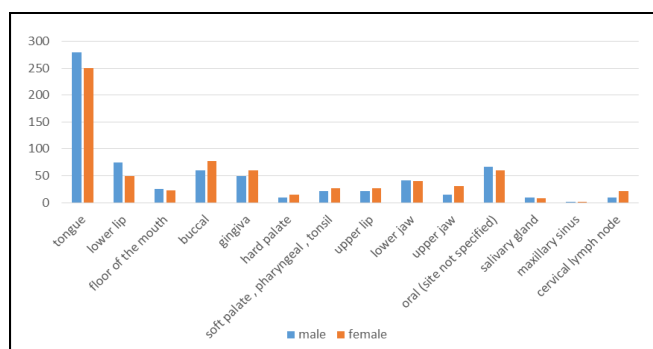
		Classification		P - value		
		Benign	Malignant			
Site of the lesion of in the tongue	Tip	21	65.6%	11	34.4%	0.000
	Anterior	4	30.8%	9	69.2%	
	Lateral	59	39.1%	92	60.9%	
	Base	12	66.7%	6	33.3%	
	Ventral	31	79.5%	8	20.5%	
	Site not specified	262	65.2%	140	34.8%	
	Total		389	59.4%	266	

**Table 6.** Description and association between the site of the tongue lesions and their malignancy.

The site of the lesion in the tongue was significantly associated with their malignancy. As

shown in table 6, malignant tongue lesions were more prevalent at the anterior and lateral tongue, (69.2% and 60.9%; respectively). The association between site of tongue lesion and malignancy was significant, (P=0.000). Figure 1 shows the distribution of the lesions according to the site of biopsy as reported in the histopathological reports.

Figure 1 present the distribution of the lesions according to the site of biopsy as reported in the histopathological reports.



**Figure 1.** Distribution of the study sample according to the site of biopsy.

## Discussion

Tissue biopsy is one of the diagnostic methods, which routinely performed in the medical laboratories, it considered as the gold standard for the definitive diagnosis of oral, and perioral lesions. By the histopathological reports we can assess the prevalence and types of OMLs in a specific populations and determine the rate of utilization of biopsy diagnostic procedures and their challenges.<sup>9</sup>

Performing incisional and excisional biopsies is one of the responsibilities of general practitioners and specialists whenever indicated. The aim of the present study was to provide an important baseline data on the profile of OMLs among Yemenis, which will help the healthcare authorities in health planning, providing dental services, risk management, and prevention.

This study included 1367 biopsy reports from referral laboratories in the capital of the country; this increases the representativeness of the study sample and generalizability of the results.

The mean age of the patients with OMLs was 43.6 years, this in accordance with that of other study among neighbor Saudi population.<sup>5</sup> Most of the reports were of patients aged

between 4<sup>th</sup> and 6<sup>th</sup> decade, this finding is in consistent with previous surveys.<sup>7,10</sup> This age group is labile to be affected by other health problems leading them to seek the health care while which the oral lesions might accidentally found by health care providers.

The rate of malignant neoplastic lesions in this study was much higher (36.8%) than previously reported prevalence among other populations that represented 5.4%, 6.5%, 1.9%, 2.4% and 5.8% respectively.<sup>7,11-13</sup> Surprisingly, studies from south western region of Saudi Arabia reported a higher incidence of malignant lesions (38.8%) and smokeless tobacco specifically shamma was held accountable for increased incidence of malignant lesions.<sup>5,14</sup> This higher prevalence of oral cancers might be due to the commonly practiced habits among Yemeni population such as Qat chewing, smoking, and Shamma using,<sup>15</sup> which can contribute to oral cancers, and also could explains the relatively equal reported prevalence of malignant lesions among the presents study sample and that of Saudi study.

When compared to premalignant lesions, malignant neoplastic lesions were much higher (6.5% and 36.8%; respectively). This is an agreement with other authors,<sup>5,7,16</sup> and this suggests failure of early detection of suspicious oral lesions by oral health care providers, delay of case referral from general or specialized dental practitioners to biopsy the lesions or patients being unaware of oral malignant lesions and not seeking treatment in absence of the pain.

OSCC was the most predominant malignant lesion (86.7%), this finding is nearly similar to that of the study among neighboring Saudi population, which reported prevalence of 93.1%.<sup>5</sup> Other studies in Arab region reported prevalence within the same range such as Jordon (84%),<sup>17</sup> and UAE (77%).<sup>18</sup> OSSC also more prevalent among older age group of present study sample, this is in the line with other previous studies.<sup>19, 20</sup> Higher incidence of OSCC in the present study might be due to that most of the patients came to the doctors at late stage of painless oral lesions when most of the premalignant lesions has undergone malignancy transformation, furthermore common bad habits mentioned before play an important role, although studies from other populations reported much lower incidence of OSCC; Spain; 1.4%,<sup>21</sup> Brazil; 2.5%,<sup>22</sup> and Nigeria; 10.8%.<sup>23</sup>



Male to female ratio of OSCC in the present study 1:1.5 this agreed that of previous study<sup>5</sup> which reported a ratio of 1:1.9. The ratio of benign to malignant lesions in this study was relatively equal 0.8: 1, this finding is greatly differ from that of other Saudi study which reported a ratio of 1:4.5, and British study that reported a value of 1: 5. This might be explained by the difference in the level of awareness among the both genders in the different countries as well as the differences in the health care facilities and utilization of these services by the population.

Cystic lesions were the fifth most common oral and maxillofacial lesions in this study. In addition, lesions related to immune-mediated diseases were observed in 13 specimens (1.9%) and more common in male patients (1.2%). These results are varied from that a recent study which reported that cystic lesions were the second most common lesions with more predilection in female patients.<sup>7</sup> This might be owing to the different populations and consequently different social sociodemographic characteristics.

From benign neoplastic lesions, fibroma was the most prevalent lesion in the present study (7.1%), this finding is in concordant with other studies.<sup>7,24</sup> However, another study reported al lower percentage among their population 0.1%.<sup>25</sup> Fibromas are mostly non-painful lesions that caused by many etiologies, and since it is an exophytic lesions that commonly cause discomfort in the oral cavity for which the patients seeks the treatment.

This study shows that squamous papilloma represented 3.2% of OMLs; this is higher than that of previous studies.<sup>11,26</sup> Moreover, pyogenic granuloma was the second most common benign neoplastic lesions (5.3%) with higher prevalence among the younger age group of 40 years or less. This is in agreement with other studies.<sup>27,28</sup> Nevertheless, the relatively high prevalence of pyogenic granuloma suggests that difficulty in maintaining oral hygiene in children and adolescents is the main etiological factor involved in the development of pyogenic granuloma.

A recent study was performed among a sample of 409 Yemeni patients in Sana'a city; in that study the authors found premalignant lesions were not common in their study,<sup>29</sup> Whereas in the present study theses lesions represented the fourth most common of oral and maxillofacial

lesions accounting for 90 cases (6.5%). This disagreement of studies in the same population is questionable and it might be due to differences in data collection methods and sampling technique. Moreover, the previous study sample was from the dental polyclinics of faculty of dentistry to which the patients came seeking specific dental treatment for usually milder compliances.

In the present study, the tongue was the most affected site of oral neoplastic lesions (38.4%). A similar results had been reported in Yemen,<sup>15,30</sup> and most of the developed and developing countries.<sup>18,31,32</sup> So it is considered as one of the high risk area for development of oral neoplastic lesions. This also agreed what reported in the main textbooks of oral medicine.<sup>33, 34</sup>

The results of the present study shows that most of OSCC were diagnosed at advanced stages. The same finding was reported in an earlier study in Yemen,<sup>30</sup> this finding might be related to lower oral health knowledge and behavior among Yemeni patients. On the other hand, high proportion of OSCC cases in the developed countries were diagnosed at early stages.<sup>35,36</sup>

Tumor staging and histopathological grading systems are good predictors of prognosis and survival. OSCC in Yemeni young patients might be a different sort of cancer with worse prognosis as tumor staging and histopathological grading are slightly worse compared to OSCC in Yemeni old patients, this finding supports that of Halboub's study.<sup>30</sup> Contrarily, previous studies reported that there are no specific clinical or histopathological features of OSCC in young adults.<sup>35,37</sup>

Although the increased number of dental faculties and graduated dentists, there is a limited access and utilization of oral health services in Yemen, particularly in rural areas. Clearly, governorates with well-facilitated healthcare centers, acceptable socioeconomic status, highly educated community increases the patients' access to health services.<sup>38</sup> These aspects apparently generate inequalities that modify the oral health profiles of rural populations. In addition, general medical and dental practitioners need better training in the diagnosis of oral conditions. The lack of skills in oral mucosal lesions detection and oral diagnostic process probably contributes to the

underestimation of lesions prevalence. The data from this study highlight the importance of education in oral health promotion for health professionals and the general population. These activities should be included in oral premalignant and malignant lesions screening campaigns to improve their effectiveness.

### Conclusions

The present study showed high prevalence of malignant and premalignant oral mucosal lesions. The data from this study highlight the need for dental public health intervention programs for early detection of oral cancer among Yemeni population by dental practitioners. As well as the importance of education of the general population in regards to risk factors of OMLs.

#### Abbreviations:

OSCC Squamous cell carcinoma  
OMLs Oral and Maxillofacial lesions  
OPMDs Oral Potentially Malignant Disorders

### Acknowledgements

The authors thanks all the laboratories from which the histopathology reports were gathered (National Center of Public Health Laboratories, Al Ma'amon medical Labs, UST Hospital, ILAB Labs, Al -Aualqi Medical Labs, Modern International Labs, and NEWLAB Labs) Thanks also for Dr. Wael Al- Absi; Pathologist and Dr. Zead; Head of pathology dept. in the National Center of Public Health Laboratories, for their collaboration.

#### Ethics approval and consent to participate

This cross-sectional study was performed in accordance with the Declaration of Helsinki, ethical approval was gained from the Ethical Committee of Faculty of Medicine, University of Science and Technology, Yemen, (Approval no. EAC/UST173). As the data were retrospectively gained; patients consent is an applicable, permission from each source of data, which were mostly medical labs, was gained from each, with the condition that the data will be anonymously manipulated for the patient and for the data source too.

### Declaration of Interest

The authors report no conflict of interest.

### References

1. Feng J, Zhou Z, Shen X, et al. Prevalence and distribution of oral mucosal lesions: a cross-sectional study in Shanghai, China. *Journal of Oral Pathology & Medicine*. 2015;44(7):490-494.
2. Tiwari L, Kujan O, Farah CS. Optical fluorescence imaging in oral cancer and potentially malignant disorders: A systematic review. *Oral diseases*. 2020;26(3):491-510.
3. de Vasconcelos Carvalho M, Iglesias DPP, do Nascimento GJF, et al. Epidemiological study of 534 biopsies of oral mucosal lesions in elderly Brazilian patients. *Gerodontology*. 2011;28(2):111-115.
4. Adeoye J, Thomson P, Choi SW. Prognostic significance of multi-positive invasive histopathology in oral cancer. *Journal of Oral Pathology & Medicine*. 2020;49(10):1004-1010.
5. Saleh SM, Idris AM, Vani NV, et al. Retrospective analysis of biopsied oral and maxillofacial lesions in south-western Saudi Arabia. *Saudi medical journal*. 2017;38(4):405.
6. Al-Mobeeriek A, AlDosari AM. Prevalence of oral lesions among Saudi dental patients. *Annals of Saudi medicine*. 2009;29(5):365-368.
7. Alhindi NA, Sindi AM, Binmadi NO, et al. A retrospective study of oral and maxillofacial pathology lesions diagnosed at the Faculty of Dentistry, King Abdulaziz University. *Clinical, cosmetic and investigational dentistry*. 2019;11:45.
8. Petersen PE. Oral cancer prevention and control—the approach of the World Health Organization. *Oral oncology*. 2009;45(4-5):454-460.
9. Akinyamoju AO, Adeyemi BF, Adisa AO, et al. Audit of oral histopathology service at a Nigerian tertiary institution over a 24-year period. *Ethiopian journal of health sciences*. 2017;27(4):383-392.
10. Saravani S, Moudi M, Kadeh H, et al. Epidemiological Study of Oral and Maxillofacial Biopsies from Geriatric Patients in Zahedan, Iran (1996-2015). *Journal of Dental Materials and Techniques*. 2016;5(4):202-207.
11. Jones A, Franklin C. An analysis of oral and maxillofacial pathology found in adults over a 30-year period. *Journal of oral pathology & medicine*. 2006;35(7):392-401.
12. Ali M, Sundaram D. Biopsied oral soft tissue lesions in Kuwait: a six-year retrospective analysis. *Medical Principles and Practice*. 2012;21(6):569-575.
13. Mendez M, Carrard VC, Haas AN, et al. A 10-year study of specimens submitted to oral pathology laboratory analysis: lesion occurrence and demographic features. *Brazilian oral research*. 2012;26(3):235-241.
14. Vani NV, Idris AM, Saleh SM, et al. Retrospective analysis of benign orofacial tumors at a tertiary referral center in Saudi Arabia. *Journal of investigative and clinical dentistry*. 2017;8(4):e12254.
15. Sawair FA, Al-Mutwakel A, Al-Eryani K, et al. High relative frequency of oral squamous cell carcinoma in Yemen: qat and tobacco chewing as its aetiological background. *International journal of environmental health research*. 2007;17(3):185-195.
16. ALANAZI YM, ALRWUILI MR, Latif K, et al. A 5-YEARS RETROSPECTIVE STUDY OF ORAL PATHOLOGICAL LESIONS IN 425 SAUDI PATIENTS. *Pakistan Oral & Dental Journal*. 2016;36(1).
17. Rawashdeh M, Matalaka I. Malignant oral tumors in Jordanians, 1991–2001. A descriptive epidemiological study. *International journal of oral and maxillofacial surgery*. 2004;33(2):183-188.
18. Anis R, Gaballah K. Oral cancer in the UAE: a multicenter, retrospective study. *Libyan Journal of Medicine*. 2013;8(1):21782.

19. Singh S, Singh J, Chandra S, et al. Prevalence of oral cancer and oral epithelial dysplasia among North Indian population: A retrospective institutional study. *Journal of Oral and Maxillofacial Pathology: JOMFP*. 2020;24(1):87.
20. Leite AA, Leonel ACLdS, Castro JFLd, et al. Oral squamous cell carcinoma: a clinicopathological study on 194 cases in northeastern Brazil. A cross-sectional retrospective study. *Sao Paulo Medical Journal*. 2018;136(2):165-169.
21. Fierro-Garibay C, Almendros-Marqués N, Berini-Aytés L, et al. Prevalence of biopsied oral lesions in a Department of Oral Surgery. *J Clin Exp Dent*. 2011;3(2):e73-77.
22. Marocchio LS, Lima J, Sperandio FF, et al. Oral squamous cell carcinoma: an analysis of 1,564 cases showing advances in early detection. *Journal of oral science*. 2010;52(2):267-273.
23. Ajayi O, Adeyemo W, Ladeinde A, et al. Primary malignant neoplasms of orofacial origin: a retrospective review of 256 cases in a Nigerian tertiary hospital. *International journal of oral and maxillofacial surgery*. 2007;36(5):403-408.
24. Rivera C, Droguett D, Arenas-Márquez M-J. Oral mucosal lesions in a Chilean elderly population: A retrospective study with a systematic review from thirteen countries. *Journal of clinical and experimental dentistry*. 2017;9(2):e276.
25. Kumar S, Narayanan VS, Ananda S, et al. Prevalence and risk indicators of oral mucosal lesions in adult population visiting primary health centers and community health centers in Kodagu district. *Journal of Family Medicine and Primary Care*. 2019;8(7):2337.
26. Sharma BP, Baral R. Oro-dental biopsies in females: a 23 year study. *Nepal Journal of Obstetrics and Gynaecology*. 2016;11(1):24-25.
27. Martins-Filho PRS, de Santana Santos T, Piva MR, et al. A multicenter retrospective cohort study on pediatric oral lesions. *Journal of Dentistry for Children*. 2015;82(2):84-90.
28. Hong CH, Dean DR, Hull K, et al. World Workshop on Oral Medicine VII: Relative frequency of oral mucosal lesions in children, a scoping review. *Oral diseases*. 2019;25:193-203.
29. Al-Maweri SA, Alaizari NA, Al-Sufyani GA. Oral mucosal lesions and their association with tobacco use and qat chewing among Yemeni dental patients. *Journal of clinical and experimental dentistry*. 2014;6(5):e460.
30. Halboub E, Al-Mohaya M, Abdulhuq M, et al. Oral squamous cell carcinoma among Yemenis: onset in young age and presentation at advanced stage. *Journal of clinical and experimental dentistry*. 2012;4(4):e221.
31. Pires FR, Ramos AB, Oliveira JBCd, et al. Oral squamous cell carcinoma: clinicopathological features from 346 cases from a single oral pathology service during an 8-year period. *Journal of Applied Oral Science*. 2013;21(5):460-467.
32. Miyake Y, Shinozuka K, Ueki K, et al. Retrospective clinical study of 296 patients with mass lesions of the tongue. *Journal of oral science*. 2018;60(4):574-578.
33. Farah CS, Balasubramaniam R, McCullough MJ. *Contemporary Oral Medicine: A Comprehensive Approach to Clinical Practice*: Springer 2019:1339
34. Glick M. *Burket's oral medicine: PMPH USA* 2015:153
35. Sasaki T, Moles D, Imai Y, et al. Clinico-pathological features of squamous cell carcinoma of the oral cavity in patients < 40 years of age. *Journal of oral pathology & medicine*. 2005;34(3):129-133.
36. Han S, Chen Y, Ge X, et al. Epidemiology and cost analysis for patients with oral cancer in a university hospital in China. *BMC public health*. 2010;10(1):196.
37. Ribeiro ACP, Silva ARS, Simonato LE, et al. Clinical and histopathological analysis of oral squamous cell carcinoma in young people: a descriptive study in Brazilians. *British Journal of Oral and Maxillofacial Surgery*. 2009;47(2):95-98.
38. Gheno JN, Martins MAT, Munerato MC, et al. Oral mucosal lesions and their association with sociodemographic, behavioral, and health status factors. *Brazilian oral research*. 2015;29(1):1-6.