

Extrasosseous Dentinogenic Ghost Cell Tumors (EDGCT): a Case Report and Review of the Literature

Mohamed A Jaber^{1*}, Hussain Elmasmari², Salem Abu Fanas³,
Sudhir Rama Varma⁴, Essra Mohamed Elameen⁵

1. Professor, Department of clinical sciences, College of Dentistry, Ajman University, Ajman, U.A.E.
2. Assistant Professor, Department of restorative dentistry, College of Dentistry, Ajman university, Ajman, U.A.E.
3. Professor, Department of Clinical sciences, College of dentistry, Ajman University, Ajman, U.A.E.
4. Clinical Assistant Professor, Department of Clinical Sciences, College of dentistry, Ajman University, Ajman, U.A.E.
5. student, Department of medical sciences, Medical college, Ajman University, Ajman, U.A.E.

Abstract

Extrasosseous Dentinogenic Ghost Cell Tumors (EDGCT) is a benign tumor of mesenchymal origin that is uncommon in the oral and maxillofacial region and forms only 2% of all odontogenic tumors. It was previously known as Calcifying odontogenic cyst and only recently has been classified as a tumor by WHO. The lesion is a benign cystic neoplasm of odontogenic origin that is characterized by ameloblastoma-like epithelial cells and ghost cells. Both intra-osseous and extra-osseous forms of CCOT have been reported. It commonly occurs in anterior region with equal preponderance in maxilla and mandible. Most EDGCTs are located in the anterior gingiva of the mandible or maxilla. Based on the clinical, radiographical and histopathological findings the lesion was diagnosed as EDGCT and surgically excised under local anesthesia. Here we present a rare case of EDGCT in the anterior maxilla of a 12-year-old female patient that was discovered incidentally during a clinical examination arising beneath the mucosa of the anterior maxilla. The management of this tumor is discussed and the literature is reviewed.

Case report and Review (J Int Dent Med Res 2021; 14(1): 336-339)

Keywords: Dentinogenic ghost cell tumors, Ghost cells, Extrasosseous lesion, Odontogenic tumor.

Received date: 30 July 2020

Accept date: 10 October 2020

Introduction

Dentinogenic ghost cell tumors (DGCT) are very rare tumors of odontogenic origin considered as solid variants of calcifying epithelial odontogenic cysts (CEOC). Extrasosseous Dentinogenic ghost cell tumors (EDGCT), characterized by an ameloblastoma-like epithelium with ghost cells that may calcify. The entity originally described by Gorlin and colleagues in 1962 as a possible oral analogue to pilomatrixoma of skin, owing to the presence of ghost cell keratinization in both lesions. However, the lesion also called Gorlin cyst, calcifying odontogenic cyst (COC), keratinizing and calcifying odontogenic cyst.¹ World Health Organization (WHO) in 1992, designated the

entity as odontogenic tumor and in 2005, WHO renamed it as calcifying cystic odontogenic tumor and on 2017 it has been reclassified as Dentinogenic ghost cell tumors.

The classification and terminologies used to describe the odontogenic tumors have undergone various modifications since 1887. The additional knowledge has accumulated that result in refining the classification of both benign and malignant tumors. In the latest WHO classification DGT was classified as benign Odontogenic Epithelium with Odontogenic Ectomesenchyme, with or without Hard Tissue Formation.²

Extrasosseous Dentinogenic ghost cell tumors (EDGCT) is a rare condition and represent only 2% of all odontogenic tumors. The lesion believed to be arise from odontogenic epithelial remnants within the maxilla or mandible. Dentinogenic ghost cell tumors may be peripheral (extra-osseous) or central (intra-osseous) type. Most EDGCTs are located in the anterior gingiva of the mandible or maxilla,^{2,3} Their prevalence has been reported to be less

*Corresponding author:

Mohamed A Jaber
Professor, Department of clinical sciences,
College of Dentistry, Ajman University, Ajman, U.A.E.
E-mail: mohamed.jaber@ajman.ac.ae

than 25% of all DGCTs.⁴ It commonly occurs in anterior region with equal preponderance in maxilla and mandible. The condition was reported more commonly in males than in females. EDGCT affects both male and females and any age group may be involved. Both maxilla and mandible can be affected in particular anterior to the first molar but, occasionally, it is the gingival mucosa and the underlying bone is merely indented.

Pathophysiology is controversial whether a developmental cyst or a true neoplasm and are believed to be derived from odontogenic epithelial remnants within the gingiva or within the mandible or maxilla and the most conspicuous feature is abnormal keratinization producing areas of swollen, eosinophilic cells which become progressively paler, leaving only their outlines (ghost cells).⁵ Solid variants of this tumour may therefore resemble an ameloblastoma.⁶ EDGCT may present alone or in association with other odontogenic tumor or odontomas.⁶ The lesion may cause erosion of the overlying bone and enucleation is usually effective in its treatment.

The present article reports a case of EDGCT arising beneath the mucosa of the anterior maxilla. The management of this tumor is discussed and the literature is reviewed.

Case Report

12-year-old female patient referred to Ajman University, College of Dentistry Dental Clinic, Ajman, UAE with a chief complaint of palatal swelling related to gingival margin of upper left lateral incisor tooth of 2 months duration. General physical and extra-oral examination of the patient did not reveal any abnormality. Intra-oral examination also did not reveal any significant finding, except the palatal gingival swelling which was sessile, ovoid in shape with smooth surface and diffuse margins, soft to firm on palpation, painless and of size 1.5x2 cm approx. (Fig. 1). There was no evidence of any associated dental infection or periodontal defect. Past medical history was not contributory. Radiographic investigations were carried out, which included intraoral periapical radiograph and panoramic radiograph. The radiographs reveal superficial bony erosion. After obtaining informed consent from the patient, an excisional biopsy of the lesion was done along with curettage under local anesthesia and subjected to histopathological study. During

excision of the lesion, peripheral nature of the lesion could be noticed. The histological examination revealed a lesion that is sharply circumscribed with cystic features. The cystic wall is lined by a thin stratified squamous epithelium and a limited amount of stroma. The epithelial lining was seen exhibiting dentoid material that shows calcification and several ghost cells and some scattered osseous tissue (Fig. 2, Fig 3).

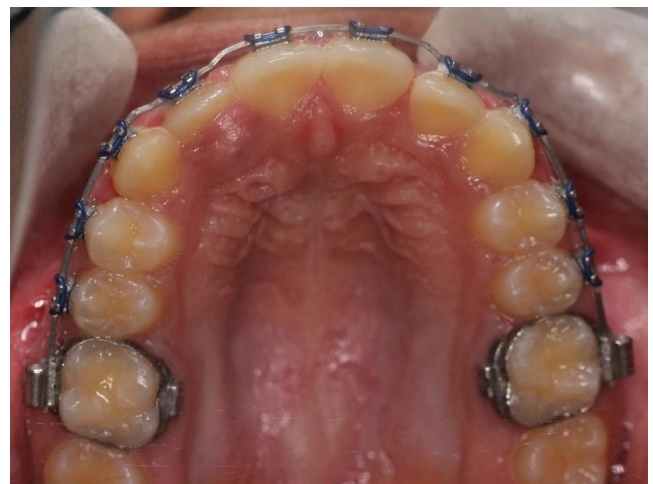

Figure 1. Swelling palatal to upper right lateral incisor tooth.

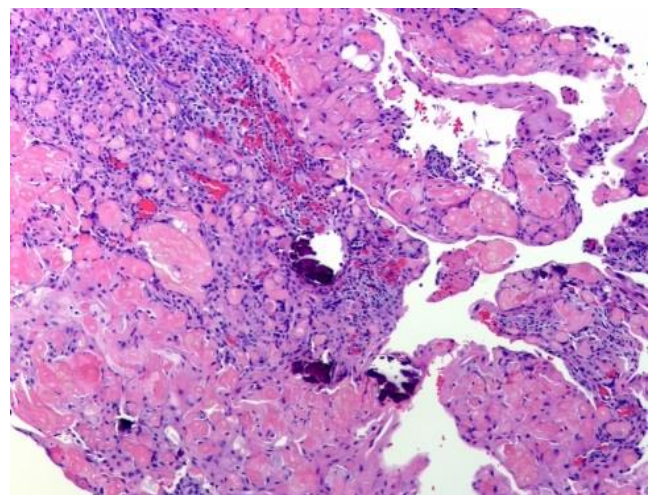


Figure 2. Photomicrograph showing numerous ghost cells and calcifications (H&E Stained x 100).

Considering the history, clinical examination, investigations and characteristic histopathological findings, a final diagnosis of EDGCT was made. The lesion was excised completely under local anesthesia and the healing process was uneventful. Till the time of

last visit, no recurrence was reported in our patient (Fig. 4).

The patient signed written informed consent agreeing for treatment and for publication of the case for research and educational purposes.

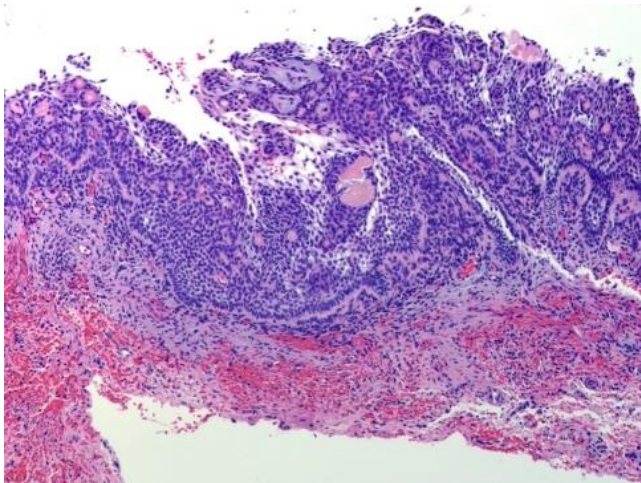


Figure 3. Photomicrograph showing cyst lining composed of an outer layer of columnar basaloid epithelium and an inner layer resembling stellate reticulum of enamel organ.

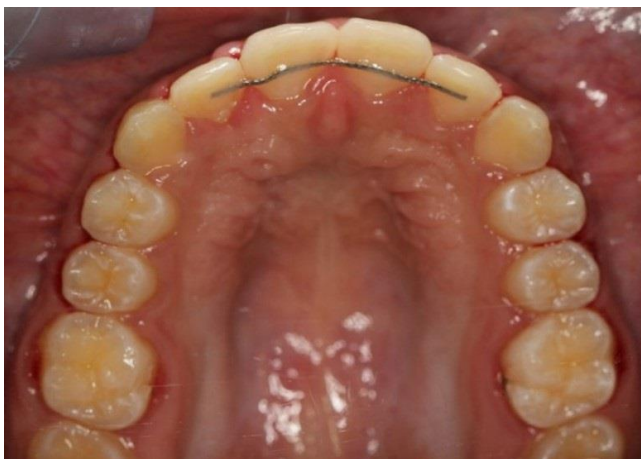

Figure 4. Patient status at the last follow up visit.

Discussion

Dentinogenic ghost cell tumors (DGCT), previously known as calcifying cystic odontogenic tumour (CCOT), or calcifying odontogenic cyst (COC) is a rare benign, slow growing developmental lesion of odontogenic epithelium. It was first described by Gorlin et al. in 1962.¹ In 2017, the World Health Organization classified it as benign tumour of odontogenic origin belonging to a group of related neoplasm, and

characterized by an ameloblastoma like epithelium containing ghost cells.⁷ Solid variants of this tumor may thus resemble an ameloblastoma.⁸ The lesion represent a spectrum of clinical behaviour and histopathological features including cystic, solid and aggressive variants.⁸⁻¹³

On the basis of clinicopathologic features, DGCT is classified into two different entities, peripheral and central type, clinically, EDGCT may present as a symptomatic nodular swellings on the gingival margin or edentulous alveolar mucosa of denture wearers, a feature that implicates trauma or irritation as aetiologic factors.⁶ In our case, trauma or irritation from orthodontics brackets was suspected as the aetiological factor.

EDGCTs occur with equal frequency in the maxilla and mandible^{2-4,9,10} and demonstrate no gender predilection.^{1,8,9,13,14} Buchner et al., noted that EDGCT tend to occur more often in mandibular anterior region and also occurred more often in females (66.6%) than in males (33.3%).⁵ In a review of 117 cases of ECCOT Chrcanovic & Gomez¹⁵ reported that the ECCOT didn't show a sex predilection, but affected women at a higher age than men, with bimodal age distribution and highest prevalence in the second and in the sixth/eighth decades of life, but other studies indicated that the lesion tend to occurs in a broad age group with a peak incidence in the second decade of life.^{8,12,14-17}

Radiographic examination of the lesion showed superficial alveolar bone resorption, similar observation also described by other researchers who noted alveolar bone resorption and saucer-shaped radiolucency,¹ in contrast Resende et al,¹⁸ reported that erosion of the underlying bone is not common radiographic feature of EDGCT as it occurs in 20% of the cases. The erosion may be so slight and can only be detected during the surgical procedure.

The EDGCT is believed to arise from odontogenic epithelial remnants.¹⁷ Histologic features include a cyst lining composed of an outer layer of a columnar basaloid odontogenic epithelium and an inner layer resembling stellate reticulum of the enamel organ. Histopathological examination of the EDGCT characterised by the presence of ghost cells and/or calcifications. These epithelial cells devoid of nuclei but they retain their basic cell outline and may undergo calcification and lose their cellular outline to form

sheet-like area.¹⁹ Shear & Speight²⁰ described the ghost cells as epithelial cells which are enlarged, ballooned, ovoid or elongated eosinophilic cells and are usually well-defined, they may sometimes be blurred and appear fused. EDGCT demonstrated positive expression of 'amelogenin protein' in the cytoplasm, suggesting that the epithelium lining of EDGCT might show ameloblastic differentiation in ghost cells.²¹ Several researchers utilizing special investigative techniques such as scanning electron microscopy or special histochemical methods tried to identify the nature of the ghost cells.²² EDGCTs can occur in association with other lesions such as odontogenic and nonodontogenic neoplasms, dentinogenic ghost cell tumour and odontogenic ghost cell carcinoma and odontomas.^{6,23-25}

Because of the benign nature of the EDGCT most authorities recommended conservative treatment like enucleation or local resection of the lesion^{2,6,15} with good prognosis and only few recurrences were reported.^{6,15}

Conclusions

The peripheral Dentinogenic ghost cell tumors is a rare benign, slow growing lesion which may present as swelling of gingival margin or alveolar ridge, with occasional involvement of underlying bone therefore surgical excision is the treatment of choice with good prognosis.

Declaration of Interest

The authors report no conflict of interest.

References

1. Gorlin R, Pindborg J, Clausen F, Vickers R. The calcifying odontogenic cyst—a possible analogue of the cutaneous calcifying epithelioma of Malherbe. *Oral Surg Oral Med Oral Pathol Endod* 1962;15:1235–43.
2. Susmit Sneha, Shams U Nisa, Amit Mhapuskar, Santosh Jadhav, Purva Abhyankar. Classification of Odontogenic Tumors: A Review Update. *J Int Dent Med Res*. 2018; 11(3): 1091-1095.
3. Moleri A, Moreira L, Carvalho J. Comparative morphology of 7 new cases of calcifying odontogenic cysts. *J Oral Maxillofac Surg* 2002;60:689–96.
4. Buchner A, Merrrell P, Hansen L. Peripheral (extraosseous) calcifying odontogenic cyst: a review of forty-five cases. *Oral Surg Oral Med Oral Pathol Endod* 1991;72:65–70.
5. Buchner A, Merrell P, Carpenter W. Relative frequency of peripheral odontogenic tumours: a study of 45 new cases and comparison with studies from the literature. *J Oral Pathol Med* 2006;35:385–91.

6. Hong S, Ellis G, Hartman K. Calcifying odontogenic cyst. A review of ninety-two cases with reevaluation of their nature as cysts or neoplasms, the nature of ghost cells, and sub classification. *Oral Surg Oral Med Oral Pathol Endod* 1991;72:56–64.
7. Wright J, Vered M. Update from the 4th Edition of the World Health Organization Classification of Head and Neck Tumours: Odontogenic and Maxillofacial Bone Tumors. *Head and Neck Pathol* 2017;11: 68–77.
8. Vaishali Koranne, Amit Mhapuskar, Shams Ul Nisa, Rashmi Saddiwal. Keratoameloblastoma- A Rare hybrid odontogenic tumor. *J Int Dent Med Res*. 2016;9:89-92.
9. Sciubba J, Fantasia J, Kahn L. Tumors and cysts of the jaws. Washington: Armed Forces Institute of Pathology 2001.pp.43–5.
10. Neville B, Damm D, Allen C, Bouquot J. *Oral and maxillofacial pathology*. 3rd ed. St. Louis: Saunders; 2009. pp. 695–7.
11. Toida M. So-called calcifying odontogenic cyst: review and discussion on the terminology and classification. *J Oral Pathol Med* 1998;27:49–52.
12. Li T, Yu S. Clinicopathologic spectrum of the so-called calcifying odontogenic cysts: a study of 21 intraosseous cases with reconsideration of the terminology and classification. *Am J Surg Pathol* 2003;27:372–84.
13. Barnes L, Everson J, Reichart P et al. World Health Organization classification of tumours: pathology and genetics of head and neck tumours. Lyon, France: IARC Press; 2005:313.
14. Buchner A. The central (intraosseous) calcifying odontogenic cyst: an analysis of 215 cases. *J Oral Maxillofac Surg* 1991;49:330–9.
15. Chrcanovic B, Gomez R. Peripheral calcifying cystic odontogenic tumour and peripheral dentinogenic ghost cell tumour: an updated systematic review of 117 cases reported in the literature. *Acta Odontologica Scandinavica* 2016, DOI: 10.1080/00016357.2016.1236986
16. Iida S, Fukuda Y, Ueda T, Aikawa T, Arizpe J, Okura M. Calcifying odontogenic cyst: radiologic findings in 11 cases. *Oral Surg Oral Med Oral Pathol Oral Radiol Endod* 2006;101:356–62.
17. Shear M. Developmental odontogenic cysts. An update. *J Oral Pathol Med* 1994;23:1–11.
18. Resende R, Brito JA, Souza L, Gomez R, Mesquita R. Peripheral calcifying odontogenic cyst: a case report and review of the literature. *Head Neck Pathol* 2011;5:76–80
19. Sonone A, Sabane VS, Desai R. Calcifying ghost cell odontogenic cyst: report of a case and review of literature. *Case Rep Dent*. 2011; 2011:328743. doi:10.1155/2011/328743
20. Shear M, Speight P. In: *Cyst of the Oral and Maxillofacial Region*. 4th ed. New York, USA: Blackwell Munksgaard; 2007. Calcifying odontogenic cyst (Calcifying cystic odontogenic tumors) pp. 100–7.
21. Gallana-Alvarez S, Mayorga-Jimenez F, Torres-Gomez FJ, Avella-Vecino FJ, Salazar-Fernandez C. Calcifying odontogenic cyst associated with complex odontoma: case report and review of the literature. *Med Oral Patol Oral Cir Bucal* 2005;10:243–47.
22. Yoshida M, Kumamoto H, Ooya K, Mayanagi H. Histopathological and immunohistochemical analysis of calcifying odontogenic cysts. *J Oral Pathol Med* 2001;30:582–88
23. Ide F, Obara K, Mishima K, Saito I. Ameloblastoma ex calcifying odontogenic cyst (dentinogenic ghost cell tumor). *J Oral Pathol Med* 2005;34:511–2.
24. Han P, Nagatsuka H, Siar C, et al. Review A pigmented calcifying cystic odontogenic tumor associated with compound odontoma: a case report and review of literature. *Head Face Med* 2007; 3(1):35. <https://doi.org/10.1186/1746-160X-3-35>
25. Zeitoun I, Dhanrajani P, Mosadomi H. Adenomatoid odontogenic tumor arising in a calcifying odontogenic cyst. *J Oral Maxillofac Surg* 1996;54:634–7.