

Titanium Mandibular Prosthesis with Condyle: A 3D Printing Reconstruction Model

Narissaporn Chaiprakit¹, Siripatra Patchanee^{2*}, Chanekrid Oupadissakoon¹,
Kritsasith Warin¹, Awiruth Klaisiri³

1. Division of Oral and maxillofacial surgery, Faculty of Dentistry, Thammasat University, Pathumthani, Thailand.
2. Division of Orthodontics, Faculty of Dentistry, Thammasat University, Pathumthani, Thailand.
3. Division of Operative Dentistry, Faculty of Dentistry, Thammasat University, Pathumthani, Thailand.

Abstract

This case report was aimed to demonstrate a novel reconstruction technique of a large defect of lower jaw after mandibular resection of Ameloblastoma in Thailand. Titanium mandibular prosthesis including condylar head was fabricated by using computer-aided design and three dimensional printing technology in combination with recipient bed for an autogenous block bone grafting prepared for further dental implants placement.

The body and angle of mandible was customized with Titanium alloy and attached with ultrahigh molecular weight of polyethylene condyle. Postoperative follow up was satisfied by both patient and surgeon with no complication was observed.

Case report (J Int Dent Med Res 2021; 14(1): 340-343)

Keywords: 3D printing, Condyle, Mandibular prosthesis, Titanium alloy.

Received date: 19 November 2020

Accept date: 05 January 2021

Introduction

Ameloblastoma is an aggressive benign odontogenic tumor generally present in the jaw bone, mostly found in mandible.¹ The surgical resection with a requirement of 1–1.5 cm of clinically and radiographically normal bone margins is the one of appropriated treatment options in large lesion.^{2,3}

Mandibular defect following resection of these tumor affects in both esthetic and function, which requires a multidisciplinary medical and dental team approach to restore function, esthetic and quality of life of the patient. The goals of mandibular reconstruction are to establish continuity alveolar height, width and arch form and to restore facial contour along with oral functions including mastication, deglutition, speech and oral competence. Many reconstruction modalities have been reported include reconstruction plate with or without pedicled myocutaneous flaps, alloplastic material, free graft, pedicled osteomyocutaneous flaps, and a variety of free vascularized bone flaps.^{4,5} However, reconstruction in large mandibular

defect may require vascularized bone flap such as Fibular free flap that cause morbidity at donor site and make the operation more complicated.⁴

Nowadays, the advance three dimensional (3D) technology can be used to fabricate alloplastic models for the mandibular reconstruction. Thus leads to improve cosmetic and functional outcome of manually bent plate, decrease in operative time and/or length of stay⁶⁻¹² and can be used as an alternative option for reconstruction of mandibular defect which prevent an esthetically acceptable reconstruction from fatigued failure at plate bending area.¹³

The aim of these report was to demonstrate the reconstruction of mandibular defect after segmental mandibulectomy of Ameloblastoma at mandible using customized 3D titanium mandibular prosthesis with condyle.

Case Report

A 36-year-old male presented to our department with an enlarging mass at right cheek. Radiographic examination showed multilocular radiolucency at right body, angle and ramus of mandible. A computed tomography with contrast media was further revealed enhancing mass with bony destruction extended to ramus of right mandible (Figure 1). Incisional biopsy was compatible with Ameloblastoma. The definitive planning was discussed with patient as tumor

*Corresponding author:

Dr. Siripatra Patchanee, Division of Orthodontics, Faculty of Dentistry, Thammasat University, 99 M. 18, Paholyothin road, Klongluang, Pathumthaini 12120, Thailand
E-mail: siripatra.p@hotmail.com

resection with segmental mandibulectomy and disarticulate then immediately reconstruction mandibular defect with Fibular microvascular flap. However, patient denied the flap reconstruction option due to complications and morbidity from complex procedures. Another reconstruction method was offered as 3D printing customized titanium mandibular prosthesis and condyle with a specialized housing design for autogenous iliac bone block graft. By comparing all risk and benefit, patient made his decision for the latter plan.

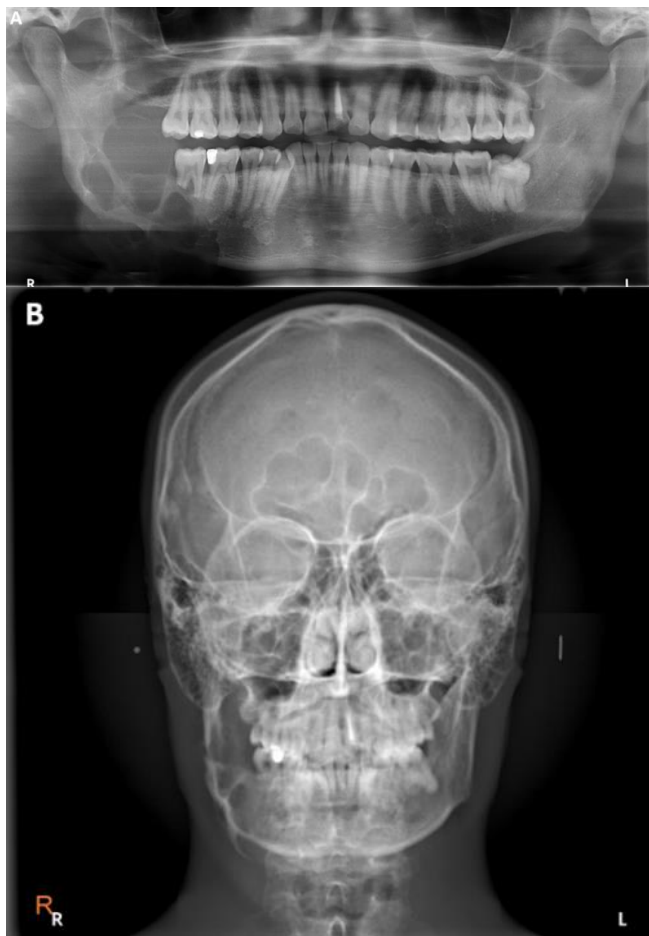

Figure 1. Pre-operative radiographs (A) Panoramic radiograph showed multilocular radiolucency at right posterior mandible involve inferior border of mandible. (B) Postero-anterior skull radiograph showed multilocular radiolucency with buccal expansion of right posterior mandible.

The tumor resection process was performed under general anesthesia by using 3D print surgical guide. Then customized mandibular prosthesis with condyle was applied to

mandibular defect and fixed with 2.7-locking screws at mandibular symphysis stump (Figure 2).

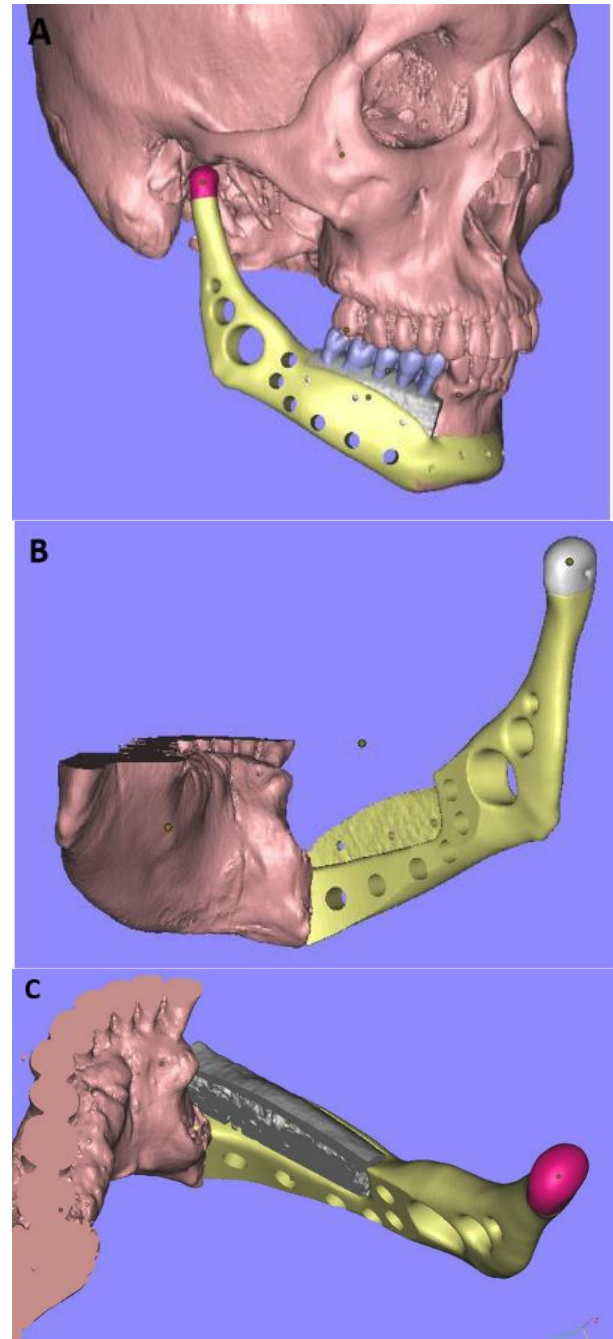


Figure 2. Customized mandibular prosthesis with condyle (A) Reconstruction mandibular defect planned with 3D simulation of mandibular model using customized mandibular prosthesis with condyle. (B) Lingual aspect of prosthesis which designed as 2.7 mm locking plate and had the slot for placing corticocancellous bone block graft. (C) Lingual aspect of prosthesis after placing corticocancellous bone block graft.

A corticocancellous block graft was harvested from left iliac bone as 3D planed and fixed to the titanium body part of prosthesis with 2.7-locking screw. Postoperative films showed completed tumor removal. The customized mandibular prosthesis with condyle was placed in planned position and an esthetically acceptable reconstruction (Figure 3).

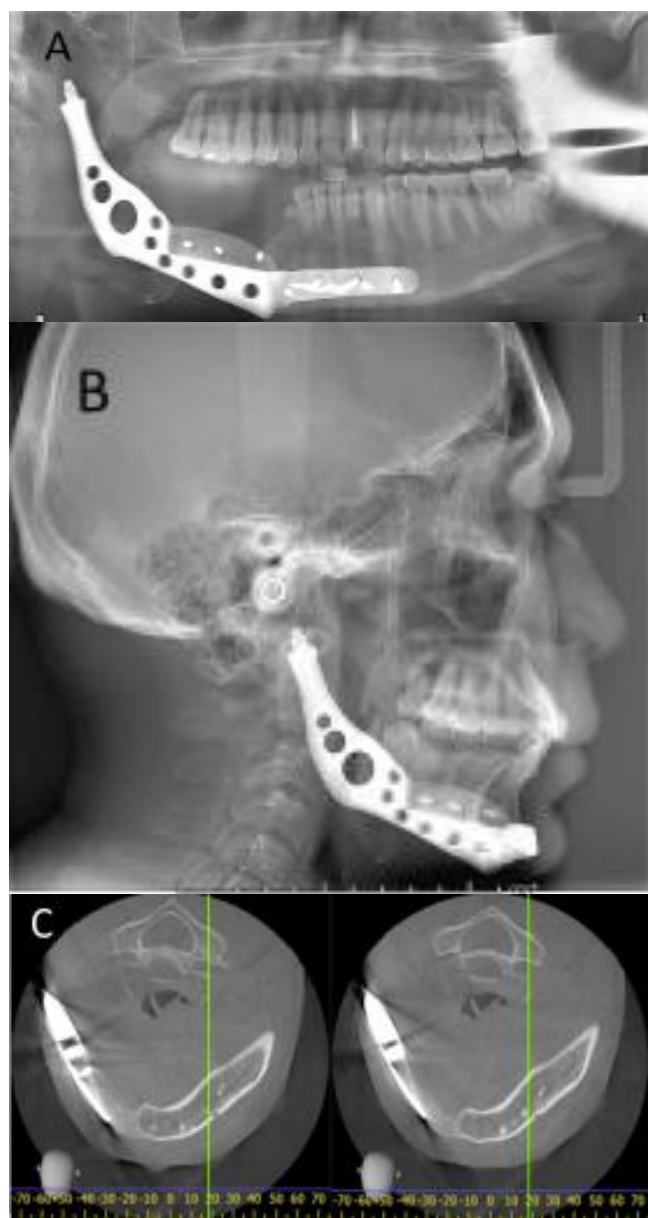


Figure 3. Radiograph showed mandibular prosthesis with condyle and a corticocancellous bone graft (arrow heads) was placed in planned position with no clinical complication after 3 months post-operatively. (A) Panoramic radiograph (B) Lateral cephalometric radiograph (C) Cone-beam computed tomography (axial views).

Method of model construction

Preoperatively, computed tomography was performed to obtain a 0.5-mm slice of the patient's mandible in digital imaging and communications in medicine (DICOM) format. Next, a 3D mandibular model of the patients was prepared. We used a custom-made titanium mandibular prosthesis for mandibular reconstruction. The surface of the customized prosthesis was designed to reproduce the natural curvature of the mandible by the mirror image of the contralateral side in accordance with postoperative esthetic results. The condylar head prosthetic part was created to place in glenoid fossa. The symphysis part was designed passively fit to the remaining symphysis stump by 2.7 mm locking plate and 4 fixing holes at dentoalveolar part were prepared for fixing an iliac block graft.

Discussion

Oral functions and cosmetic satisfaction among patients are main important factors that should be addressed in reconstruction of mandibular defect. Ideally, a vascularized bone flap, for example Fibular free flap is considered as the best reconstruction method in terms of reliable reconstruction.^{4,14} However, this is not always possible due to morbidity at donor site and risk of complication and flap failure. Currently, many efficient 3D mandibular reconstruction that involve the combination of an autogenous free bone graft or vascularized bone flap are available.^{6, 7, 9, 12,15} However, obtaining an esthetically appropriate reconstruction remains challenging, especially in patients requiring reconstruction in a large mandibular defect.

These customized titanium mandibular prosthesis with condyle is the first custom-made alloplastic mandibular prosthesis with condylar part which can combined with corticocancellous bone graft for mandibular reconstruction in Thailand. Their use has a cosmetic-related advantage over intra-operative conventional mandibular plate bending method, owing to their design closely match the three-dimensional shape of the contralateral side of patient's mandible which can ensure complete esthetical facial contour and reduce the incidence of plate failure from improper adaptation of plate.⁸ Furthermore, the condylar prosthesis part can maintain masticatory movement similar to normal

jaw function.

It is clear that custom made mandibular prosthesis are relatively expensive. Patients with large mandibular defect who concern about their appearance may require a relatively high-quality cosmetic repair. Surgeons must provide them with an esthetically pleasing reconstruction and less complication. In addition, this patient had reported well adaptation on function and no clinical complication was observed 4 months postoperatively. At this point, using a custom made 3D printing mandibular prosthesis seems to be a promising protocol for large defect reconstruction in our center. Further investigations are required for more information of mechanical properties and long term stability.

Conclusions

In conclusion, postoperative function and cosmetic results are important for patient satisfaction after tumor resection and reconstruction of mandibular defect. Customized mandibular prosthesis with condyle are useful when function and cosmetic results are required. And using 3D surgical planning in these customized mandibular prosthesis can ensure dental rehabilitation with moderate or good post-operative quality of life.

Consent

Consent form obtained from the patient to use his photos for educational purposes.

Declaration of Interest

The authors report no conflict of interest.

References

1. Masthan KM, Anitha N, Krupaa J, Manikkam S. Ameloblastoma. *J Pharm Bioallied Sci.* 2015;7:167-70.
2. Dandriyal R, Gupta A, Pant S, Baweja HH. Surgical management of ameloblastoma: Conservative or radical approach. *Natl J Maxillofac Surg.* 2011;2(1):22-7.
3. Singh M, Shah A, Bhattacharya A, Raman R, Ranganatha N, Prakash P. Treatment algorithm for ameloblastoma. *Case Rep Dent.* 2014:121032.
4. Hayden RE, Mullin DP, Patel AK. Reconstruction of the segmental mandibular defect: current state of the art. *Curr Opin Otolaryngol Head Neck Surg.* 2012;20(4):231-6.
5. Kumar BP, Venkatesh V, Kumar KA, Yadav BY, Mohan SR. Mandibular Reconstruction: Overview. *J Maxillofac Oral Surg.* 2016;15(4):425-41.
6. Dupret-Bories A, Vergez S, Meresse T, Brouillet F, Bertrand G. Contribution of 3D printing to mandibular reconstruction after cancer. *Eur Ann Otorhinolaryngol Head Neck Dis.* 2018;135(2):133-6.
7. Goormans F, Sun Y, Bila M, et al. Accuracy of computer-assisted mandibular reconstructions with free fibula flap: Results of a single-center series. *Oral Oncol.* 2019;97:69-75.
8. Gutwald R, Jaeger R, Lambers FM. Customized mandibular reconstruction plates improve mechanical performance in a mandibular reconstruction model. *Comput Methods Biomech Biomed Engin.* 2017;20(4):426-35.
9. Jacek B, Maciej P, Tomasz P, et al. 3D printed models in mandibular reconstruction with bony free flaps. *J Mater Sci Mater Med.* 2018;29(2):23.
10. Lee YW, You HJ, Jung JA, Kim DW. Mandibular reconstruction using customized three-dimensional titanium implant. *Arch Craniofac Surg.* 2018;19(2):152-6.
11. Li CH, Wu CH, Lin CL. Design of a patient-specific mandible reconstruction implant with dental prosthesis for metal 3D printing using integrated weighted topology optimization and finite element analysis. *J Mech Behav Biomed Mater.* 2020;105:103700.
12. Rachmiel A, Shilo D, Blanc O, Emodi O. Reconstruction of complex mandibular defects using integrated dental custom-made titanium implants. *Br J Oral Maxillofac Surg.* 2017;55(4):425-7.
13. Salgueiro MI, Stevens MR. Experience with the use of prebent plates for the reconstruction of mandibular defects. *Craniomaxillofac Trauma Reconstr.* 2010;3(4):201-8.
14. Tri Ardi Mahendra, Nina Ariani, Saraventi Mursid, Parintosa Atmodiwirjo, Kristaninta Bangun, Dwi Ariawan. Reconstruction with fibula transfer and implant supported overdenture for a mandibular defect: A multidisciplinary approach. *J. Int. Dent. Medical Res.* 2017;10(3):1005-9.
15. Pati, Teerdha & Adamali, Mohammed & Smriti, Komal & Pentapati, Kalyana & Vineetha, R & Gadicherla, Srikanth. (2019). 3D Bio-Printing-A Review on Current Application and Future Prospects in Dentistry. *J. Int. Dent. Medical Res.* 2019;12(3): 1202-10.